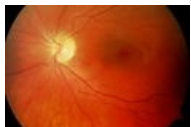

Kategorie:Klinický obraz

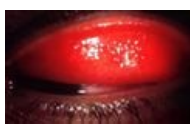Media in category "Klinický obraz"

The following 200 files are in this category, out of 236 total.

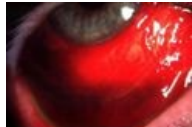(previous page) (next page)



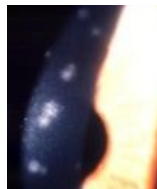Achromatopsie.jpg
900 × 603; 58 KB



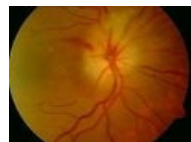Adenovirová ker...
879 × 544; 48 KB



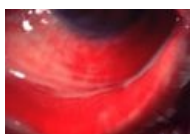Adenovirová ker...
826 × 579; 50 KB



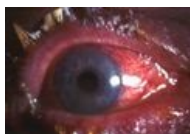Adenovirová ker...
510 × 619; 30 KB



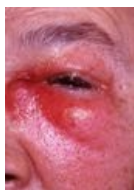AION.jpg
258 × 191; 11 KB



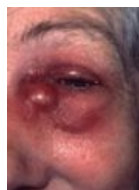Akutní bakteriáln...
854 × 581; 41 KB



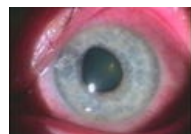
Akutní bakteriáln...
853 × 591; 59 KB



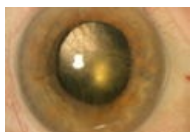Akutní dakryloxy...
464 × 658; 54 KB



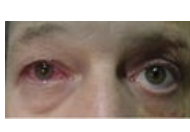Akutní dakryloxy...
467 × 634; 45 KB



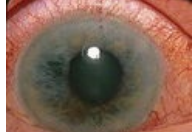Akutní glaukom.jpg
773 × 539; 53 KB



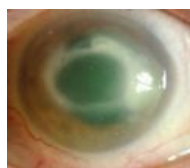
Akutní iridocykliti...
605 × 413; 33 KB



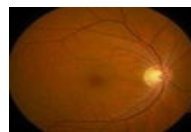Akutní iridocykliti...
592 × 311; 32 KB



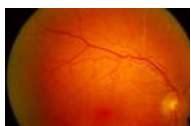Akutní záchvat gl...
215 × 165; 15 KB



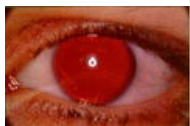Amébová keratiti...
589 × 513; 33 KB



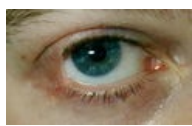
Angiopathia hype...
852 × 573; 47 KB



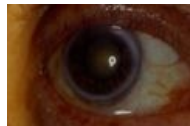
Angiosclerosis hy...
851 × 552; 53 KB



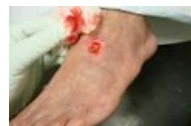Aniridie.jpg
650 × 426; 55 KB



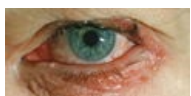Ankyloblefaron.jpg
752 × 473; 60 KB



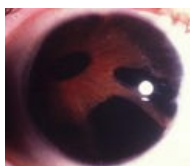
Arcus corneae se...
942 × 647; 52 KB



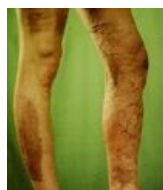Arterial ulcer peri...
750 × 500; 51 KB



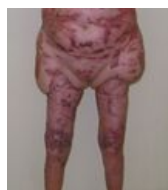Atopický ekzém -...
858 × 416; 68 KB



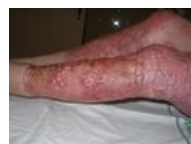Atrofie duhovky.jpg
487 × 424; 24 KB



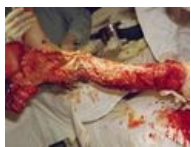Avulze DK 2 roky...
583 × 683; 49 KB



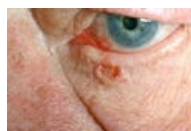Avulze DK nasled...
781 × 881; 368 KB



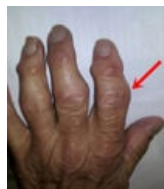Avulze DK otoky.j...
1,600 × 1,200; 457 KB



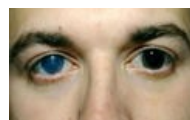Avulze DK.jpg
800 × 600; 68 KB



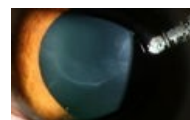
Bazaliom víčka.jpg
703 × 469; 78 KB



Bouchard-nodes ...
880 × 1,024; 280 KB



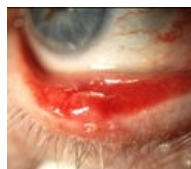Buftalmus.jpg
880 × 538; 75 KB



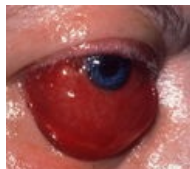
Buftalmus2.jpg
880 × 538; 40 KB



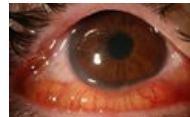Bulózní keratopa...
880 × 538; 44 KB



Chalazion dolníh...
607 × 538; 57 KB



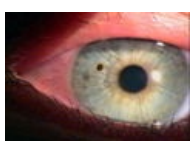
Chemóza spojivk...
453 × 406; 40 KB



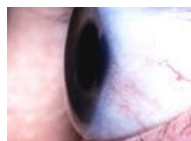Chemóza spojivk...
780 × 503; 67 KB



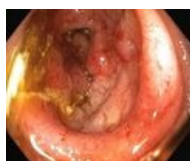Cirk popal krku E...
480 × 360; 68 KB



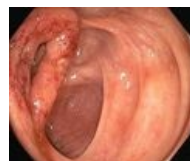Cizí tělísko rohov...
763 × 533; 58 KB



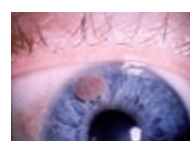
Cornea plana.jpg
660 × 499; 52 KB



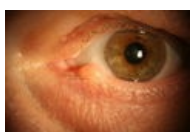Crohn1.jpg
300 × 250; 83 KB



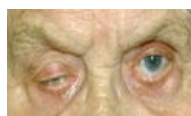Crohn2.jpg
300 × 254; 73 KB



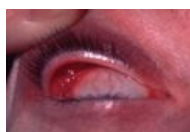Cysta duhovky.jpg
570 × 403; 38 KB



Cysta víčka.jpg
703 × 469; 58 KB



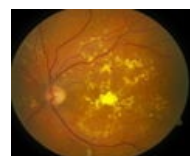Dakryoadenitida...
477 × 279; 26 KB



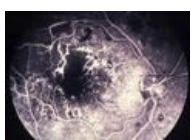
Dakryoadenitida...
586 × 404; 32 KB



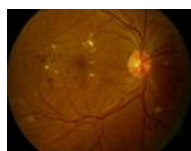Deviace bulbu.jpg
850 × 376; 57 KB



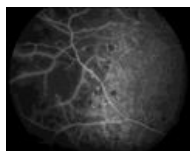
Diabetická MP - e...
658 × 526; 43 KB



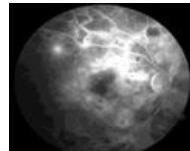
Diabetická MP - i...
191 × 132; 13 KB



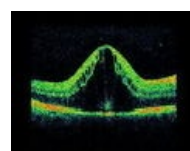
Diabetická MP - i...
653 × 515; 40 KB



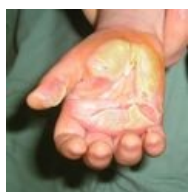Diabetická MP FA...
588 × 470; 43 KB



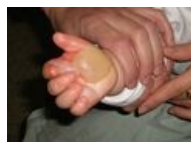Diabetická MP FA...
591 × 509; 45 KB



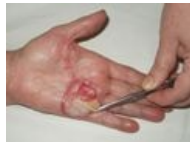Diabetická MP O...
253 × 197; 16 KB



Dlan buly.jpg
1,135 × 1,159; 331 KB



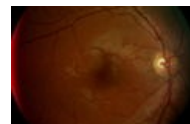Dlan dite.jpg
2,288 × 1,712; 844 KB



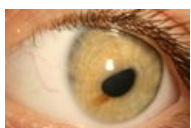
Dlan fibrinova bu...
1,257 × 1,017; 502 KB



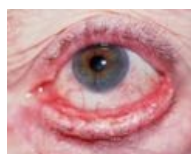Dysfunkce šž - m...
1,869 × 746; 297 KB



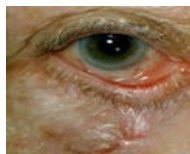
Dystrofie čípků.jpg
900 × 603; 46 KB



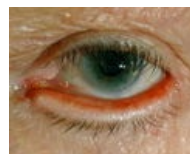Ektopie zornice.jpg
711 × 474; 55 KB



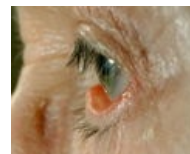Ektropium involu...
728 × 586; 58 KB



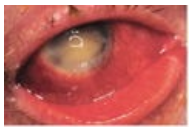Ektropium jizevn...
560 × 468; 62 KB



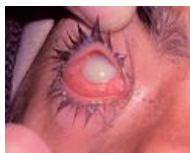Ektropium.jpg
571 × 472; 65 KB



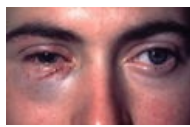Ektropium2.jpg
560 × 468; 42 KB



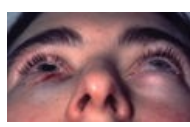Endoftalmitida.jpg
676 × 446; 55 KB



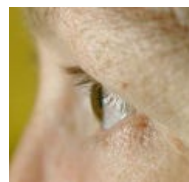
Endoftalmitida2.j...
360 × 286; 31 KB



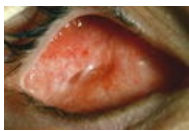Enoftalmus-blow ...
792 × 503; 68 KB



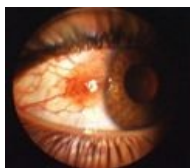Enoftalmus-blow ...
751 × 444; 53 KB



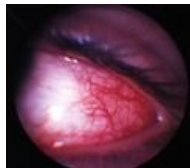Enoftalmus.jpg
452 × 431; 30 KB



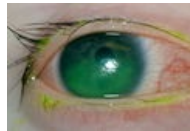Enukleace bulbu...
873 × 584; 73 KB



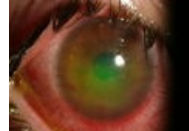
Episcleritis nodul...
750 × 659; 51 KB



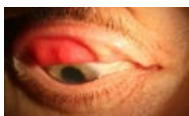Episcleritis simpl...
728 × 657; 43 KB




Eroze rohovky.jpg
773 × 539; 59 KB



Eroze rohovky2.jpg
669 × 497; 46 KB



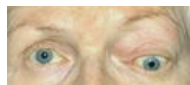Everze horního ví...
711 × 426; 50 KB



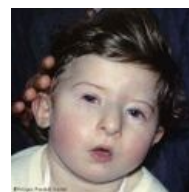Exoftalmus - inte...
388 × 934; 48 KB



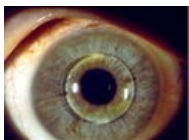Exoftalmus-jedno...
980 × 411; 68 KB



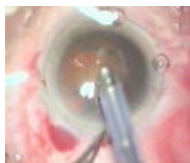Exoftalmus-jedno...
926 × 408; 51 KB



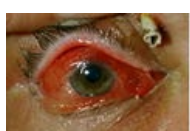Facial appearanc...
518 × 526; 19 KB



Fakická předněk...
771 × 567; 73 KB



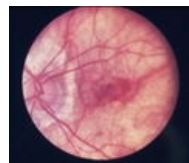
Fakoemulzifikace...
326 × 276; 18 KB



Flegmóna očnice...
850 × 554; 92 KB




Fuchsova dystrof...
850 × 571; 46 KB




Fuchsova skvrna...
614 × 526; 48 KB




Furunkl víčka.jpg
858 × 416; 69 KB




Glaukom - incipie...
253 × 273; 28 KB



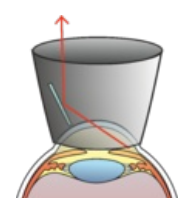
Glaukom - nasáln...
253 × 273; 35 KB



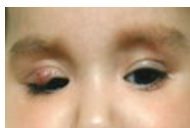Glaukom - pokro...
253 × 273; 30 KB




Glaukom - zbytko...
253 × 273; 22 KB



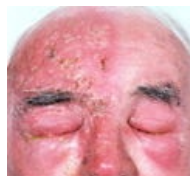Goniosk.png
2,050 × 2,342; 451 KB



Hemangiom víčk...
703 × 469; 53 KB



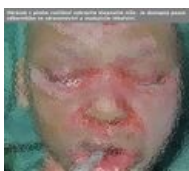Herpes simplex k...
846 × 536; 25 KB



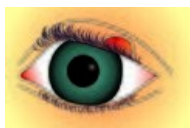
Herpes zoster op...
573 × 546; 83 KB



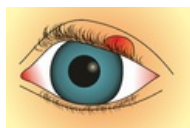
Hertlův exoftalm...
746 × 238; 35 KB



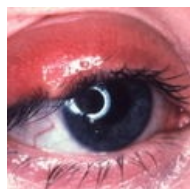Hluboke popaleni...
480 × 426; 62 KB



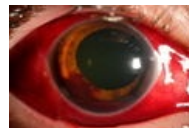Hordeolum.jpg
2,344 × 1,611; 4.21 MB



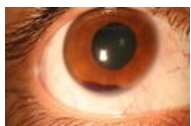Hordeolum.png
2,344 × 1,611; 958 KB



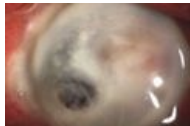Hordeolum1.jpg
530 × 530; 57 KB



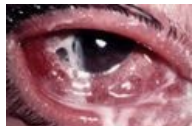Hyfema, sufuze.jpg
773 × 539; 62 KB



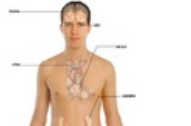
Hyféma.jpg
776 × 504; 65 KB



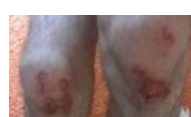Hyperakutní gon...
554 × 393; 28 KB



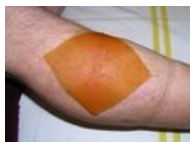Hyperakutní gon...
876 × 606; 74 KB



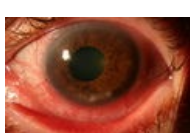Hypertenzní krize...
640 × 512; 216 KB



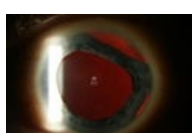
IMAG0213 1.jpg
2,610 × 1,472; 449 KB



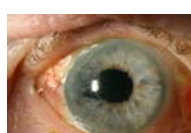Inadine.jpg
2,048 × 1,536; 944 KB



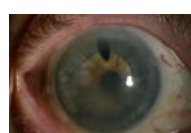Injekce smíšená.j...
780 × 503; 68 KB



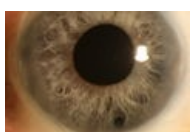Iridodialýza.jpg
711 × 474; 31 KB



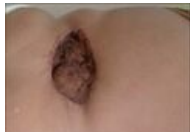Iridorhexe.jpg
711 × 474; 60 KB



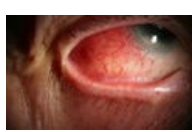Iridotomie-BIRE.jpg
711 × 474; 44 KB



Iridotomie-LIRE.jpg
711 × 474; 45 KB



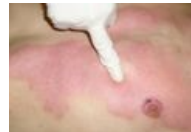JCutanAesthetSur...
743 × 558; 60 KB



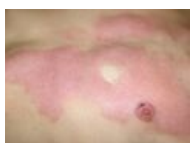Jizevnatý pemphi...
712 × 441; 55 KB




Kanalikulitida.jpg
711 × 426; 53 KB



Kapilární návrat ...
1,200 × 898; 324 KB



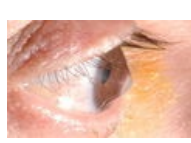Kapilární návrat ...
1,200 × 898; 320 KB



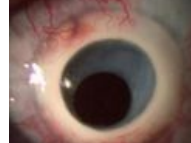Keratokonus - m...
517 × 167; 23 KB



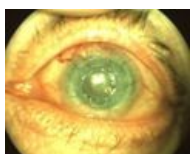Keratokonus-Vog...
411 × 426; 24 KB



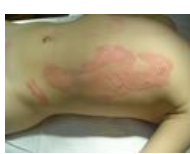Keratokonus.jpg
950 × 600; 87 KB



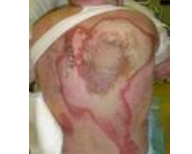Keratoprotéza al...
660 × 645; 41 KB



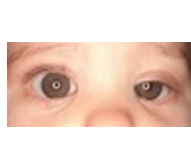Keratoprotéza ke...
759 × 609; 59 KB



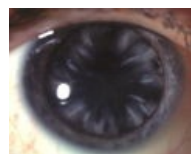Kolaterální otok.jpg
2,288 × 1,712; 874 KB



Koncentrická pop...
1,485 × 1,966; 838 KB




Kongenitální ptóz...
1,207 × 549; 57 KB



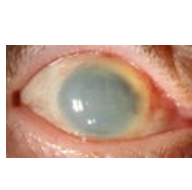Kortikální katar...
380 × 315; 17 KB



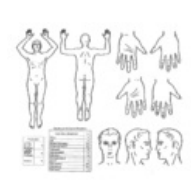Krönleinův výstře...
1,500 × 1,752; 108 KB



Lagoftalmus - zá...
526 × 586; 75 KB



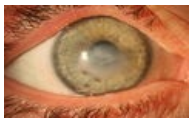Leukom.jpg
865 × 529; 68 KB



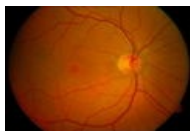Lund-Browder-ad...
960 × 816; 88 KB



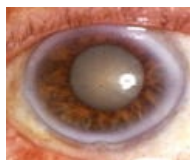Lund-Browder-ch...
960 × 816; 102 KB



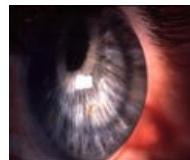Makula.jpg
865 × 529; 84 KB



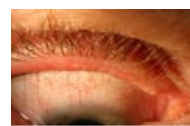Makulární díra.jpg
741 × 501; 40 KB



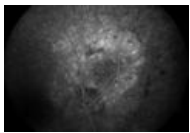
Maturitní katarak...
258 × 216; 15 KB



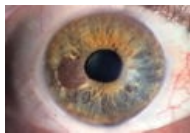Megalokornea.jpg
707 × 607; 53 KB



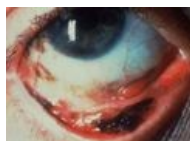Meibomitida.jpg
861 × 546; 75 KB



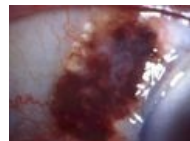Melanom cévnat...
725 × 496; 40 KB



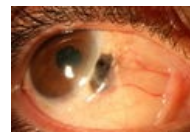
Melanom duhovk...
565 × 393; 41 KB



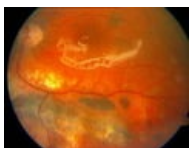Melanom spojivk...
847 × 636; 64 KB



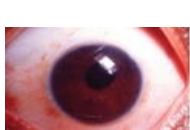Melanom spojivk...
837 × 642; 53 KB



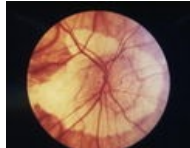
Melanoma ciliárn...
863 × 583; 85 KB



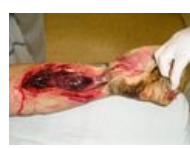Metalóza.jpg
467 × 359; 25 KB



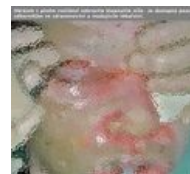Mikrokornea.jpg
585 × 325; 35 KB



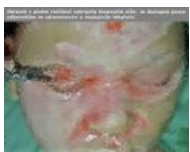Myopický konus -...
674 × 565; 49 KB



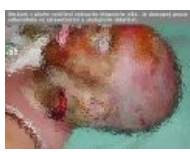Narez karpal el p...
1,924 × 1,365; 569 KB



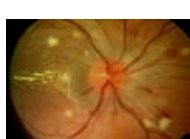Narez vicek01.jpg
480 × 443; 70 KB



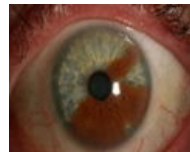Narez vicek02.jpg
480 × 379; 52 KB



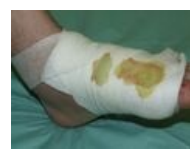Narezy vicek krk...
480 × 360; 69 KB



Neuroretinopathi...
851 × 552; 57 KB



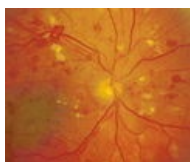Nevus duhovky.jpg
600 × 496; 43 KB



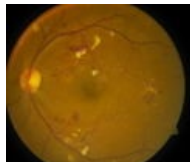
Noha prosak.jpg
1,600 × 1,200; 584 KB



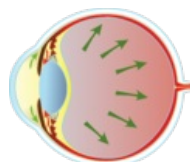
Nozky novorozen...
896 × 592; 159 KB



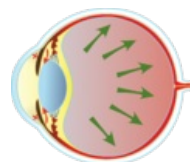
NPDR 2.jpg
442 × 375; 36 KB



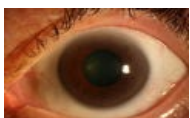NPDR.jpg
527 × 470; 32 KB



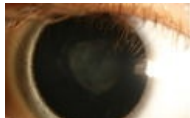NT2.png
2,458 × 2,119; 519 KB



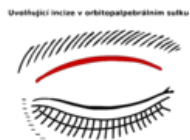NT3.png
2,496 × 2,119; 524 KB



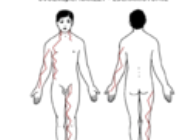Nubekula.jpg
865 × 529; 68 KB



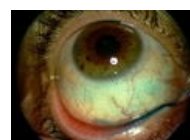Nukleární katarak...
715 × 473; 35 KB



Nářez oko.svg
1,780 × 1,500; 15 KB



Nářezy.svg
1,024 × 1,236; 59 KB



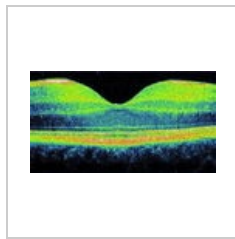
Obarvení lisamin...
773 × 573; 80 KB



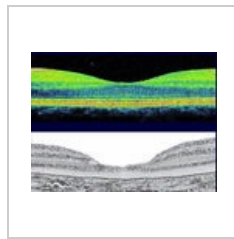
Obrna medianu.p...
640 × 699; 206 KB



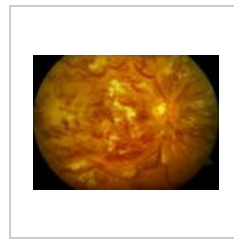
Obrna n.ulnaris.p...
486 × 604; 120 KB



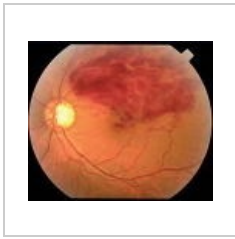
OCT norma.jpg
422 × 231; 43 KB



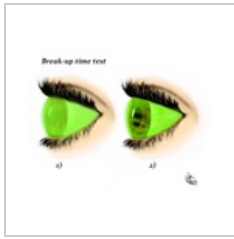OCT vs. histologi...
649 × 487; 103 KB



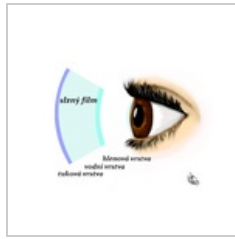
Okluze vena cent...
784 × 569; 60 KB



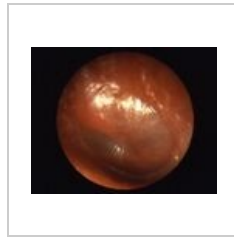
Okluze větve ven...
242 × 207; 13 KB



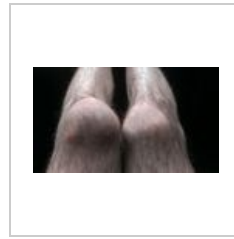
Oko-slný film-B...
1,844 × 1,420;
1.97 MB



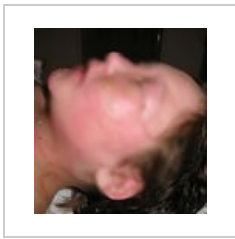Oko-slný film.png
1,844 × 1,420; 910
KB



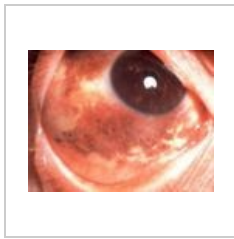
Otitis media acut...
754 × 600; 56 KB



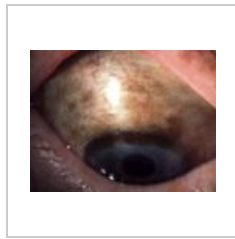
Otok kolene.jpeg
3,264 × 1,840;
1.42 MB



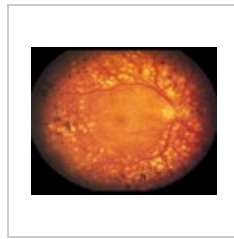
Otok obličeje.jpg
1,557 × 1,665;
2.28 MB



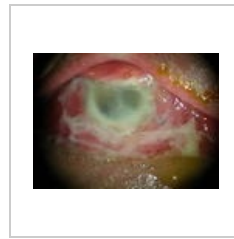Oční melanóza.JPG
835 × 640; 65 KB



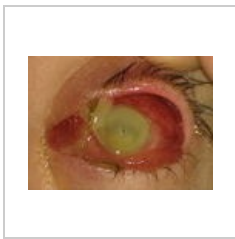
Oční melanóza2.J...
841 × 643; 51 KB




Panlaserfotokoag...
588 × 470; 56 KB



Panoftalmitida.jpg
259 × 191; 13 KB



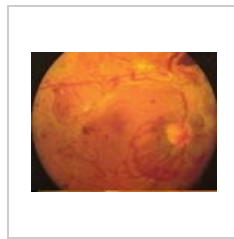
Panoftalmitida2.jpg
254 × 184; 15 KB



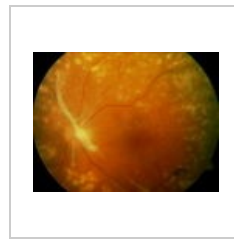
Paréza N.VI..jpg
915 × 357; 57 KB



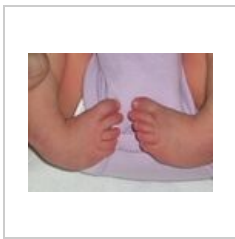
Paréza N.VII..jpg
526 × 586; 60 KB



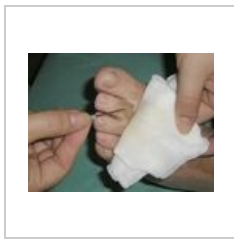PDR - fibrovaskul...
256 × 193; 12 KB



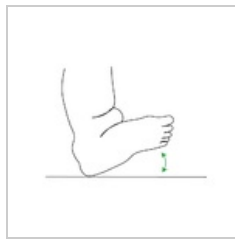
PDR - ischemie.jpg
769 × 576; 45 KB



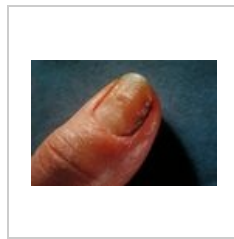
PEC.jpg
640 × 480; 66 KB



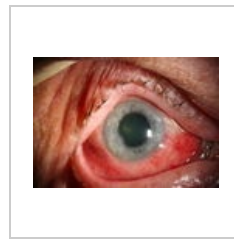
Perforace buly no...
2,288 × 1,712;
1,005 KB



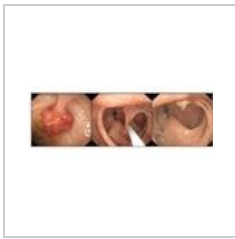Pes-calcaneovalg...
800 × 619; 24 KB



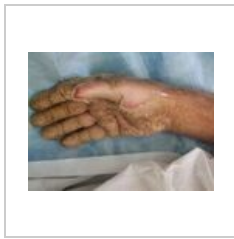PHIL 2923 lores.jpg
700 × 475; 35 KB



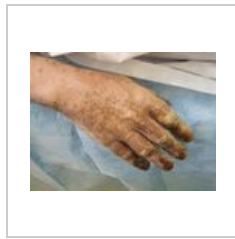Poleptání oka.jpg
773 × 539; 76 KB



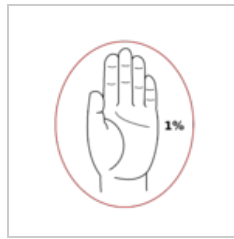Polypy.jpg
800 × 313; 40 KB



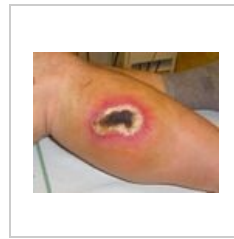Popalenina el obl...
1,200 × 900; 342
KB



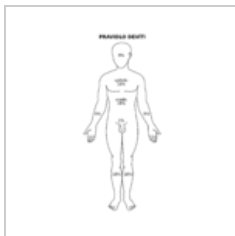
Popalenina el obl...
1,200 × 900; 372
KB




Popalenina rozsa...
1,284 × 1,576; 9
KB



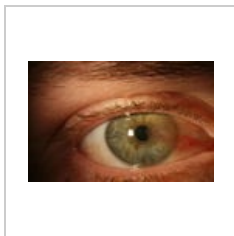
Popálenina III.st ...
1,254 × 946; 406
KB



Pravidlo9.svg
860 × 1,940; 15 KB



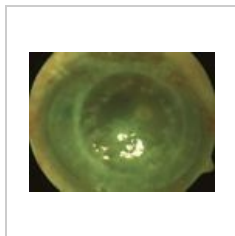
Precipitáty endot...
605 × 413; 24 KB



Pterygium1.jpg
776 × 504; 65 KB



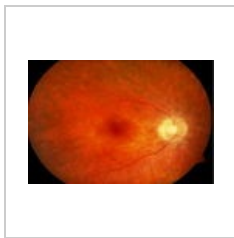
PWS.jpg
720 × 540; 72 KB



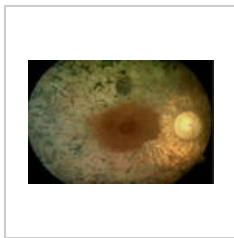
Rejekce terče.JPG
731 × 549; 37 KB



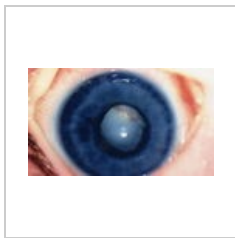
Retina.png
2,744 × 1,722;
1.06 MB



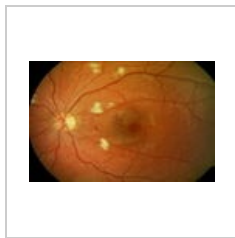
Retinitis pigment...
900 × 603; 63 KB



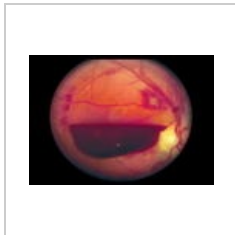
Retinitis pigment...
900 × 603; 79 KB



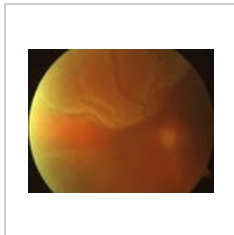
Retinoblastom.jpg
666 × 391; 38 KB



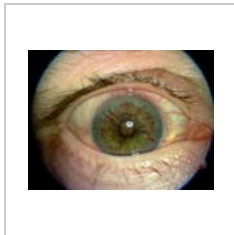
Retinopathia hyp...
851 × 552; 54 KB



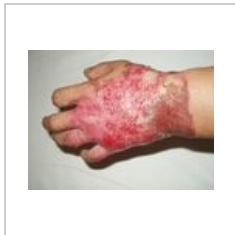Retrovitreální krv...
688 × 479; 34 KB



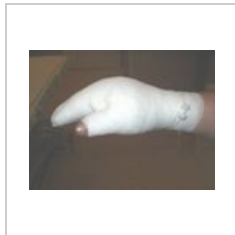
Rhegmatogenní ...
776 × 603; 29 KB



Rubeóza.jpg
761 × 573; 74 KB



Ruka kapilarostá...
1,600 × 1,200; 420 KB



Ruka obvaz spra...
1,500 × 1,125; 100 KB

(previous page) (next page)