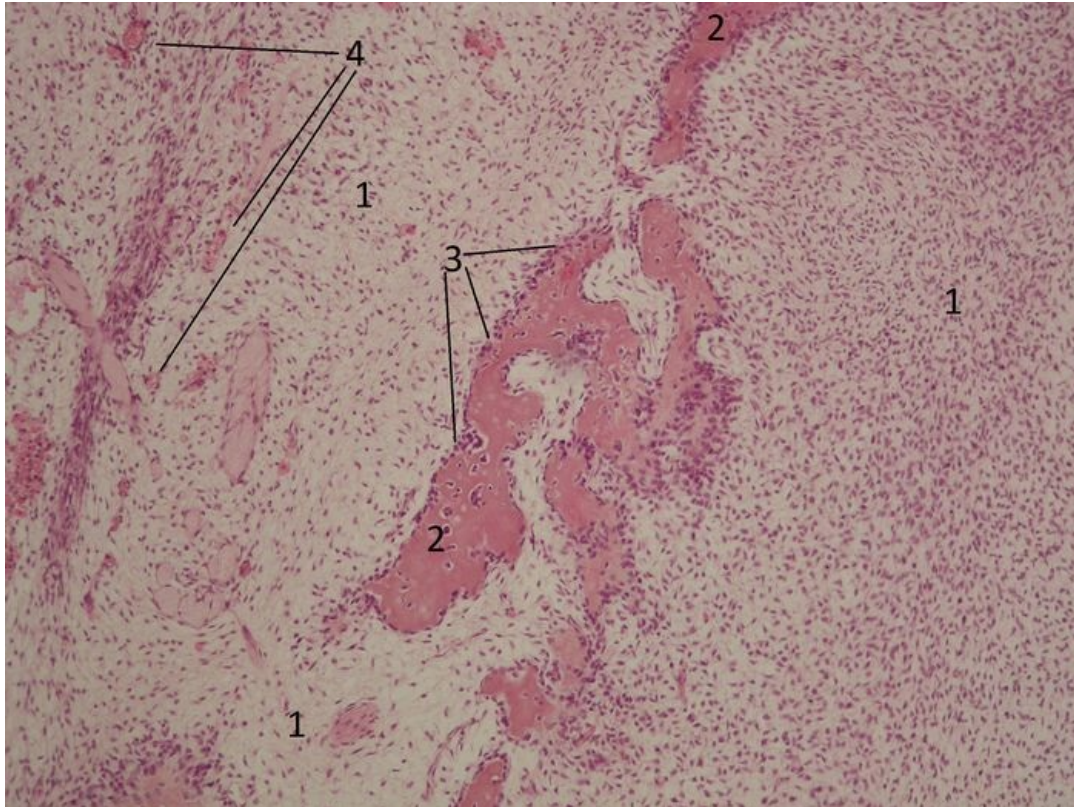


Intramembranózní osifikace (preparát)



1 - Nediferencovaný mesenchym / undifferentiated mesenchyme

2 - Osteoid

3 - Lem osteoblastů / osteoblastic ridge

4 - Drobné cévy / little blood vessels