

# Kategorie:Anatomie

## Subcategories

This category has the following 3 subcategories, out of 3 total.

### A

- Anatomická schémata (172 F)
- Anatomické fotografie (2 F)

### T

- Topografická anatomie (91 P, 4 F)

## Pages in category "Anatomie"

The following 200 pages are in this category, out of 820 total.

(previous page) (next page)

### A

- Abrupce
- Uživatel:Adelabenes/Pískoviště
- Uživatel:Adelaides/Pískoviště
- Anatomické názvosloví
- Portál:Anatomie
- Čipaultovo pravidlo
- Ankylóza
- Anomálie koronárních tepen
- Anulus tendineus communis
- Aorta
- Aorta abdominalis
- Aorta thoracica
- Apokrinní žlázy
- Arcus palmaris superficialis
- Arteria axillaris
- Arteria brachialis
- Arteria carotis communis
- Arteria carotis externa
- Arteria carotis interna
- Arteria circumflexa humeri posterior
- Arteria facialis
- Arteria femoralis
- Arteria iliaca communis
- Arteria iliaca externa
- Arteria iliaca interna
- Arteria lusoria
- Arteria maxillaris
- Arteria meningeae media
- Arteria radialis
- Arteria subclavia
- Arteria ulnaris
- Arteria vertebralis
- Arterie
- Arteriální zásobení hrudní stěny
- Articulatio acromioclavicularis
- Articulatio coxae
- Articulatio cubiti
- Articulatio humeri
- Articulatio radioulnaris distalis
- Articulatio sacroiliaca
- Articulatio sternoclavicularis
- Articulatio temporomandibularis

### B

- Bazální ganglia
- Biomechanika

- Biomechanika
- Biomechanika kolenního kloubu
- Biomechanika krevního oběhu
- Brocovo centrum řeči
- Brzlík
- Bránice
- Brániční kýla
- Bursa omentalis
- Bécclardův úhel

## C

- Calotův trojúhelník
- Canalis adductorius
- Canalis carpi
- Canalis cubitalis
- Canalis femoralis
- Canalis musculofibularis
- Canalis obturatorius
- Canalis pronatorius
- Canalis pudendalis
- Capsula interna
- Caput medusae
- Carpus
- Cavitas glenoidalis
- Cementum
- Centrální nervový systém
- Chirurgické přístupy k pankreatu
- Chlupy a vlasy
- Chopartův kloub
- Chrupavka
- Chuťová dráha
- Chámovod
- Cirkulace mozkomíšního moku
- Clavicula
- Concha nasalis inferior
- Corona mortis
- Cortex renalis
- Cortiho orgán
- Cytoarchitektonika mozkové kůry
- Cévní zásobení hrudní stěny (rozcestník)
- Cévní zásobení srdce
- Cévy dolní končetiny
- Cévy horní končetiny
- Cévy mozku
- Cévy močopohlavního systému

## D

- Uživatel:Da Bean Ye/Pískoviště
- Dentes molares
- Dentes premolares
- Dentinové tubuly
- Dentinum
- Destotův prostor
- Dextrokardie
- Diafýza
- Diastola
- Diastáza
- Diencephalon
- Difusní endokrinní systém
- Discus articularis
- Dlouhý natahovač palce (rozcestník)
- Dlouhý ohýbač palce (rozcestník)
- Dolní premoláry
- Dolní čelist
- Douglasův prostor
- Druhy skusu
- Druhý dolní premolár
- Druhý horní premolár
- Dráha zadních míšních provazců
- Duodenum
- Dura mater
- Dutina nosní
- Dutina ústní

- Děloha

## E

- Ejakulácia
- Ekrinní potní žlázy
- Uživatelka:Elle/Pískoviště
- Enamelum
- Endokard
- Endokrinní orgány
- Enoftalmus
- Enterický autonomní systém
- Epifýza
- Epifýza (část kosti)
- Epigastrium
- Epiglottis
- Epiglottis (histologický preparát)
- Epikantus
- Epikard
- Eponyma fraktur
- Eponyma v anatomii
- Eustachova trubice
- Extraglosální svaly

## F

- Falx inguinalis
- Fascia cervicalis
- Fascie bederní
- Fascie hlavy
- Femur
- Fibula
- Fissura scalenorum
- Foramen humerotricipitale
- Foramen infrapiriforme
- Foramen ischiadicum majus
- Foramen ischiadicum minus
- Foramen magnum
- Foramen omentale
- Foramen omotricipitale
- Foramen suprapiriforme
- Fossa axillaris
- Fossa cubitalis
- Fossa iliopectinea
- Fossa infratemporalis
- Fossa ischioanalís
- Fossa pterygopalatina
- Fossa supraclavicularis minor
- Fossa temporalis
- Foveola radialis
- Funkce míchy
- Funkce vývodných cest močových

## G

- Galea aponeurotica
- Ganglia
- Ganglion ciliare
- Ganglion pterygopalatinum
- Glandula parotis
- Glandula sublingualis
- Glandula submandibularis
- Glandulae vesiculosae
- Golgiho šlachové tělísko
- Guiotův prostor
- Guyonův kanál

## H

- Headovy zóny
- Hematoencefalická bariéra
- Hemiplegia alternans
- Hemiplegie
- Hiatus adductorius
- Hiatus basilicus

- Hiatus basilicus
- Hiatus saphenus
- Hilum renale
- Hladké svalstvo
- Hlasivky
- Hlavové nervy
- Hlavový parasimpatikus
- Hltan
- Hormony štítné žlázy
- Horní premoláry
- Hrdlo děložní
- Hrudní koš
- Hrudní nervy
- Humerus
- Hymen
- Hypofýza
- Hypospadie
- Hypothalamo-hypofysární systém
- Hypothalamus

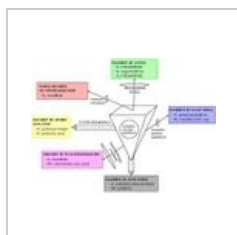
I

- Incisura scapulae
- Inervace hrudní stěny
- Inervace slinných žláz
- Inervace slzné žlázy
- Inervace svalu
- Interoreflexní dráhy
- Intraglosální svaly

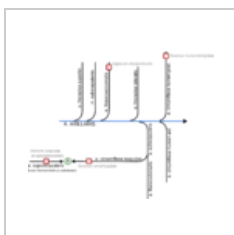(previous page) (next page)

## Media in category "Anatomie"

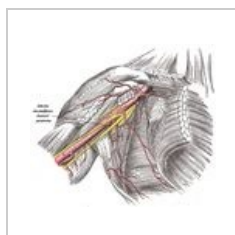
The following 146 files are in this category, out of 146 total.



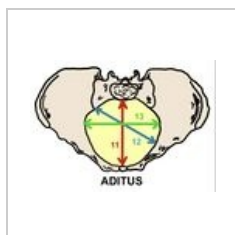
800px-Fossapter...  
800 × 582; 61 KB




A axillaris.png  
2,574 × 2,068; 229 KB



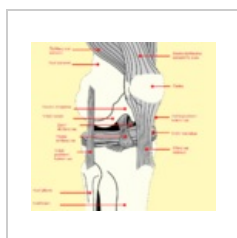A.circumflexa hum...  
683 × 600; 109 KB



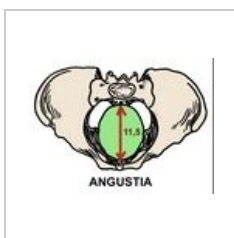Aditus pelvis.jpeg  
791 × 558; 100 KB



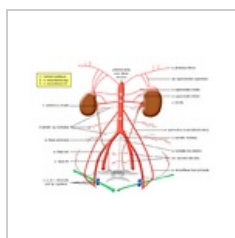
Amplitudo pelvis...  
744 × 562; 112 KB



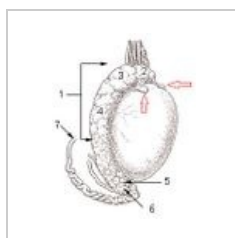
Anatomie kolena ...  
1,000 × 911; 181 KB



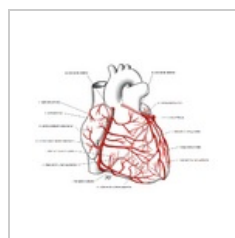
Angustia pelvis.j...  
737 × 541; 105 KB



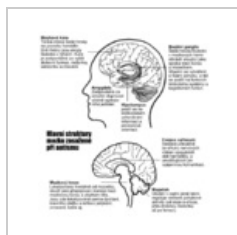
Aorta 1.png  
1,280 × 960; 370 KB



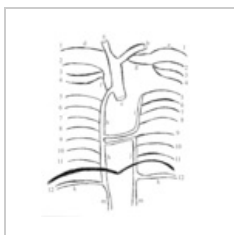
Apendix varlete ...  
194 × 250; 31 KB



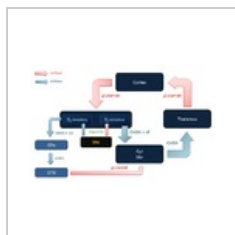
Arteriae coronari...  
871 × 633; 284 KB



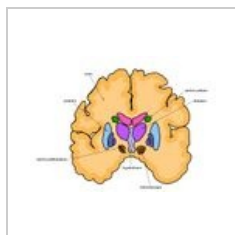
Autismbrain cs.png  
500 × 540; 171 KB



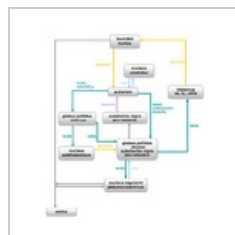
Azyg final.png  
518 × 595; 52 KB



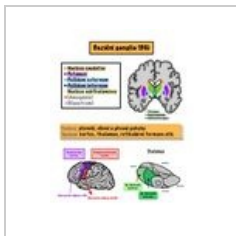
Bazalni ganglia.p...  
923 × 588; 50 KB



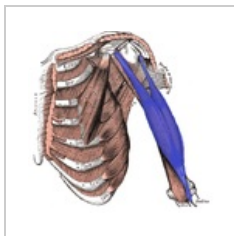
Bazální ganglia.jpg  
1,365 × 1,000; 447 KB



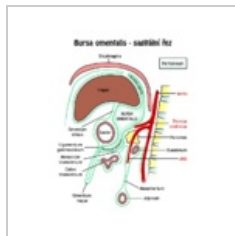
BG zapojení.png  
563 × 651; 50 KB



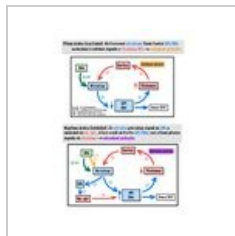
BG1.jpeg  
1,668 × 2,154; 555 KB



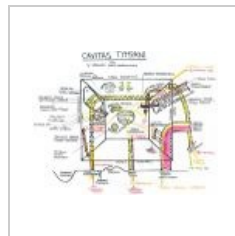
Bicepsbrachii bar...  
557 × 547; 257 KB



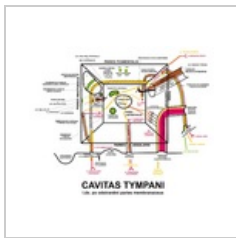Bursa omentalis....  
640 × 782; 60 KB



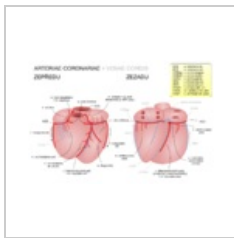
C7D53B82-71A0-...  
1,668 × 2,154; 488 KB



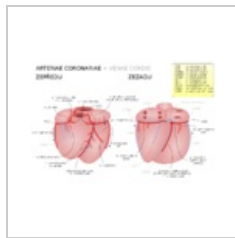
Cavitas tympani.j...  
960 × 747; 165 KB



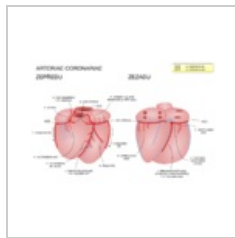
Cavitas tympani...  
1,200 × 982; 523 KB



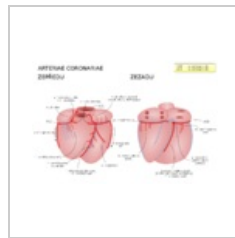
Cevy srdce aa vv...  
1,080 × 720; 265 KB



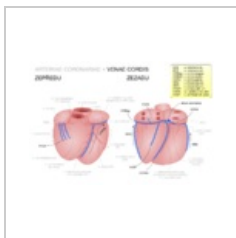
Cevy srdce aa vv...  
1,080 × 720; 66 KB



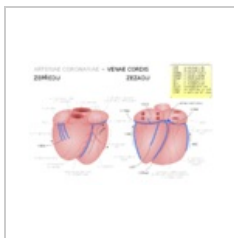
Cevy srdce aa.png  
1,080 × 720; 211 KB



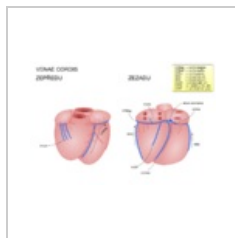
Cevy srdce aa.svg  
1,080 × 720; 56 KB



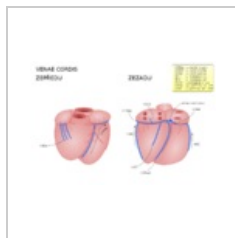
Cevy srdce vv aa...  
1,080 × 720; 257 KB



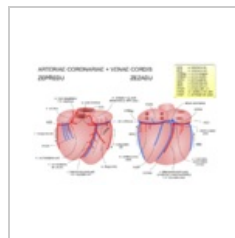
Cevy srdce vv aa...  
1,080 × 720; 66 KB



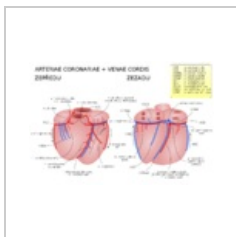
Cevy srdce vv.png  
1,080 × 720; 179 KB



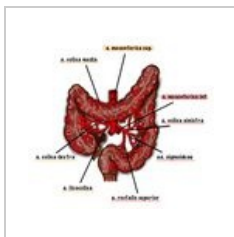
Cevy srdce vv.svg  
1,080 × 720; 49 KB



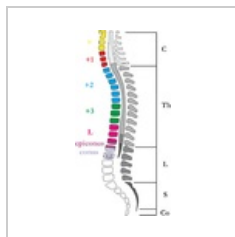Cevy srdce.png  
1,080 × 720; 270 KB



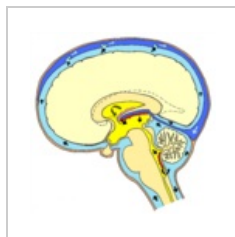
Cevy srdce.svg  
1,080 × 720; 66 KB



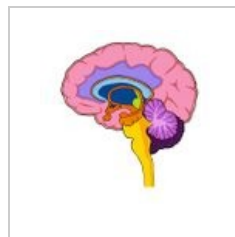
Cevy colon.jpg  
1,589 × 1,481; 300 KB



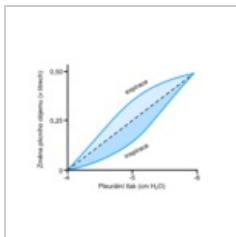
Chipault.png  
600 × 1,166; 205 KB



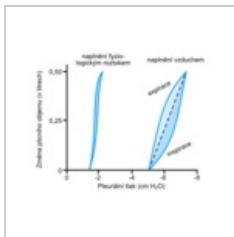
Cirkulace likvoru...  
2,093 × 2,057; 2.37 MB



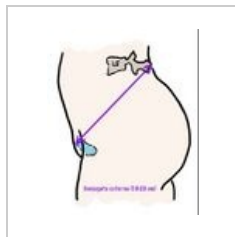
CNS nákres.jpg  
1,000 × 1,090; 132 KB



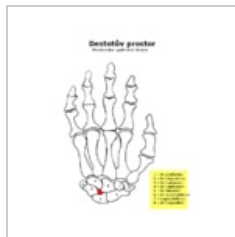
Compliance 1.png  
340 × 280; 21 KB



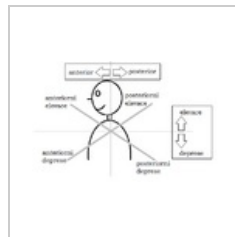
Compliance 2.png  
340 × 280; 25 KB



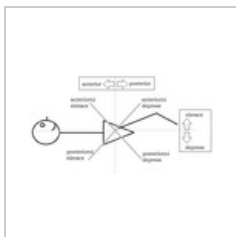
Conjugata extern...  
914 × 1,114; 97 KB



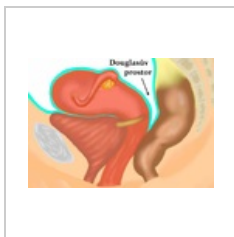
Destotův prostor...  
562 × 750; 33 KB




Diagonály lopatk...  
476 × 309; 11 KB



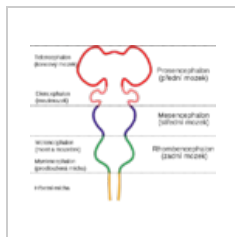
Diagonály pánve...  
598 × 325; 12 KB



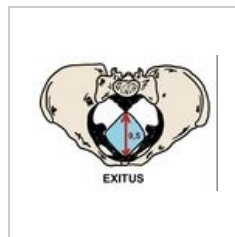
Douglasův prost...  
1,148 × 802; 599 KB



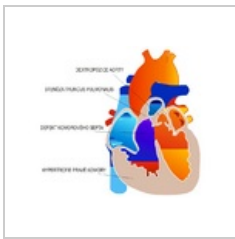
Edem plic.png  
520 × 380; 20 KB



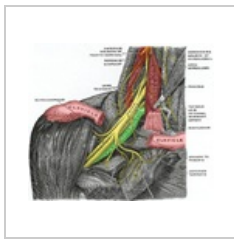
Embryonální moz...  
710 × 599; 57 KB



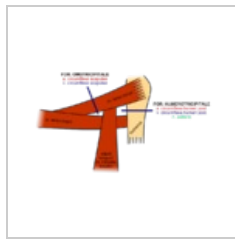
Exitus pelvis.jpeg  
777 × 569; 105 KB



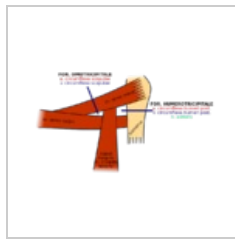
Fallotova tetralo...  
744 × 609; 139 KB



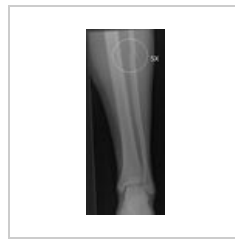Fissura scalenoru...  
575 × 488; 489 KB



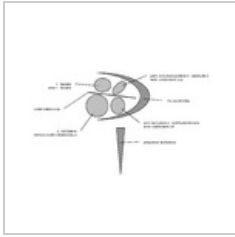
Foramina.png  
700 × 450; 53 KB



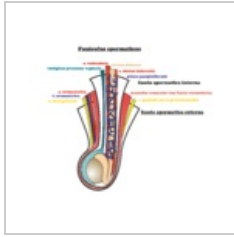
Foramina.svg  
700 × 450; 22 KB



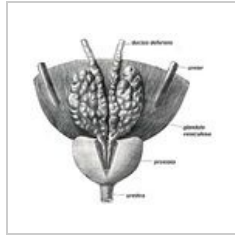
Fracturafibulae.JPG  
304 × 712; 12 KB



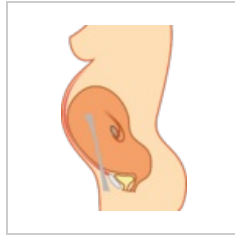
Fundus MAI.png  
1,256 × 800; 17 KB



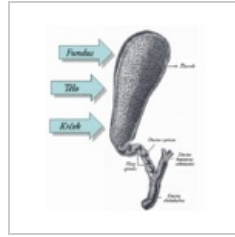
Funisperm.png  
2,573 × 2,145; 882 KB



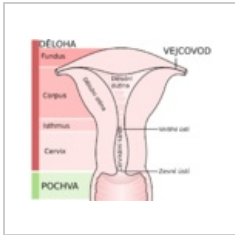
Glandula vesicul...  
420 × 388; 84 KB



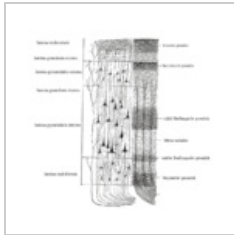
Graviteres.png  
1,036 × 1,539; 153 KB



Gray1095 cs.png  
478 × 555; 62 KB



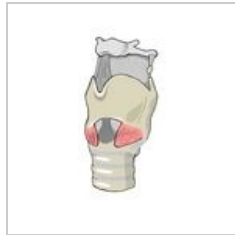Gray1167 cz.svg  
824 × 721; 70 KB



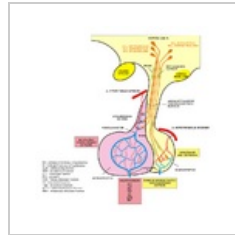
Gray754 cs.png  
700 × 680; 257 KB



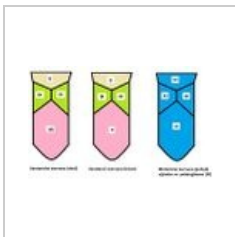
Herniace disku.jpg  
300 × 514; 59 KB



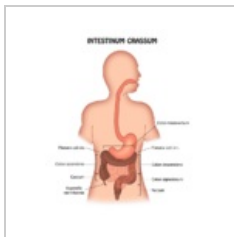
Hrtan - nákres.jpg  
1,000 × 2,041; 461 KB



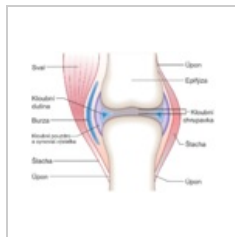
Hypofyzarni obe...  
747 × 765; 194 KB



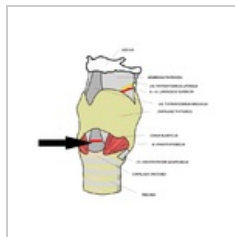
Inervace jazyka.J...  
491 × 298; 30 KB



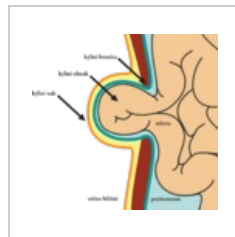
Intestinum crass...  
660 × 780; 57 KB



Joint cs.png  
882 × 676; 233 KB



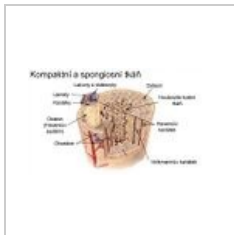Koniotomie.png  
678 × 600; 152 KB



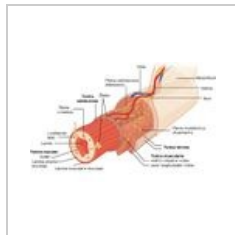
Kýla.png  
1,735 × 1,644; 262 KB



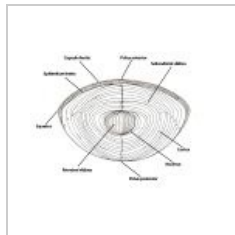
Labutí šíje.png  
1,030 × 616; 362 KB



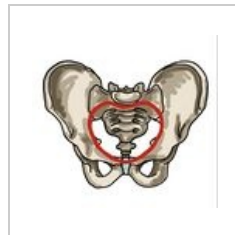
Lamelosní kost (s...  
520 × 300; 83 KB



Layers of the gas...  
800 × 515; 117 KB



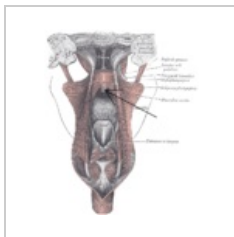
LensII.jpg  
960 × 720; 91 KB



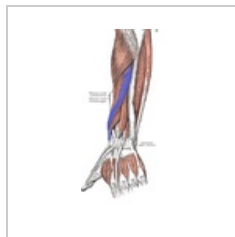Linea terminalis.j...  
951 × 890; 168 KB



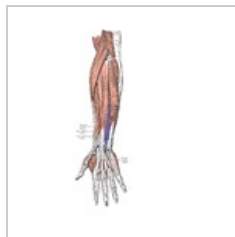Lymf odtok prsu.j...  
1,448 × 1,236; 162 KB



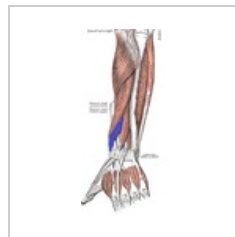M. uvulae šipka.p...  
700 × 840; 331 KB



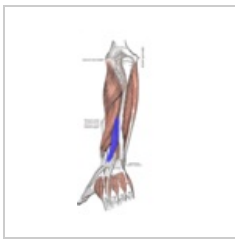M.abductorpollici...  
241 × 520; 132 KB



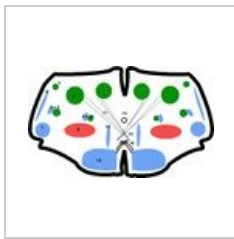
M.extensordigiti...  
728 × 1,296; 192 KB



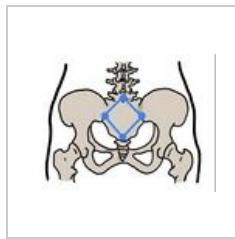
M.extenzorpollici...  
238 × 504; 139 KB



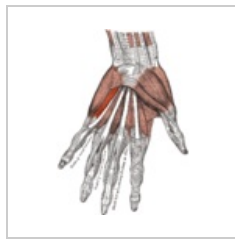M.extenzorpollici...  
281 × 602; 153 KB



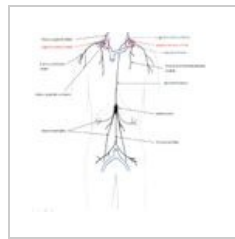
Medulla oblongat...  
640 × 383; 78 KB



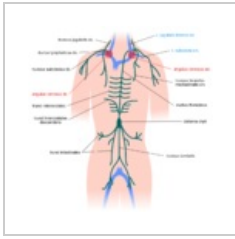
Michaelisova rou...  
902 × 671; 120 KB



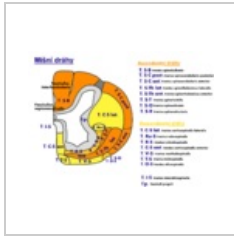
Musculus flexor d...  
636 × 882; 295 KB



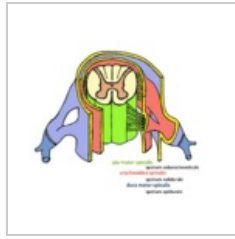Mízní kmeny.jpg  
1,490 × 1,436; 235 KB



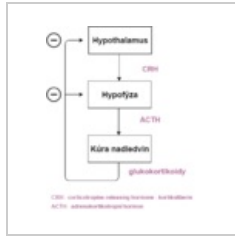Mízní kmeny.png  
1,400 × 1,400; 258 KB



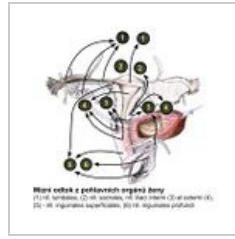
Míšní dráhy.png  
1,533 × 1,124; 309 KB



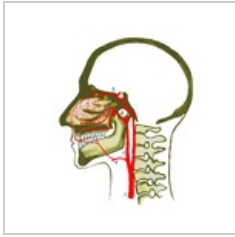
Míšní obaly.png  
1,261 × 1,072; 1,023 KB



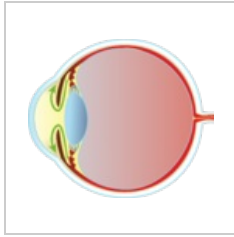
Negativní zpětná...  
342 × 411; 21 KB



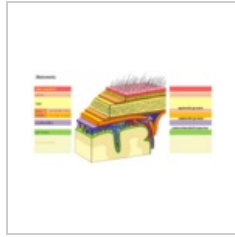
Nodi feminini.jpg  
1,024 × 1,024; 136 KB



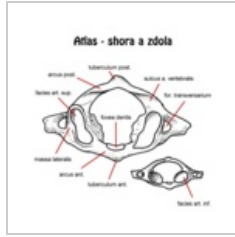
Nos-cévy.png  
2,048 × 2,048; 712 KB



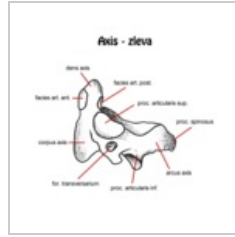
NT1.png  
2,463 × 2,119; 469 KB



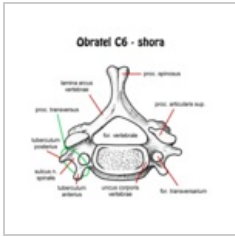
Obaly mozku.png  
2,081 × 1,077; 1.46 MB



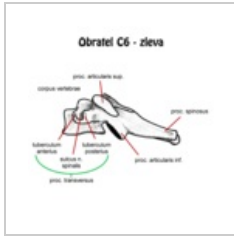
Obratel atlas.png  
600 × 600; 64 KB



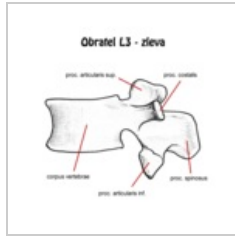
Obratel axis zlev...  
600 × 600; 43 KB



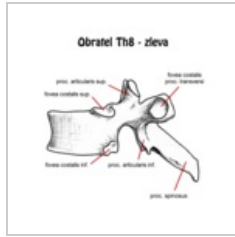
Obratel C6 shora...  
600 × 600; 70 KB



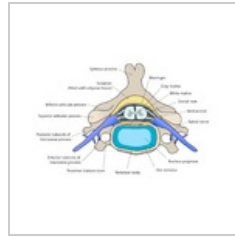
Obratel C6 zleva...  
600 × 600; 44 KB



Obratel L3 zleva...  
600 × 600; 68 KB



Obratel Th8 zlev...  
600 × 600; 61 KB



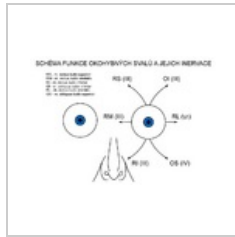
Obratel.png  
1,883 × 1,317; 253 KB



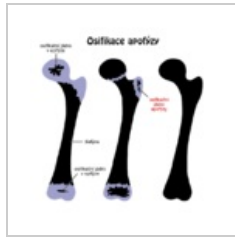
Obrna medianu.p...  
640 × 699; 206 KB



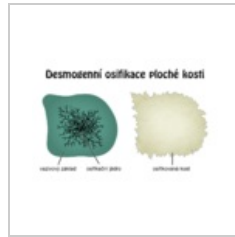
Obrna n.ulnaris.p...  
486 × 604; 120 KB



Okohybné svaly....  
800 × 556; 88 KB



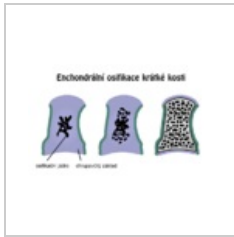Osifikace apofýz...  
700 × 700; 28 KB



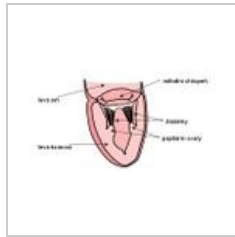
Osifikace desmo...  
900 × 600; 124 KB



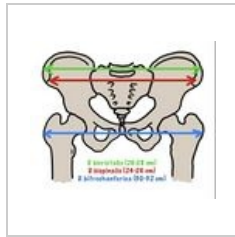Osifikace dlouhé ...  
1,050 × 650; 73 KB



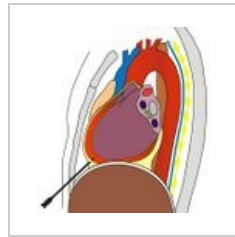
Osifikace krátké ...  
750 × 450; 36 KB



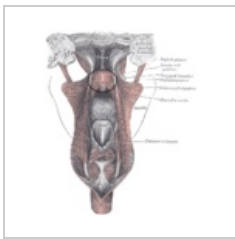
Papilarnisval.JPG  
526 × 293; 19 KB



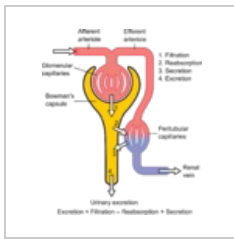
Pelvimetrické vyš...  
870 × 742; 147 KB



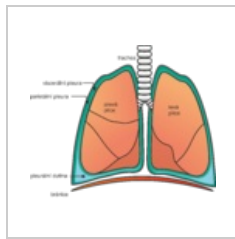
Perikardiocentez...  
513 × 535; 108 KB



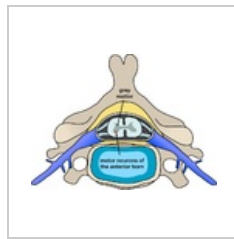
Pharyngopalatin...  
700 × 840; 332 KB



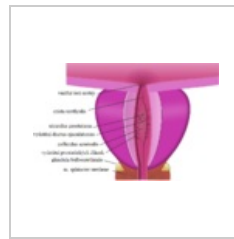Physiology of Ne...  
1,046 × 1,221; 166 KB



Pleura.png  
2,611 × 2,199; 556 KB



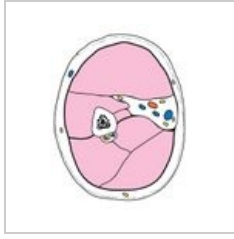
Polio spinal diagr...  
800 × 588; 197 KB



Prostata.png  
842 × 536; 144 KB




Receptory.png  
1,024 × 853; 70 KB



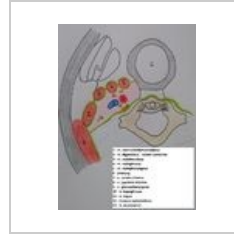Regio brachialis.j...  
542 × 703; 73 KB



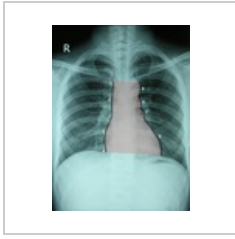Scapula ant num...  
600 × 755; 523 KB



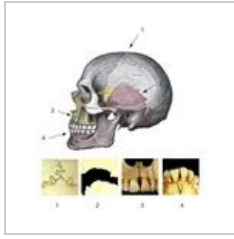
Scapula post nu...  
600 × 792; 564 KB



Spatium parapha...  
2,340 × 3,137; 1.26 MB




Srdetni stin.png  
2,026 × 2,743; 5.25 MB



Suturas.jpg  
716 × 778; 249 KB



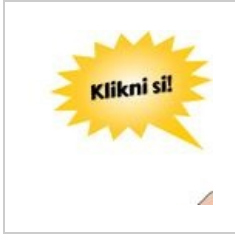Svalovec1.png  
1,200 × 1,126; 6 KB



Svalovec10.png  
3,000 × 543; 27 KB



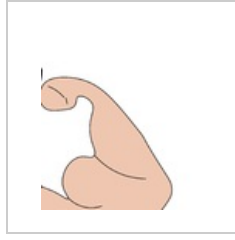
Svalovec11.png  
3,000 × 1,087; 52 KB



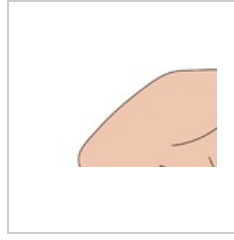
Svalovec1a.jpg  
641 × 602; 31 KB



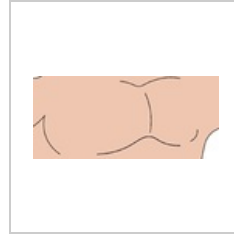Svalovec2.png  
801 × 1,126; 36 KB



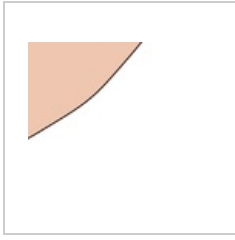
Svalovec3.png  
999 × 1,126; 22 KB



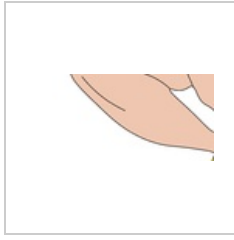
Svalovec4.png  
1,050 × 563; 9 KB



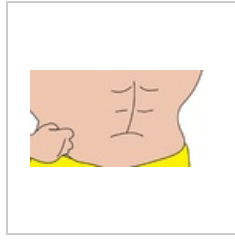
Svalovec5.png  
1,268 × 563; 13 KB



Svalovec6.png  
682 × 563; 4 KB



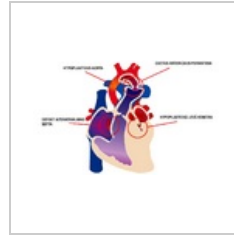
Svalovec7.png  
1,200 × 563; 14 KB



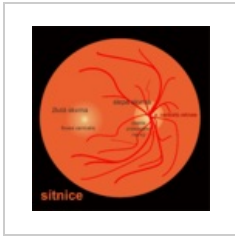
Svalovec8.png  
1,080 × 563; 17 KB



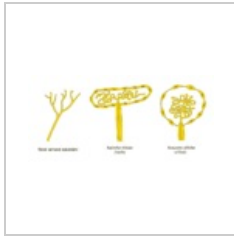Svalovec9.png  
720 × 563; 2 KB



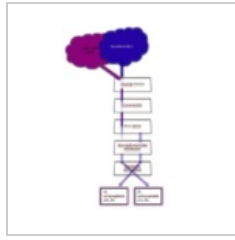
Syndrom hypopl...  
967 × 599; 157 KB



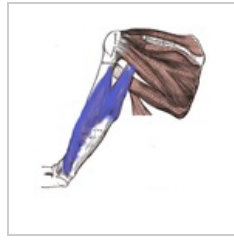Sítnice.png  
1,991 × 2,072; 357 KB



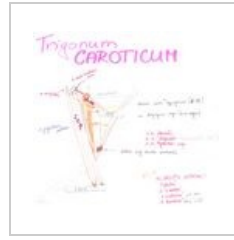
Termoreceptory....  
850 × 400; 24 KB



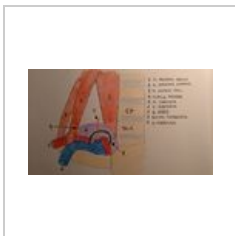Tractus.png  
459 × 689; 93 KB



Tricepsbrachii.png  
580 × 594; 201 KB



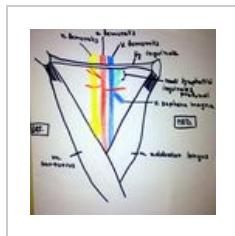
Trigonum carotic...  
2,218 × 2,104; 218 KB



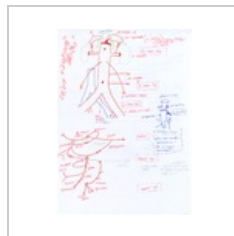Trigonum scalen...  
4,160 × 2,340; 2.1 MB



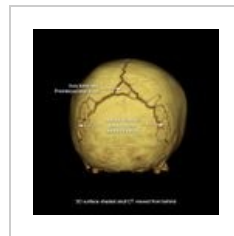
Trigonum subma...  
3,472 × 2,480; 479 KB



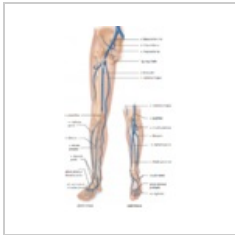Trigonumfemoral...  
2,448 × 2,448; 3.93 MB



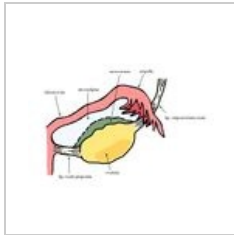
Větvení břišní ao...  
2,550 × 3,510; 11.73 MB



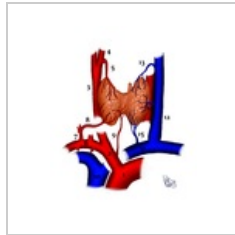
WormianBones.jpg  
820 × 820; 65 KB



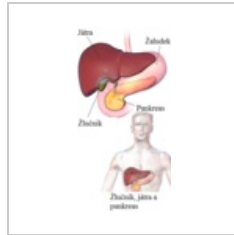
ZilyDK.png  
579 × 957; 424 KB



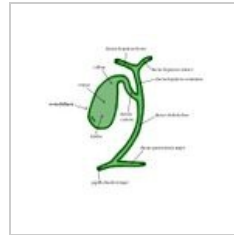
Závěs vaječníku.j...  
1,347 × 1,000; 299 KB



Šž - zásobení.png  
1,406 × 1,776; 1.01 MB



Žlučník, játra, pa...  
300 × 600; 167 KB



Žlučové cesty - n...  
1,089 × 1,000; 228 KB



Žíly mozku.jpg  
798 × 993; 220 KB