

Kategorie:EKG

Subcategories

This category has the following 3 subcategories, out of 3 total.

E

- Ecgpedia.org (empty)

P

- Převzatá EKG (2 C)

S

- Stefajir.cz (EKG) (38 F)

Pages in category "EKG"

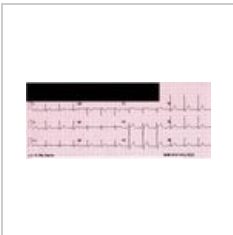
This category contains only the following page.

E

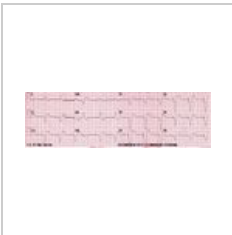
- Portál:EKG

Media in category "EKG"

The following 64 files are in this category, out of 64 total.



12 lead generate...
864 × 350; 213 KB




12 lead paced.jpg
864 × 260; 222 KB



12leadECG (pozn...
1,040 × 407; 175 KB



AIM - evolvece.png
800 × 175; 16 KB



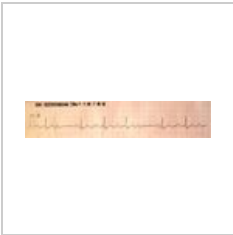
AP.png
1,000 × 561; 55 KB



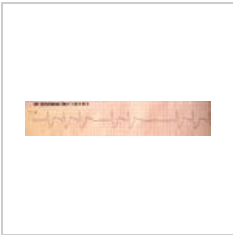Asystolie.JPG
2,564 × 577; 1.09 MB



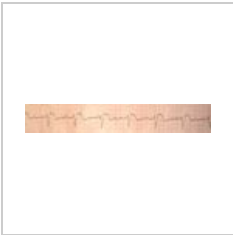AV-I.JPG
2,176 × 354; 705 KB



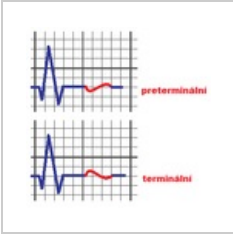
AV-II-1typ.JPG
2,003 × 380; 697 KB



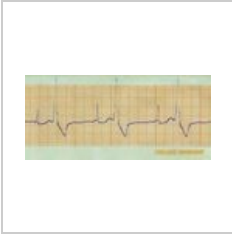
AV-II.JPG
2,204 × 400; 704 KB




AV-III.JPG
2,588 × 382; 729 KB




Bifázická T vlna.p...
335 × 326; 7 KB



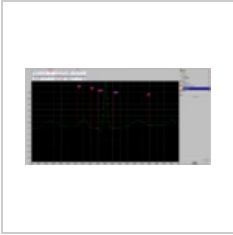
Bigeminie.jpg
800 × 365; 84 KB



Brugada syndro...
800 × 473; 307 KB




BTL08Win avrg 3...
1,920 × 1,004; 181 KB




BTL08Win avrg.p...
1,918 × 998; 166 KB



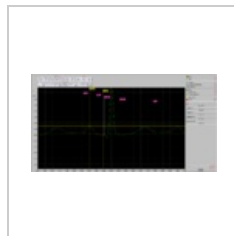
BTL08Win II dg.png
1,920 × 1,057; 199 KB



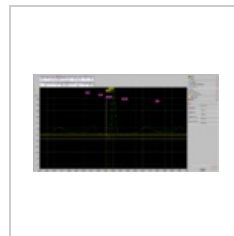
BTL08Win nahled...
1,352 × 863; 288 KB



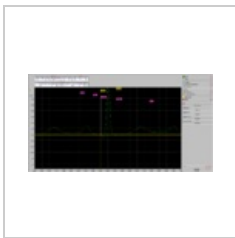BTL08Win nahled...
1,358 × 865; 254 KB



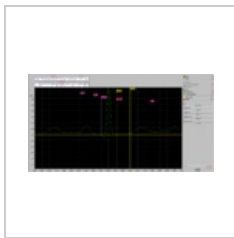BTL08Win P-amp...
1,920 × 1,002; 193 KB



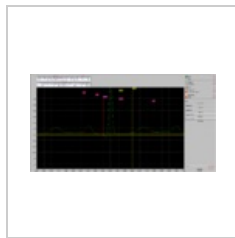BTL08Win Q-amp...
1,920 × 1,001; 189 KB



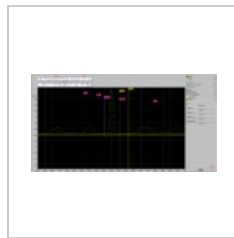
BTL08Win ST-de...
1,920 × 1,001; 190 KB



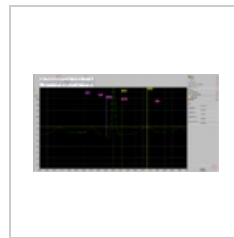
BTL08Win ST-seg...
1,920 × 1,002; 192 KB



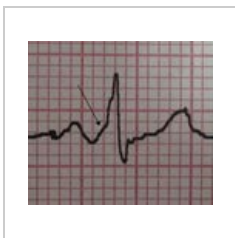
BTL08Win ST-seg...
1,920 × 1,001; 184 KB



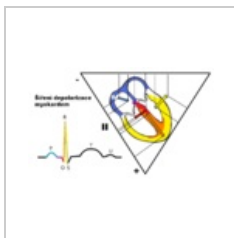
BTL08Win ST-skl...
1,920 × 1,001; 192 KB



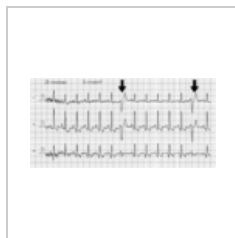
BTL08Win T-amp...
1,920 × 1,004; 192 KB



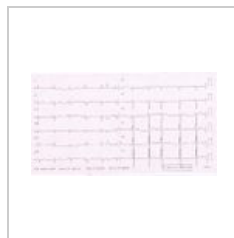Delta vlny při WP...
681 × 600; 60 KB



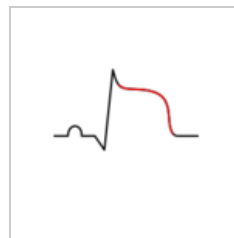
Depolarizace.png
1,715 × 1,025; 302 KB



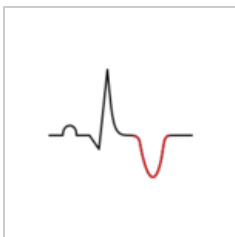
EKG - KES.png
617 × 299; 4 KB




Ekg disekce aort...
975 × 542; 124 KB



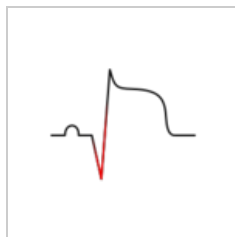
EKG elevace ST.s...
200 × 150; 3 KB



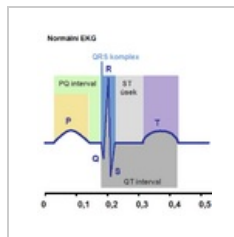
EKG inverze T.svg
200 × 150; 3 KB



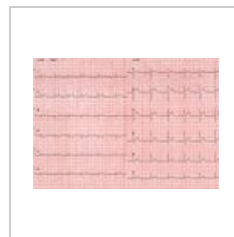Ekg normal.jpg
807 × 585; 59 KB



EKG pato Q.svg
200 × 150; 4 KB



Ekg-schema.png
387 × 411; 6 KB



Electrocardiogra...
2,000 × 1,413; 4.67 MB



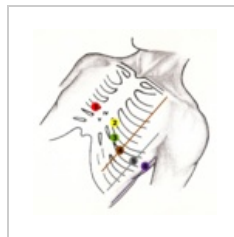Fibrilace-komor.JPG
2,219 × 440; 832 KB



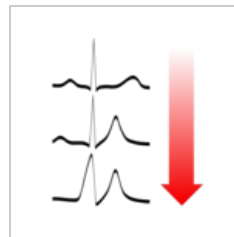
FlutterSINE.JPG
1,988 × 443; 715 KB



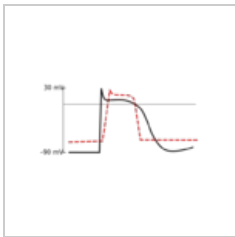
FS.JPG
2,032 × 445; 652 KB



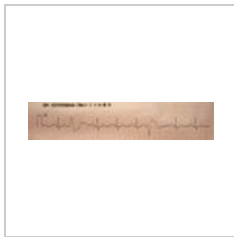Hrudní svody.png
2,058 × 2,070; 4.55 MB



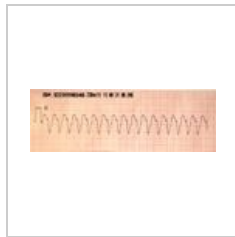
Hyperkalémie EK...
550 × 600; 25 KB



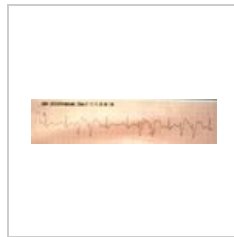
Hyperkalémie ka...
613 × 312; 35 KB



KES.JPG
2,093 × 422; 573 KB



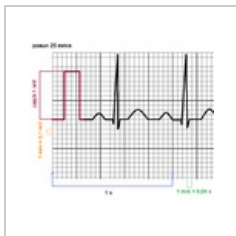
KT.JPG
1,686 × 556; 780 KB



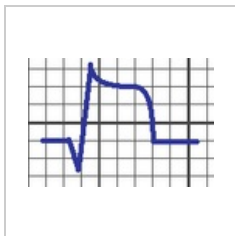
Kuplety.jpg
2,024 × 484; 866 KB



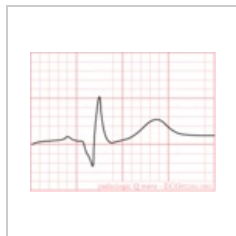
LQT.png
800 × 235; 118 KB



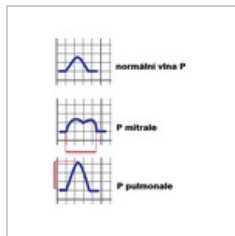
ParametryEKG.png
664 × 577; 21 KB



Pardeeho vlna.png
180 × 124; 2 KB



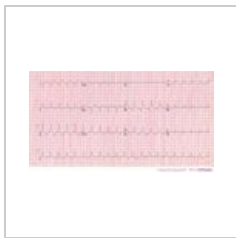Patologické q.png
800 × 599; 10 KB



Patologie P vlny....
280 × 359; 6 KB




Postup výpočtu - ...
1,231 × 768; 522 KB



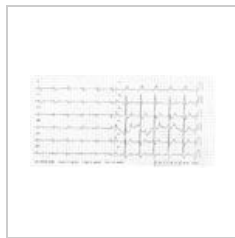
Pulm embolism e...
2,149 × 1,182;
1.01 MB



RBBB 4 1.jpg
3,373 × 1,277;
1.34 MB



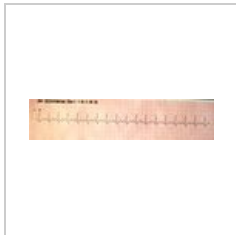
RBBB 4 2.jpg
3,345 × 1,633;
1.69 MB



RBBB 4 3.jpg
3,381 × 1,689;
1.68 MB



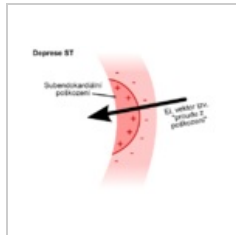
SINUS-BRADY.JPG
2,420 × 332; 570 KB



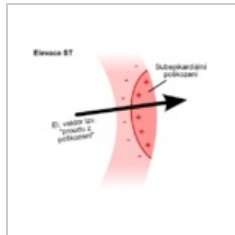
SINUS-TACHY.JPG
2,291 × 494; 915 KB



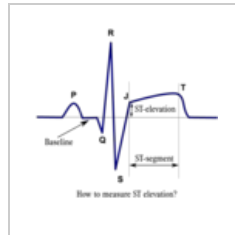
Sinus.JPG
2,147 × 250; 461 KB



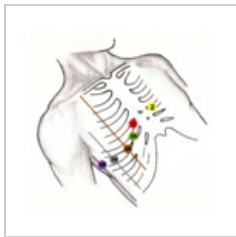ST deprese myok...
500 × 400; 31 KB



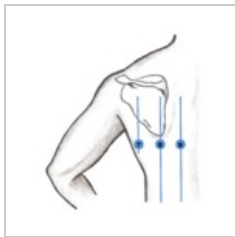
ST elevace myok...
500 × 400; 30 KB



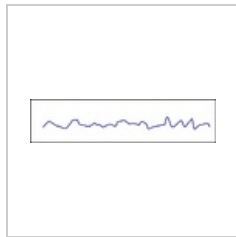
ST elevace.png
597 × 600; 35 KB



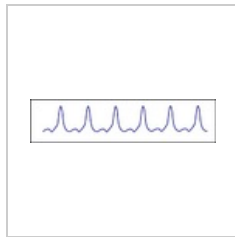
V3R-V6R.png
2,081 × 2,069; 4.6 MB



V789.png
1,684 × 1,844; 1.5 MB



VF - scheme.png
800 × 184; 31 KB



VT - scheme.png
800 × 184; 56 KB