

Kategorie:Histologická schémata

Pages in category "Histologická schémata"

The following 6 pages are in this category, out of 6 total.

D

- Dýchací systém (praktikum) (1. LF UK)

H

- Portál:Histologické praktikum (1. LF UK)

K

- Kardie (histologický preparát)

L

- Lymfatický systém (praktikum) (1. LF UK)

O

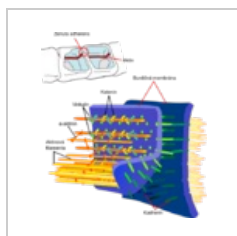
- Obecné zásady mikroskopování

Ž

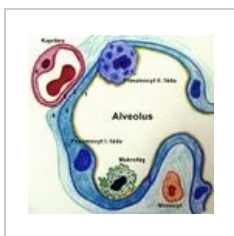
- Žláznový epitel (praktikum) (1. LF UK)

Media in category "Histologická schémata"

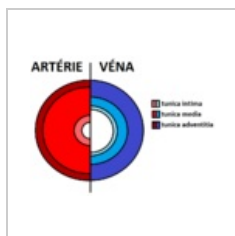
The following 69 files are in this category, out of 69 total.



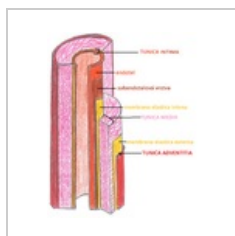
Adherens Junctio...
490 × 548; 117 KB



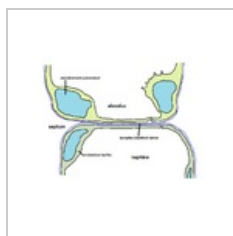
Alveolo-kapilární ...
1,286 × 1,238; 439 KB




Arterie vena.png
798 × 606; 26 KB



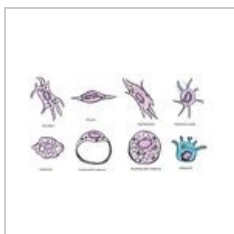
Arterie vena2.png
1,248 × 1,532;
1.99 MB



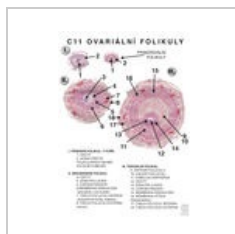
Bariera.png
1,037 × 782; 46 KB



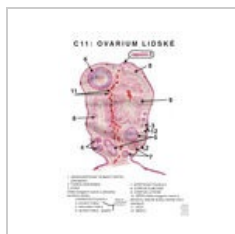
Barvicí metody.JPG
550 × 327; 64 KB



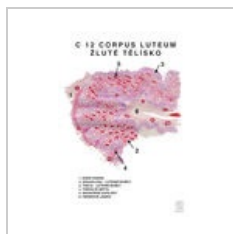Buňky fixní.jpg
1,673 × 930; 309 KB



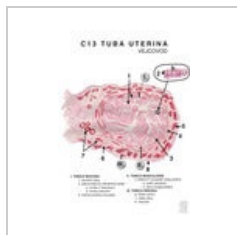
C11 detail.jpg
1,600 × 2,264;
1.42 MB



C11 Ovarium.jpg
1,600 × 2,264;
1.59 MB



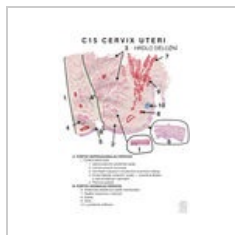C12 Corpus luteu...
1,600 × 2,264;
1.51 MB



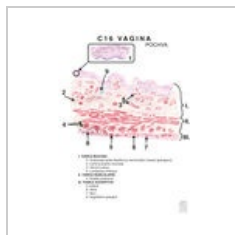C13 Tuba uterina...
1,600 × 2,264;
1.51 MB



C14 Corpus uteri...
595 × 842; 329 KB



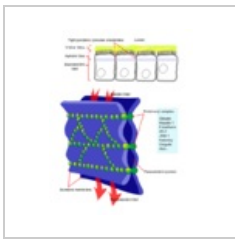
C15 Cervix uteri.j...
1,600 × 2,264;
1.42 MB



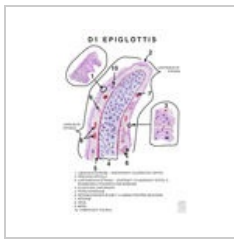C16 Vagina.jpg
1,600 × 2,264;
1.16 MB



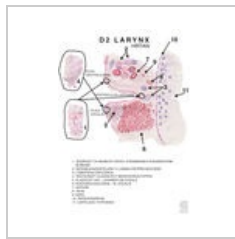C17 Endometriu...
1,600 × 2,264; 785 KB



Cellular tight jun...
499 × 646; 116 KB



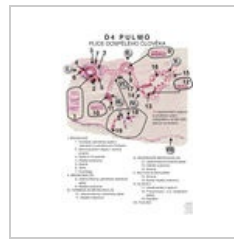D1 Epiglottis.jpg
1,600 × 2,264;
1.29 MB



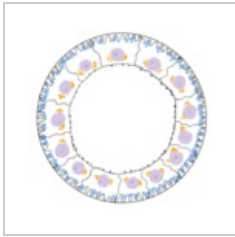
D2 Larynx.jpg
1,600 × 2,264;
1.32 MB




D3 Trachea.jpg
1,600 × 2,264; 915
KB



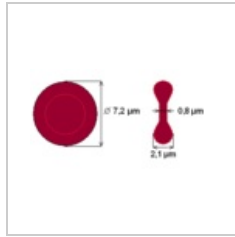
D4 Pulmo.jpg
1,600 × 2,264; 603
KB



Distalni tubulus s...
302 × 292; 46 KB



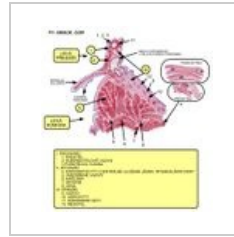
Dvojvrstva.jpg
569 × 398; 45 KB



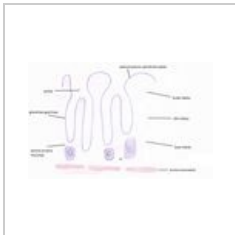
Ery-schema.png
359 × 192; 4 KB



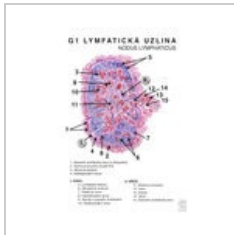
Erythrocyty.png
800 × 282; 301 KB



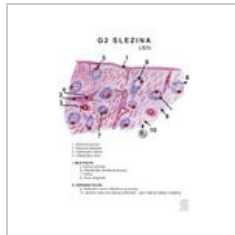F1 cor.jpg
1,175 × 1,275; 275
KB



Fundus.jpg
2,429 × 1,521; 404
KB



G1.jpg
1,600 × 2,264; 533
KB



G2.jpg
1,600 × 2,264; 565
KB



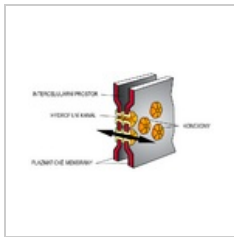
G3.jpg
1,600 × 2,264; 412
KB



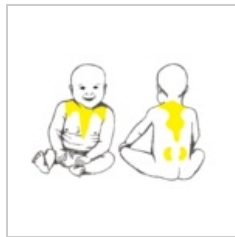
G4.jpg
1,600 × 2,264;
1.44 MB



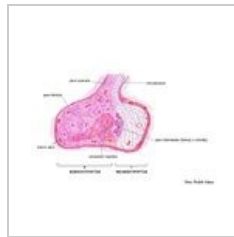G5-Brzlík-dospělé...
1,600 × 2,264; 315
KB



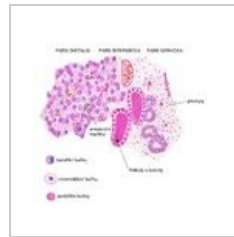Gap junctions.png
800 × 435; 106 KB



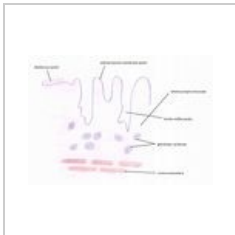
Hnědá tuková tk...
1,709 × 1,238; 790
KB



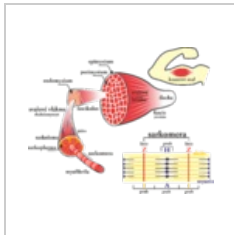
Hypofyza-schem...
4,288 × 2,952;
1.71 MB



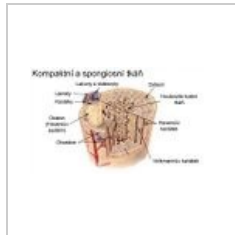
Hypofyza-schem...
3,048 × 3,000;
1.81 MB



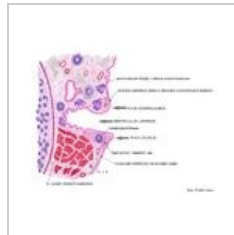
Kardie nakres.jpg
2,457 × 1,729; 469
KB



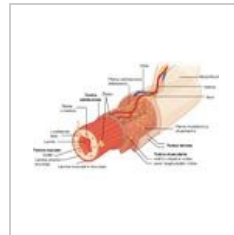
Kosterní sval.png
2,887 × 2,281; 974
KB



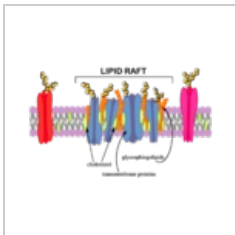
Lamelosní kost (s...
520 × 300; 83 KB



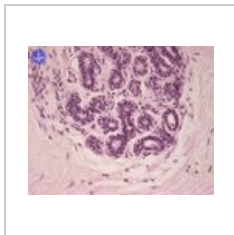
Larynx-schema.jpg
4,052 × 3,184;
2.02 MB



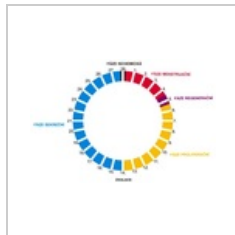Layers of the gas...
800 × 515; 117 KB



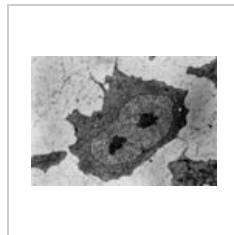
Lipid Raft-.png
300 × 183; 50 KB



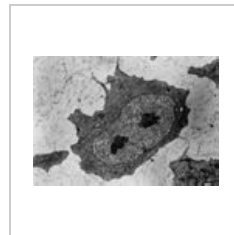
Mamma nonlacta...
600 × 480; 54 KB



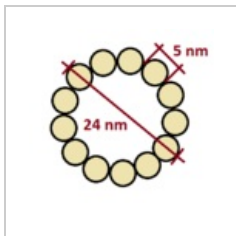
Menstruacni cykl...
600 × 401; 63 KB



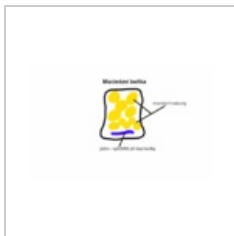Mesenchymová bu...
2,007 × 1,407; 354
KB



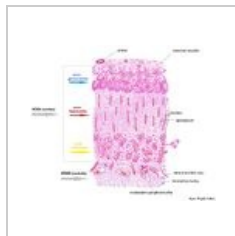
Mesenchymová b...
454 × 318; 86 KB



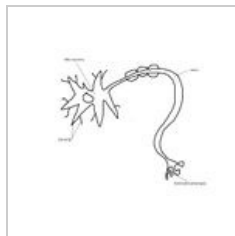
Mikrotubulus.png
400 × 400; 12 KB




Mucinózní buňka...
1,280 × 800; 81 KB




Nadledvinasche...
5,288 × 4,472; 3.75 MB



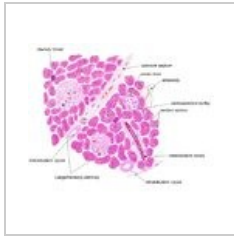Neuron-a-jeho-st...
768 × 614; 50 KB



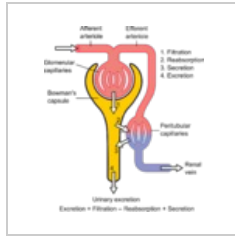
Organy.png
676 × 414; 47 KB



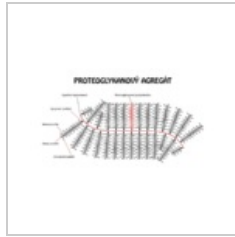
Osifikace dlouhé ...
1,050 × 650; 73 KB



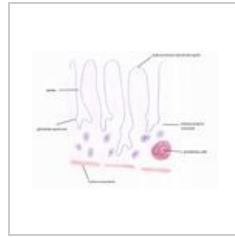
Pankreas-schem...
4,312 × 3,542; 2.5 MB



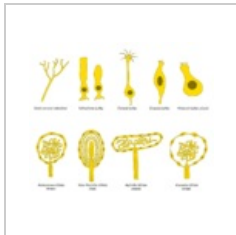Physiology of Ne...
1,046 × 1,221; 166 KB



Proteoglykan.png
1,080 × 600; 89 KB



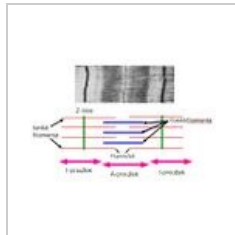
Pylorus nakres.jpg
2,385 × 1,769; 492 KB



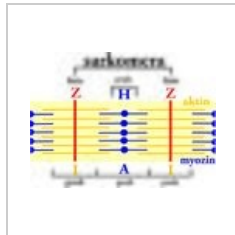
Receptory.png
1,024 × 853; 70 KB



Retina.png
2,744 × 1,722; 1.06 MB



Sarkomera.JPG
500 × 336; 23 KB



Sarkomera.jpg
1,349 × 985; 2.13 MB

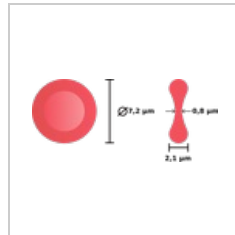


Schéma erythrocy...
276 × 123; 10 KB

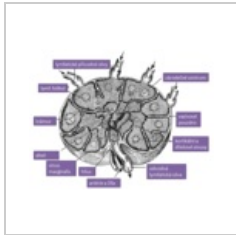
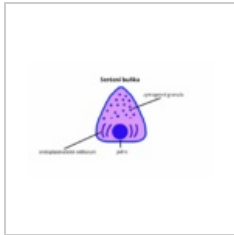
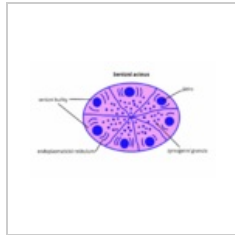


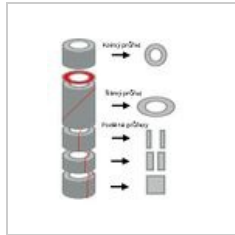
Schéma lymfatic...
603 × 457; 146 KB



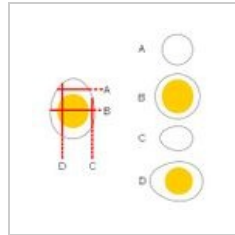
Serozni bunka.png
1,280 × 800; 86 KB



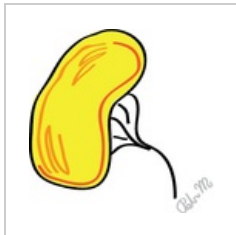
Serózní acinus.png
1,280 × 800; 217 KB



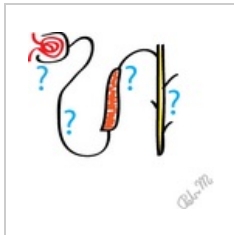Trubice.jpg
243 × 298; 14 KB



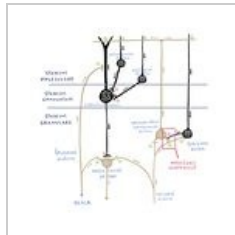
Vejce.jpg
304 × 298; 13 KB



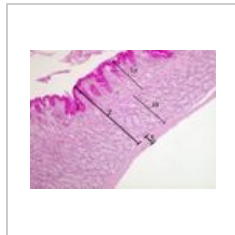Vylučovací soust...
260 × 257; 15 KB



Vylučovací soust...
268 × 257; 11 KB



Zapojení mozek...
2,042 × 2,042; 398 KB



Žaludek fundus 2...
1,037 × 778; 283 KB