

# Kategorie:Obrázky s anotacemi

## Subcategories

This category has only the following subcategory.

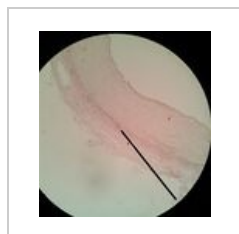### O

► Obrázky s 10+ anotacemi (12 F)

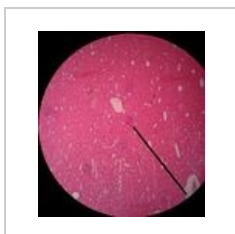## Media in category "Obrázky s anotacemi"

The following 200 files are in this category, out of 308 total.

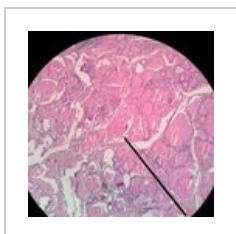
(previous page) (next page)



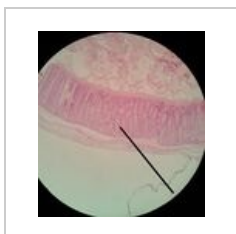
01 Svalova arteri...  
1,920 × 2,068; 933 KB



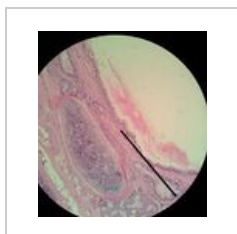
02 Ledvina.jpg  
1,920 × 2,137; 1.09 MB



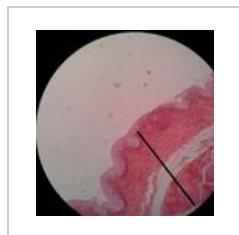03 Stitna zlaza.jpg  
1,920 × 1,920; 1.28 MB



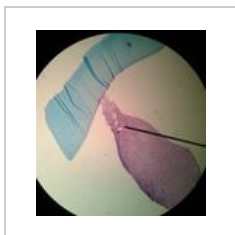
04 Tluste strevo.j...  
1,920 × 2,127; 1.03 MB



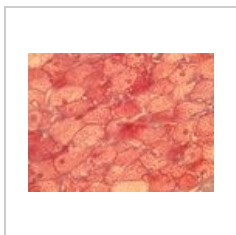
06 Bronchus.jpg  
1,920 × 2,112; 1.14 MB



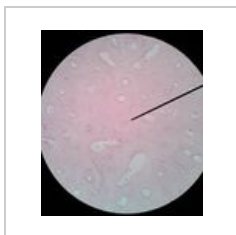07 Mocovy mech...  
1,920 × 2,004; 852 KB



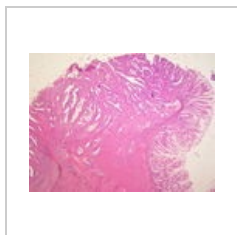
19 Mesenchym 4...  
1,920 × 2,087; 952 KB



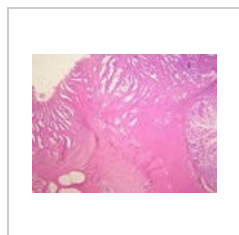
22 c Hnedý tuk 4...  
2,592 × 1,944; 2.83 MB



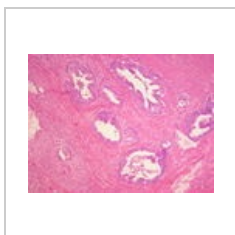29 b lamelární k...  
1,920 × 2,191; 973 KB



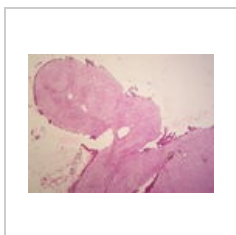
Adenokarcinom t...  
3,264 × 2,448; 1.63 MB



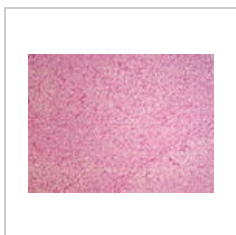Adenokarcinom t...  
3,264 × 2,448; 1.61 MB



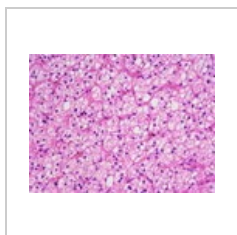
Adenokarcinom t...  
3,264 × 2,448; 1.36 MB



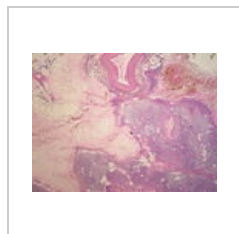
Adenom nadledvi...  
3,264 × 2,448; 1.42 MB



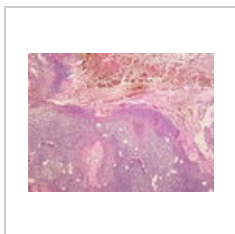
Adenom nadledvi...  
3,264 × 2,448; 1.31 MB



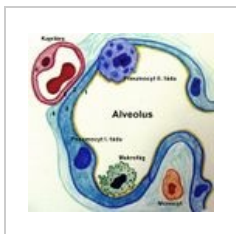
Adenom nadledvi...  
3,264 × 2,448; 1.39 MB



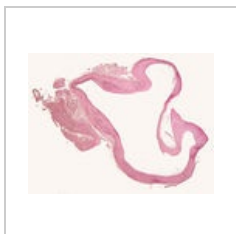
Akutní hemoragi...  
3,264 × 2,448; 1.77 MB



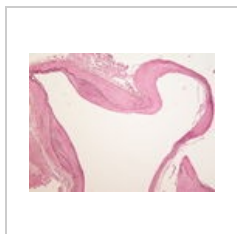
Akutní hemoragi...  
3,264 × 2,448; 1.34 MB



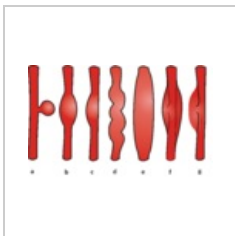
Alveolo-kapilární ...  
1,286 × 1,238; 439 KB



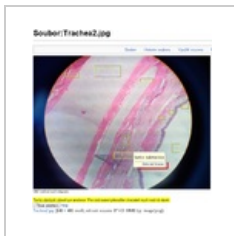Aneurysma mozku...  
2,800 × 2,132; 625 KB



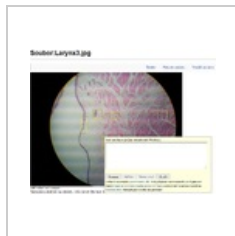Aneurysma mozku...  
3,264 × 2,448; 1.55 MB



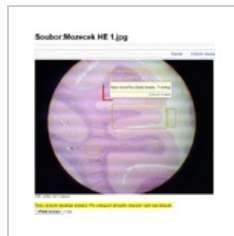Aneurysmata.png  
3,116 × 1,954;  
1.05 MB



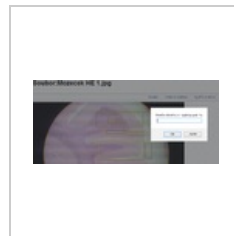Anotování-nápop...  
650 × 668; 578 KB



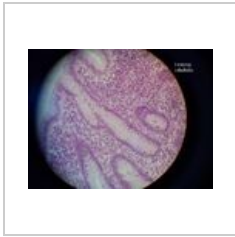
Anotování-nápop...  
783 × 614; 414 KB



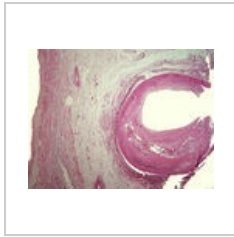
Anotování-nápop...  
652 × 664; 490 KB



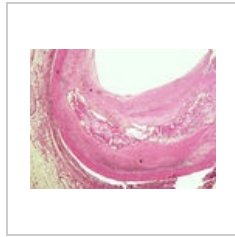
Anotování-nápop...  
786 × 356; 287 KB



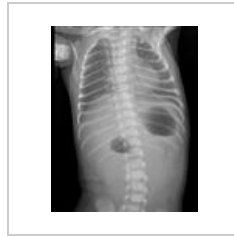Appendix3 -a.jpg  
640 × 480; 51 KB



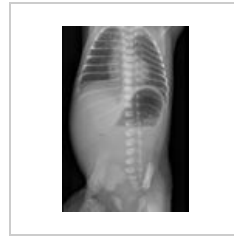Ateroskleróza kor...  
3,264 × 2,448; 3  
MB



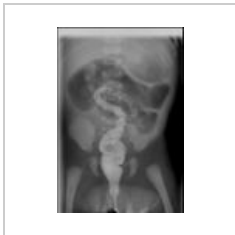Ateroskleróza kor...  
3,264 × 2,448;  
3.13 MB



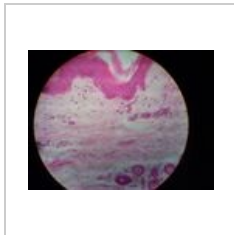
Atrezie duodena ...  
360 × 455; 18 KB



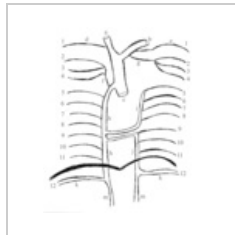
Atrezie duodena ...  
482 × 706; 36 KB



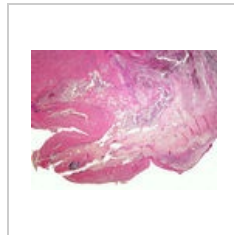
Atrezie jejuna IV...  
338 × 491; 15 KB



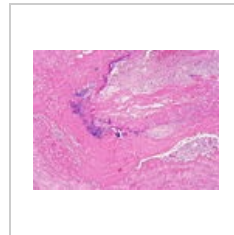
Axilla 5.jpg  
640 × 480; 79 KB



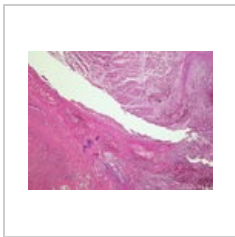
Azyg final.png  
518 × 595; 52 KB



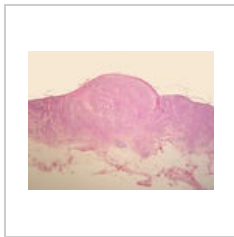Bakteriální endok...  
3,264 × 2,448;  
3.48 MB



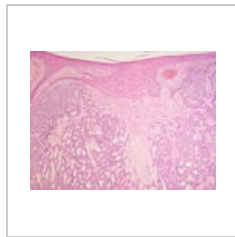
Bakteriální endok...  
3,264 × 2,448;  
4.54 MB



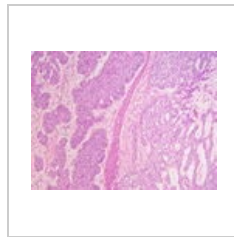
Bakteriální endok...  
3,264 × 2,448;  
4.57 MB



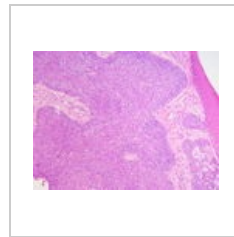
Bazaliom (81A).jpg  
3,264 × 2,448;  
1.75 MB



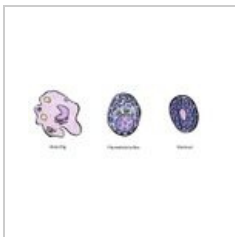Bazaliom (81B).jpg  
3,264 × 2,448;  
1.51 MB



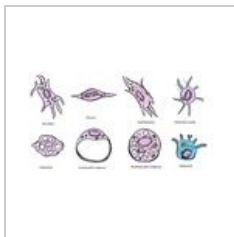
Bazaliom (81C).jpg  
3,264 × 2,448;  
1.38 MB



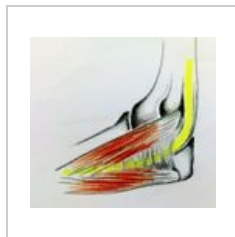
Bazaliom (81D).jpg  
3,264 × 2,448; 1.4  
MB



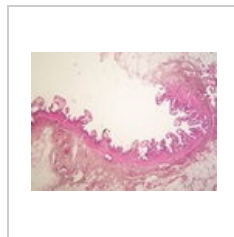
Bloudivé buňky.jpg  
1,187 × 474; 124  
KB



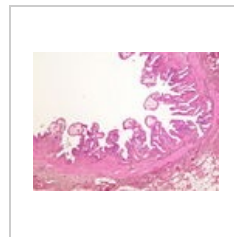
Buňky fixní.jpg  
1,673 × 930; 309  
KB



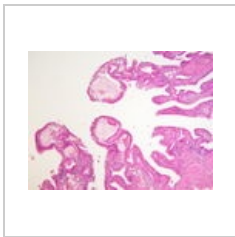
Canaliscubitalis.jpg  
1,019 × 944; 464  
KB



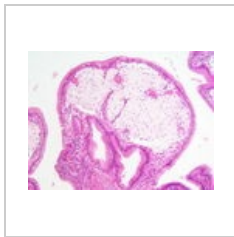
Cholesterolosis v...  
3,264 × 2,448;  
1.39 MB



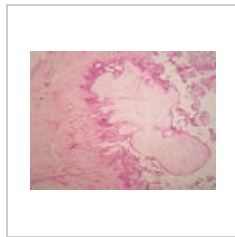
Cholesterolosis v...  
3,264 × 2,448;  
1.38 MB



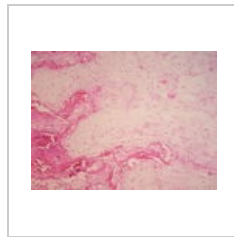
Cholesterolosis v...  
3,264 × 2,448;  
1.56 MB



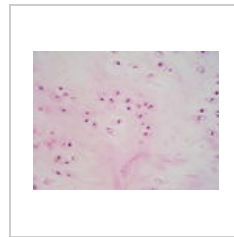
Cholesterolosis v...  
3,264 × 2,448;  
1.44 MB



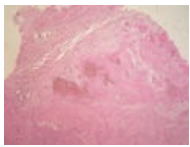
Chondrom (22A)....  
3,264 × 2,448;  
1.43 MB



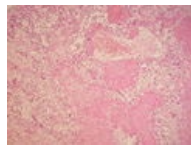
Chondrom (22B)....  
3,264 × 2,448;  
1.75 MB



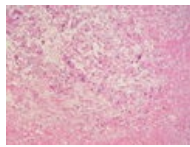
Chondrom (22C)....  
3,264 × 2,448;  
1.76 MB



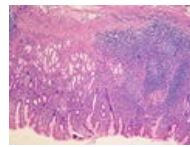
Choriokarcinom (...  
3,264 × 2,448;  
1.45 MB



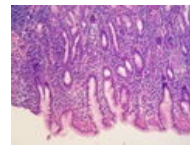
Choriokarcinom (...  
3,264 × 2,448;  
1.57 MB



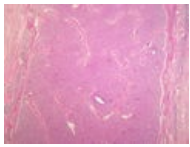
Choriokarcinom (...  
3,264 × 2,448;  
1.36 MB



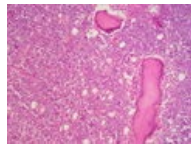
Chronická gastrit...  
3,264 × 2,448; 4.1  
MB



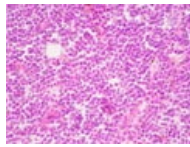
Chronická gastrit...  
3,264 × 2,448;  
3.61 MB



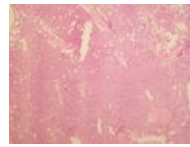
Chronická lymfad...  
3,264 × 2,448;  
4.13 MB



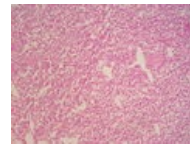
Chronická lymfad...  
3,264 × 2,448;  
1.61 MB



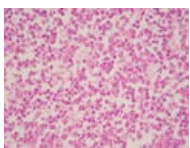
Chronická lymfad...  
3,264 × 2,448;  
1.56 MB



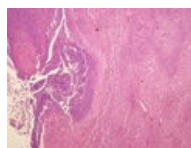
Chronická myeló...  
3,264 × 2,448; 1.7  
MB



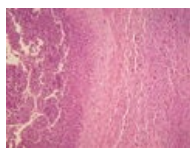
Chronická myeló...  
3,264 × 2,448;  
1.36 MB



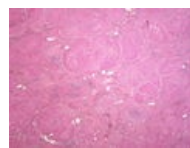
Chronická myeló...  
3,264 × 2,448;  
1.59 MB



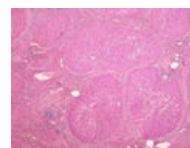
Chronický absces...  
3,264 × 2,448;  
1.34 MB



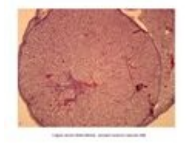
Chronický absces...  
3,264 × 2,448;  
1.29 MB



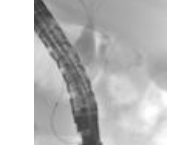
Cirhóza (41A).jpg  
3,264 × 2,448; 1.3  
MB



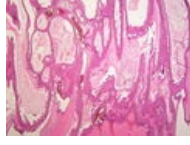Cirhóza (41B).jpg  
3,264 × 2,448;  
1.34 MB



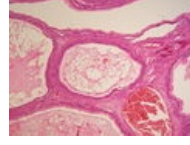Corpus luteum.jpg  
3,046 × 2,454;  
1.08 MB



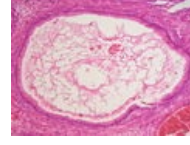
Cysta choledoch...  
547 × 763; 53 KB



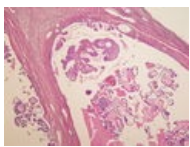
Cystadenoma m...  
3,264 × 2,448;  
1.71 MB



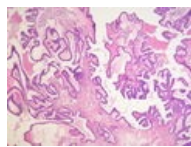
Cystadenoma m...  
3,264 × 2,448;  
1.54 MB



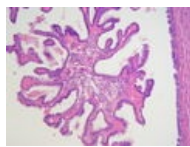
Cystadenoma m...  
3,264 × 2,448;  
1.62 MB



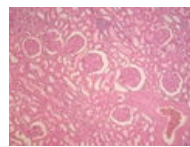
Cystadenoma ser...  
3,264 × 2,448;  
1.51 MB



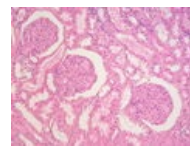
Cystadenoma ser...  
3,264 × 2,448;  
1.51 MB




Cystadenoma ser...  
3,264 × 2,448;  
1.78 MB



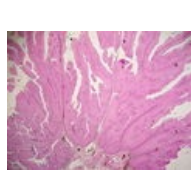
Diabetická glome...  
3,264 × 2,448;  
1.35 MB



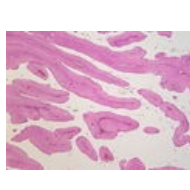
Diabetická glome...  
3,264 × 2,448;  
1.47 MB



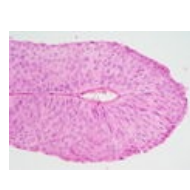Disociační křivka ...  
756 × 777; 54 KB



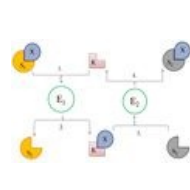
Dobře diferencov...  
3,264 × 2,448;  
1.73 MB



Dobře diferencov...  
3,264 × 2,448;  
1.36 MB

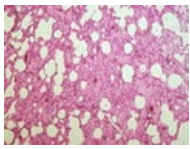


Dobře diferencov...  
3,264 × 2,448;  
1.67 MB

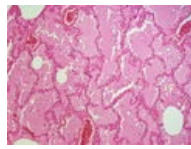


DSC 1639.JPG  
786 × 522; 43 KB






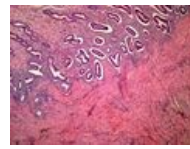
Edém plic (10A).j...  
3,264 × 2,448;  
3.69 MB



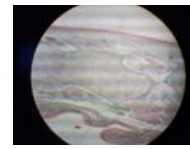
Edém plic (10B).j...  
3,264 × 2,448;  
3.28 MB



Enchondrální osif...  
1,037 × 778; 260  
KB



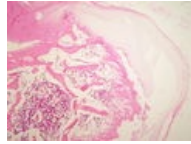
Endometrium a ...  
2,592 × 1,944;  
1.51 MB



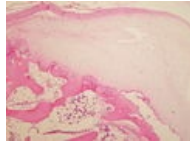
Epiglottis1 - rozdi...  
640 × 480; 88 KB



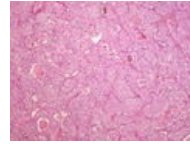
Epitel dýchacích ...  
2,116 × 1,413;  
1.23 MB



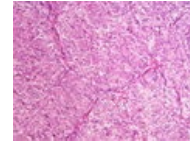
Exostosis cartilag...  
3,264 × 2,448;  
3.29 MB



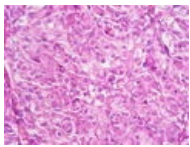
Exostosis cartilag...  
3,264 × 2,448;  
3.08 MB



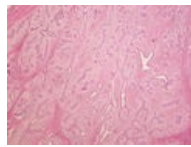
Feochromocytom...  
3,264 × 2,448;  
1.32 MB



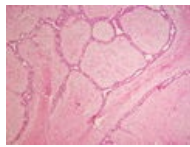
Feochromocytom...  
3,264 × 2,448;  
3.41 MB



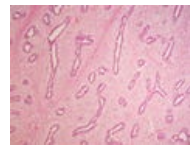Feochromocytom...  
3,264 × 2,448; 1.4  
MB



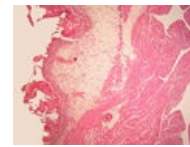
Fibroadenom ma...  
3,264 × 2,448;  
1.68 MB



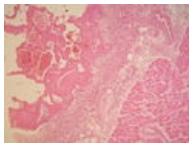
Fibroadenom ma...  
3,264 × 2,448;  
1.36 MB



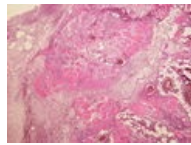
Fibroadenom ma...  
3,264 × 2,448;  
1.54 MB



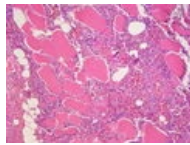
Fibrózní perikardi...  
3,264 × 2,448;  
2.53 MB



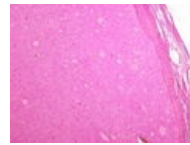
Fibrózní perikardi...  
3,264 × 2,448;  
1.42 MB



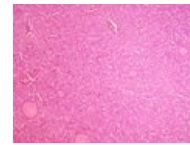
Flegmóna koster...  
3,264 × 2,448;  
4.52 MB



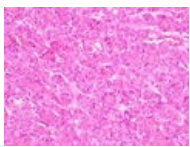
Flegmóna koster...  
3,264 × 2,448;  
1.34 MB



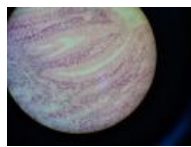
Folikulární karcin...  
3,264 × 2,448;  
3.45 MB



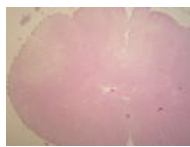
Folikulární karcin...  
3,264 × 2,448;  
4.51 MB



Folikulární karcin...  
3,264 × 2,448;  
3.56 MB



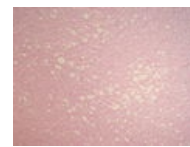
Fundus žaludku4...  
640 × 480; 94 KB



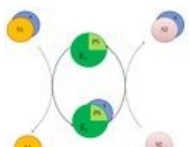
Funikulární myel...  
3,264 × 2,448;  
1.37 MB



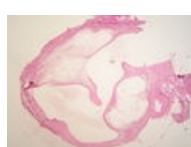
Funikulární myel...  
3,264 × 2,448;  
1.63 MB



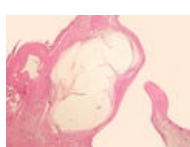Funikulární myel...  
3,264 × 2,448;  
1.44 MB



Funkce prostetic...  
790 × 667; 52 KB



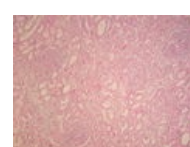
Ganglion (74A).jpg  
3,264 × 2,448;  
1.84 MB



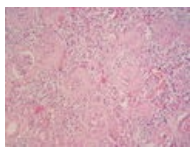
Ganglion (74B).jpg  
3,264 × 2,448;  
1.41 MB



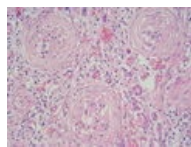
Glandula subling...  
640 × 480; 115 KB



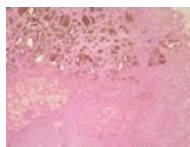
Glomerulonefritis...  
3,264 × 2,448;  
1.56 MB



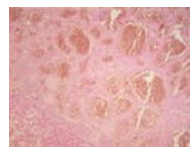
Glomerulonefritis...  
3,264 × 2,448;  
1.44 MB



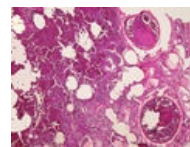
Glomerulonefritis...  
3,264 × 2,448;  
1.56 MB



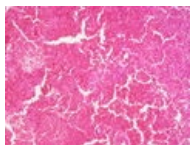
Hemangiom jater...  
3,264 × 2,448;  
1.62 MB



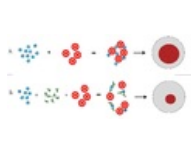
Hemangiom jater...  
3,264 × 2,448;  
1.31 MB



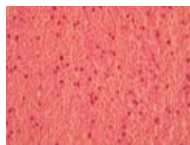
Hemoragický infa...  
3,264 × 2,448;  
3.55 MB




Hemoragický infa...  
3,264 × 2,448;  
4.57 MB



HIT.png  
4,500 × 2,069; 915  
KB



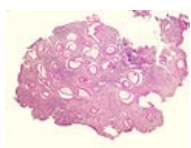
Hladký sval 3.jpg  
1,037 × 778; 213  
KB



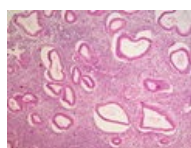
Hladký sval 4.jpg  
1,037 × 778; 120  
KB



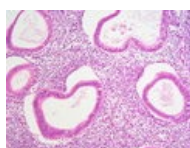
Hladký sval.jpg  
1,037 × 778; 149  
KB



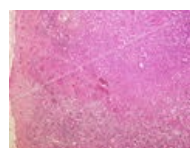Hyperplastické e...  
3,264 × 2,448;  
2.22 MB



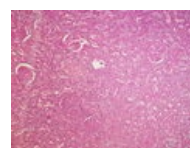
Hyperplastické e...  
3,264 × 2,448;  
1.75 MB



Hyperplastické e...  
3,264 × 2,448;  
1.39 MB



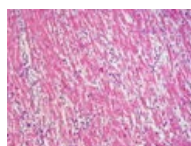
Infarkt ledviny (2...  
3,264 × 2,448;  
5.08 MB



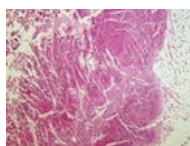
Infarkt ledviny (2...  
3,264 × 2,448;  
4.43 MB



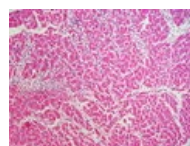
Infarkt myokardu...  
3,264 × 2,448;  
4.56 MB



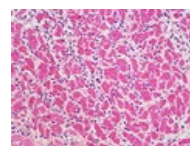
Infarkt myokardu...  
3,264 × 2,448; 3.6  
MB



Infarkt myokardu...  
3,264 × 2,448;  
4.43 MB



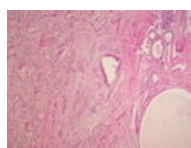
Infarkt myokardu...  
3,264 × 2,448;  
3.62 MB



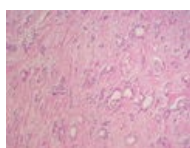
Infarkt myokardu...  
3,264 × 2,448;  
3.41 MB



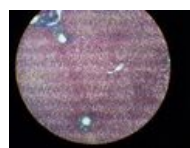
Infiltrující karcino...  
3,264 × 2,448;  
3.71 MB



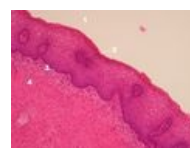
Infiltrující karcino...  
3,264 × 2,448;  
3.54 MB



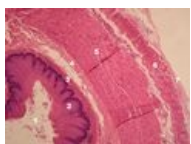
Infiltrující karcino...  
3,264 × 2,448;  
3.91 MB



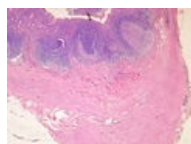
Játra (HE) 3.jpg  
640 × 480; 151 KB



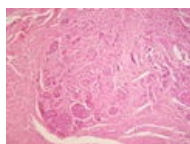
Jícen 14 upr.jpg  
2,592 × 1,944;  
1.43 MB



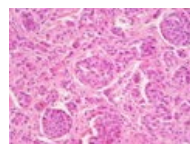
Jícen3 upr.jpg  
2,592 × 1,944;  
1.71 MB



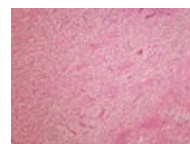Karcinoid append...  
3,264 × 2,448;  
1.35 MB



Karcinoid append...  
3,264 × 2,448;  
1.36 MB

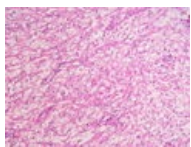


Karcinoid append...  
3,264 × 2,448;  
1.42 MB

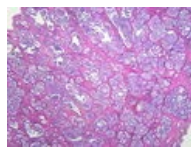


Karcinom ledviny...  
3,264 × 2,448;  
1.36 MB

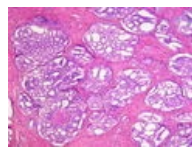




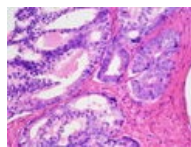
Karcinom ledviny...  
3,264 × 2,448; 1.4 MB



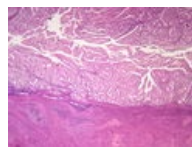
Karcinom prostat...  
3,264 × 2,448; 1.37 MB



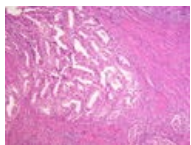
Karcinom prostat...  
3,264 × 2,448; 1.76 MB



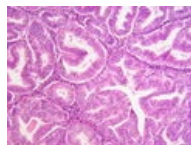
Karcinom prostat...  
3,264 × 2,448; 1.53 MB



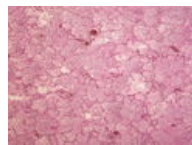
Karcinom těla děl...  
3,264 × 2,448; 1.64 MB



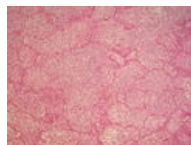
Karcinom těla děl...  
3,264 × 2,448; 1.67 MB



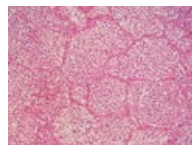
Karcinom těla děl...  
3,264 × 2,448; 1.62 MB



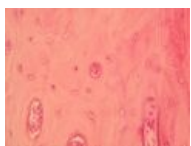
Katarální bronch...  
3,264 × 2,448; 1.31 MB



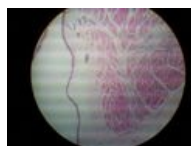
Katarální bronch...  
3,264 × 2,448; 1.85 MB



Katarální bronch...  
3,264 × 2,448; 1.64 MB



Lamelosní kost 4...  
1,037 × 778; 160 KB



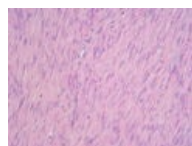
Larynx3.jpg  
640 × 480; 88 KB



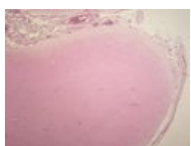
Leiomyoma uteri ...  
3,264 × 2,448; 1.39 MB



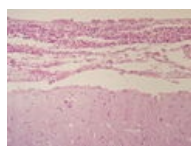
Leiomyoma uteri ...  
3,264 × 2,448; 1.48 MB



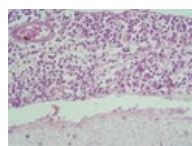
Leiomyoma uteri ...  
3,264 × 2,448; 1.56 MB



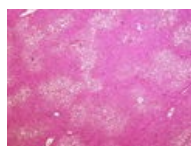
Leptomeningitis ...  
3,264 × 2,448; 1.59 MB



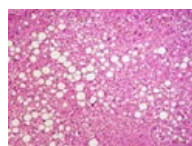
Leptomeningitis ...  
3,264 × 2,448; 1.47 MB



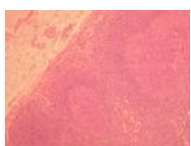Leptomeningitis ...  
3,264 × 2,448; 1.6 MB



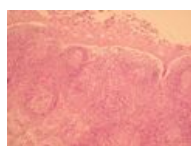Ložisková velkok...  
3,264 × 2,448; 4.71 MB



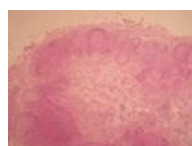Ložisková velkok...  
3,264 × 2,448; 3.62 MB



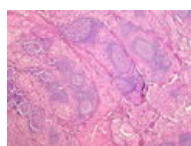
Lymf uzlina 1.jpg  
1,296 × 972; 445 KB



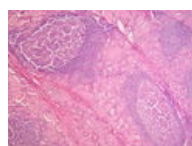
Lymf uzlina 3.jpg  
1,296 × 972; 473 KB



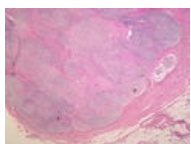
Lymf uzlina 4.jpg  
1,296 × 972; 371 KB



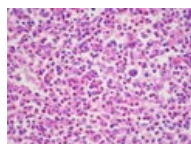
Lymfoplasmocyt...  
3,264 × 2,448; 3.92 MB



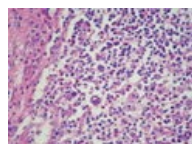
Lymfoplasmocyt...  
3,264 × 2,448; 4.29 MB



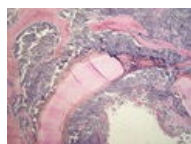
Maligní lymfogra...  
3,264 × 2,448; 1.29 MB



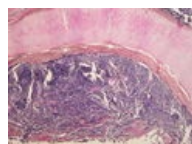
Maligní lymfogra...  
3,264 × 2,448; 1.67 MB



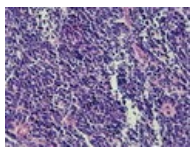
Maligní lymfogra...  
3,264 × 2,448; 1.59 MB



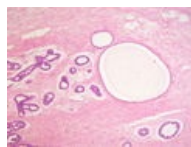
Malobuněčný kar...  
3,264 × 2,448; 1.91 MB



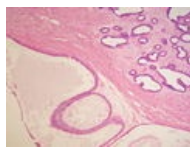Malobuněčný kar...  
3,264 × 2,448; 1.31 MB



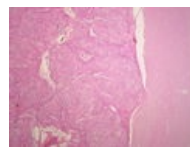
Malobuněčný kar...  
3,264 × 2,448;  
1.34 MB



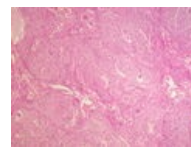
Mastopathia fibro...  
3,264 × 2,448; 1.5  
MB



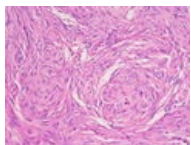
Mastopathia fibro...  
3,264 × 2,448;  
1.54 MB



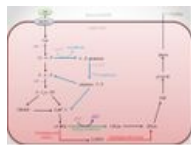
Meningeom (69A...  
3,264 × 2,448;  
1.54 MB



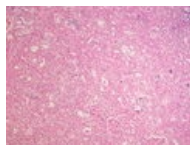
Meningeom (69B...  
3,264 × 2,448;  
1.65 MB



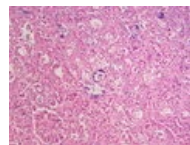
Meningeom (69C...  
3,264 × 2,448;  
1.39 MB



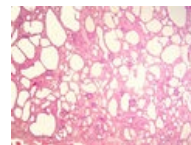
Metabolismus er...  
1,068 × 803; 110  
KB



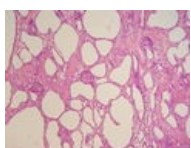
Metastatické zvá...  
3,264 × 2,448;  
1.37 MB



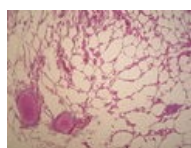
Metastatické zvá...  
3,264 × 2,448;  
1.54 MB



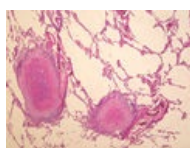
Mikrocystóza led...  
3,264 × 2,448;  
2.34 MB



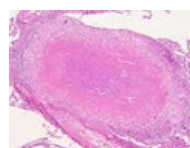
Mikrocystóza led...  
3,264 × 2,448;  
3.05 MB



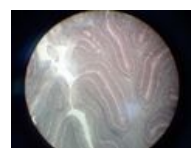Miliární TBC plic (...  
3,264 × 2,448; 1.5  
MB



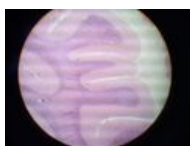
Miliární TBC plic (...  
3,264 × 2,448;  
1.93 MB



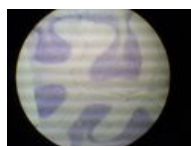Miliární TBC plic (...  
3,264 × 2,448;  
1.74 MB



Mozecek - impre...  
640 × 480; 94 KB



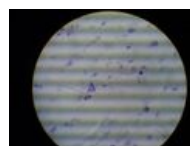
Mozecek HE 1.jpg  
640 × 480; 82 KB



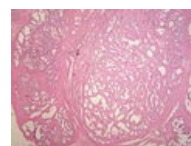
Mozecek HE 3.jpg  
640 × 480; 82 KB



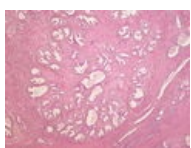
Mozek Nissl 2.jpg  
640 × 480; 61 KB



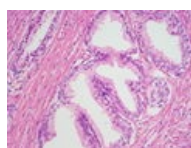
Mozek Nissl 3.jpg  
640 × 480; 58 KB



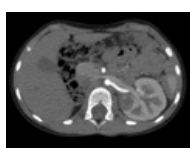
Myoadenomová ...  
3,264 × 2,448;  
1.66 MB



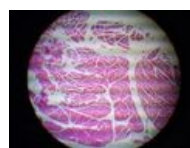Myoadenomová ...  
3,264 × 2,448; 1.3  
MB



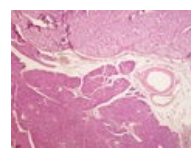
Myoadenomová ...  
3,264 × 2,448;  
1.53 MB



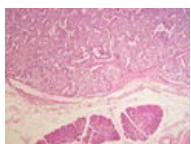
Nefroblastom soli...  
715 × 531; 280 KB



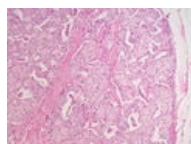
Nervo - svalove v...  
640 × 480; 55 KB



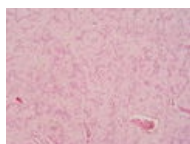
Nesidiom (79A).jpg  
3,264 × 2,448;  
4.35 MB



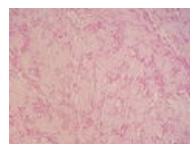
Nesidiom (79B).jpg  
3,264 × 2,448; 4  
MB



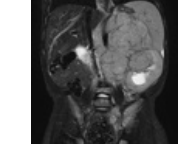
Nesidiom (79C).jpg  
3,264 × 2,448;  
1.46 MB



Neurilemom (25A...  
3,264 × 2,448;  
1.38 MB



Neurilemom (25B...  
3,264 × 2,448;  
1.51 MB



Neuroblastom 1....  
635 × 798; 498 KB