

Kategorie:PD soubory

Pages in category "PD soubory"

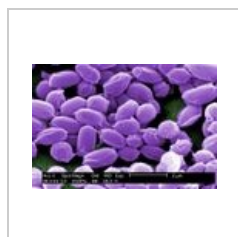This category contains only the following page.

P

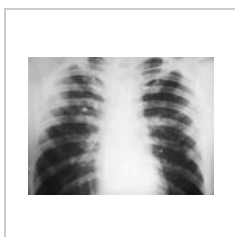- Uživatel:Pája1137/Pískoviště

Media in category "PD soubory"

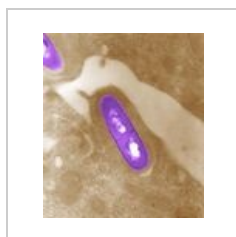
The following 107 files are in this category, out of 107 total.



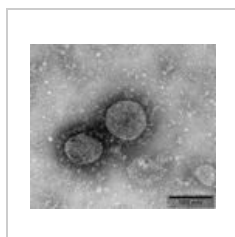
10123 lores.jpg
700 × 475; 60 KB



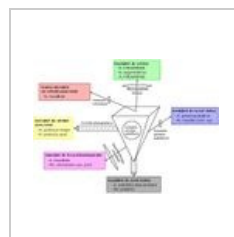
10187 lores.jpg
700 × 520; 29 KB



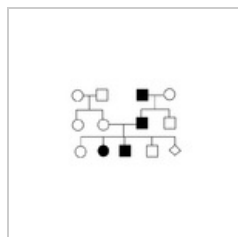
10828 lores.jpg
700 × 809; 99 KB



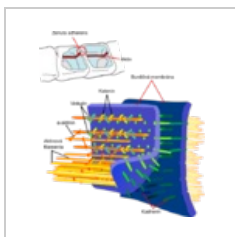
2019-nCoV kmen...
778 × 694; 193 KB



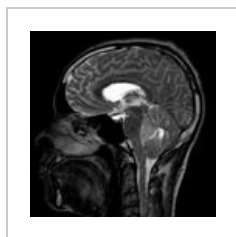800px-Fossapter...
800 × 582; 61 KB



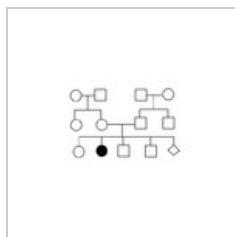
AD.png
640 × 400; 8 KB



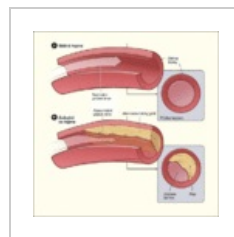Adherens Junctio...
490 × 548; 117 KB



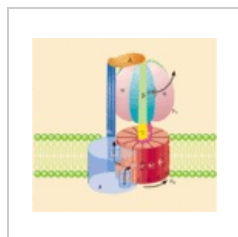
Anaplas mri.jpg
630 × 630; 92 KB



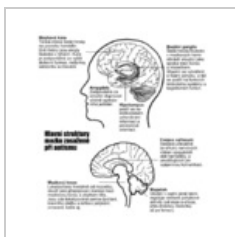
AR.png
640 × 400; 8 KB



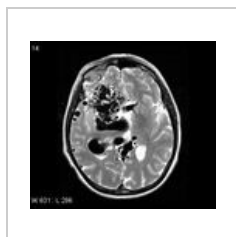Atherosclerosis d...
450 × 451; 39 KB



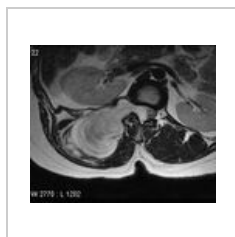ATP synthase.gif
600 × 567; 46 KB



Autismbrain cs.png
500 × 540; 171 KB



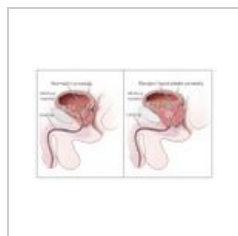
AVM cerebral.jpg
630 × 570; 60 KB



Axial schwannom...
630 × 533; 58 KB



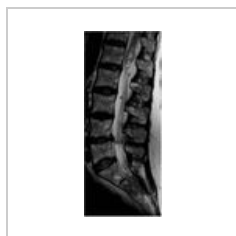Bakterie dle Gra...
2,736 × 1,725; 342 KB



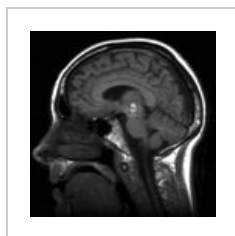Benign Prostatic ...
1,053 × 650; 96 KB



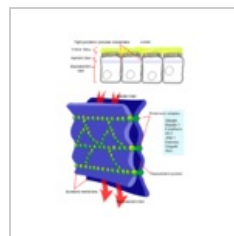
Bronzova.png
249 × 438; 91 KB



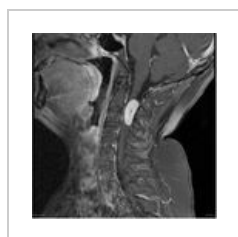Carcinoma breas...
262 × 630; 23 KB



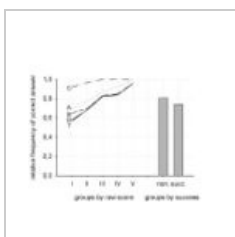
Cavernoma mes...
630 × 630; 44 KB




Cellular tight jun...
499 × 646; 116 KB



Cervical schwann...
630 × 630; 47 KB



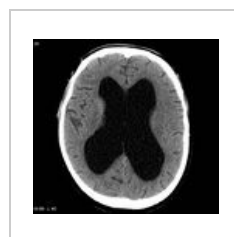CH4 05.JPG
1,060 × 856; 127 KB



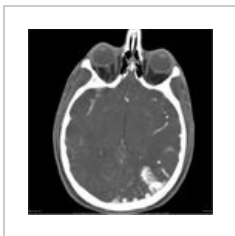CH84 03.JPG
1,062 × 817; 118 KB

Category	Overall	Female	Male	Age	Sex	Year	Location	Time	Frequency	Prevalence	Incidence	Prevalence	Incidence	Prevalence	Incidence
1	0.756	0.456	0.051	0.281	0.27	0.172	1.407								

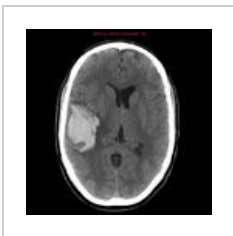
CH84.jpg
368 × 139; 17 KB



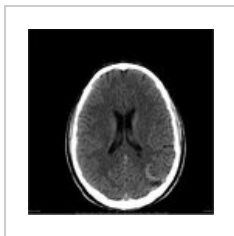
CT - obstrukční h...
442 × 418; 34 KB



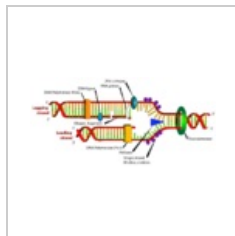
CT brainAVM con...
630 × 630; 32 KB



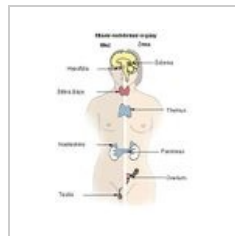
CT brainAVM non...
630 × 630; 36 KB



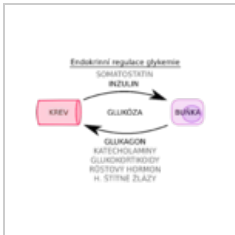CT brainAVM non...
630 × 630; 42 KB



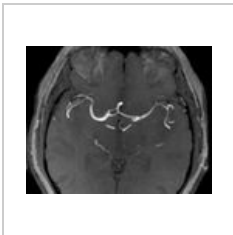
DNA replication e...
691 × 336; 83 KB



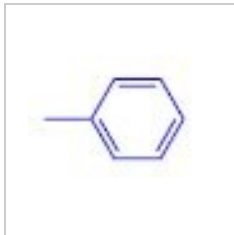
Endokrinnniorgan...
317 × 421; 23 KB



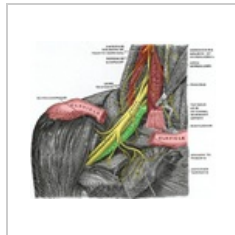
Endokrinní regul...
1,256 × 894; 102 KB



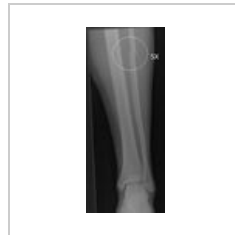Fenestrated ACA...
630 × 506; 25 KB



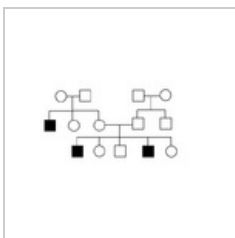
Fenyl.jpg
73 × 52; 3 KB



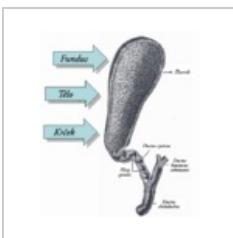
Fissura scalenoru...
575 × 488; 489 KB



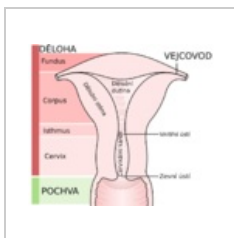
Fracturafibulae.JPG
304 × 712; 12 KB




GR.png
640 × 400; 6 KB




Gray1095 cs.png
478 × 555; 62 KB



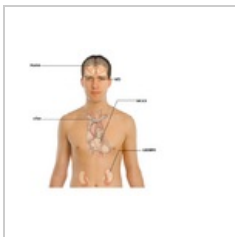
Gray1167 cz.svg
824 × 721; 70 KB



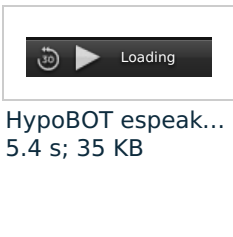
Gray754 cs.png
700 × 680; 257 KB



Hanahor.jpg
1,512 × 1,540; 474 KB



Hypertenzní krize...
640 × 512; 216 KB



HypoBOT espeak...
5.4 s; 35 KB

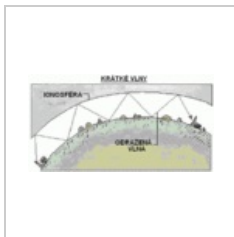
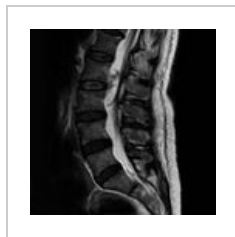


Image003.gif
589 × 310; 35 KB



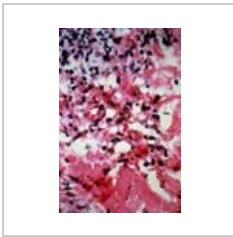
Intradural schwa...
630 × 630; 34 KB



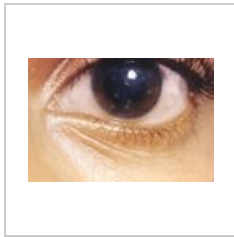
Jak to tedy je.png
640 × 547; 100 KB



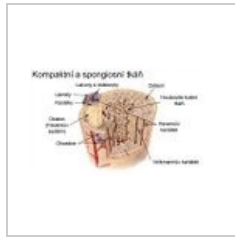
Jak začít ikona.png
211 × 235; 1 KB



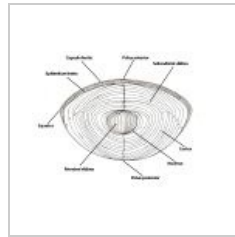
Kaposi.jpg
700 × 1,063; 115 KB



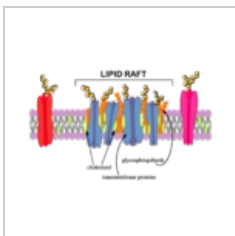
Keratitis.jpg
700 × 465; 36 KB




Lamelosní kost (s...
520 × 300; 83 KB




LensII.jpg
960 × 720; 91 KB




Lipid Raft-.png
300 × 183; 50 KB



LogoBC.png
361 × 301; 12 KB



Lukas Editor.jpg
1,296 × 1,728; 165 KB




Mainpage grad25...
40 × 40; 345 bytes



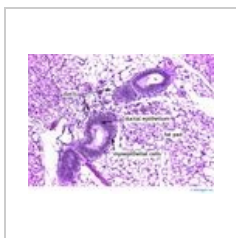Mainpage grad50...
40 × 40; 345 bytes



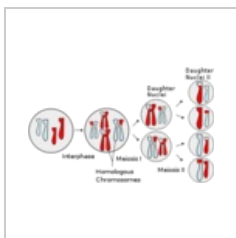
Mainpage grad75...
40 × 40; 345 bytes



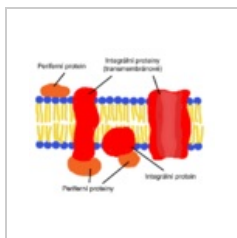
Mainpage gradie...
1,680 × 320; 11 KB



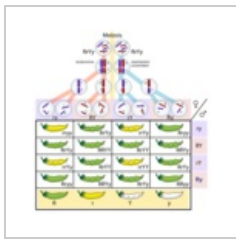
Mammary glands...
800 × 598; 117 KB



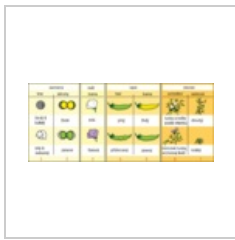
Meioza.png
300 × 188; 31 KB



Membrane protei...
438 × 362; 22 KB



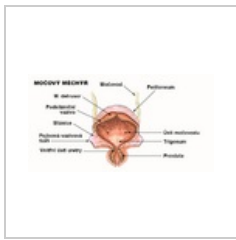
Mendel nezavisla...
579 × 599; 153 KB



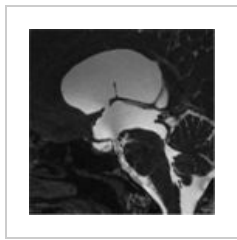
Mendel sedm zna...
592 × 254; 53 KB



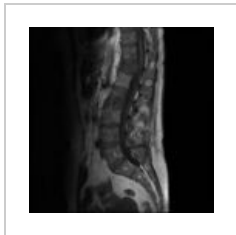Migrena.jpg
585 × 464; 133 KB



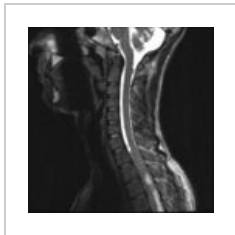
Močový měchýř (...
1,040 × 546; 200 KB



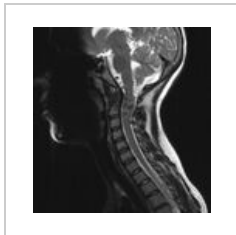MRI T2 - postope...
630 × 630; 34 KB



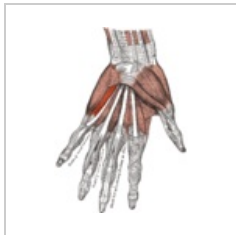MRI - metastáza ...
630 × 630; 106 KB



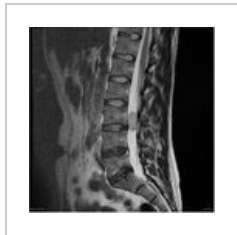
MRI - spinální ast...
630 × 630; 69 KB



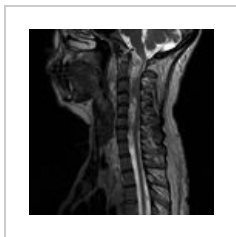MRIT2 AVM.jpg
606 × 630; 107 KB



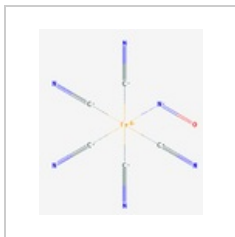
Musculus flexor d...
636 × 882; 295 KB



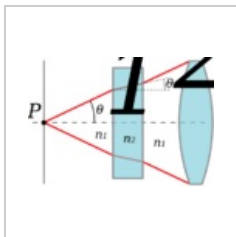
Myxo spinal.jpg
630 × 630; 61 KB



Nf-1 multiple neu...
630 × 630; 43 KB



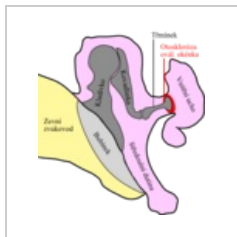Nitroprusid.png
338 × 382; 8 KB



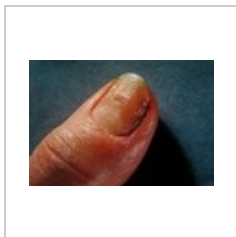
Numerical apertu...
436 × 307; 12 KB



Nursing educatio...
645 × 380; 27 KB



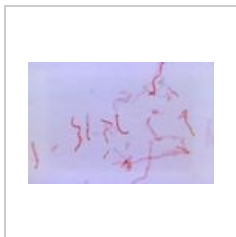Otosklerose.png
314 × 348; 36 KB



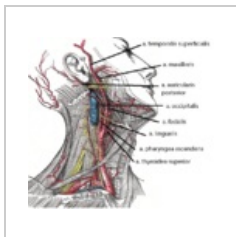
PHIL 2923 lores.jpg
700 × 475; 35 KB



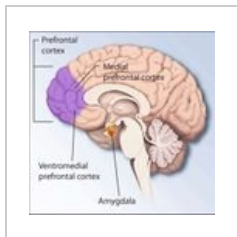
Pozor.png
1,351 × 1,184; 54 KB



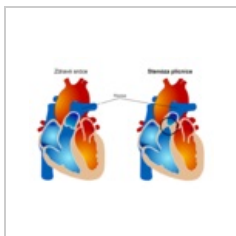
Prevotella melani...
700 × 460; 32 KB



Prime vetve ACE...
700 × 647; 478 KB



PTSD stress brain...
368 × 365; 48 KB



Pulmonary valve ...
616 × 440; 76 KB




Recept hlavička.j...
567 × 824; 82 KB



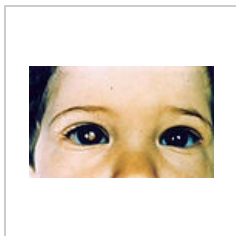
Recept ořez.jpg
553 × 277; 55 KB




Recept.jpg
557 × 795; 89 KB




Registrovat ikona...
50 × 50; 7 KB



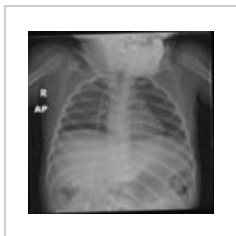Retinoblastoma.jpg
512 × 308; 38 KB



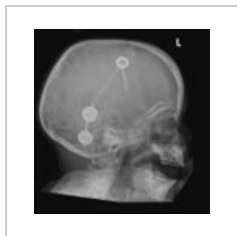RIA kalibracni kri...
383 × 249; 20 KB



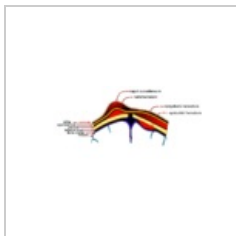
RTG záření v me...
0 × 0; 578 KB



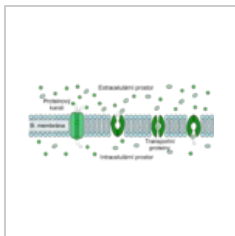
RtgVPshunt.jpg
630 × 623; 58 KB



RtgVPshunt1.jpg
600 × 630; 50 KB



Scalp hematoma...
1,059 × 414; 137 KB



Scheme facilitate...
581 × 254; 84 KB

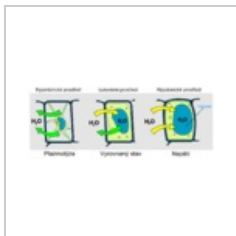
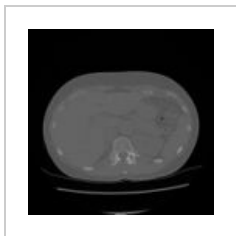


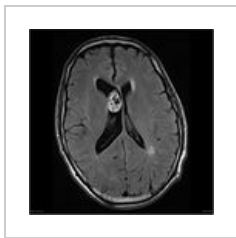
Schéma změn v r...
2,047 × 810; 251 KB




Spinal osteoid os...
630 × 630; 54 KB



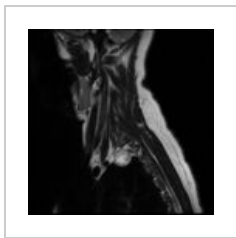
Striebro.png
249 × 436; 63 KB



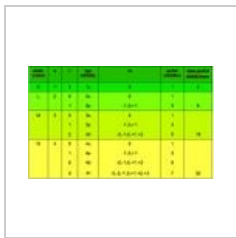Subependymom ...
442 × 442; 24 KB



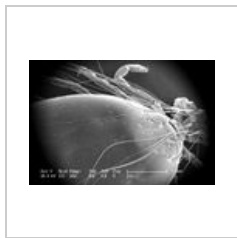Symboly1.gif
311 × 302; 4 KB



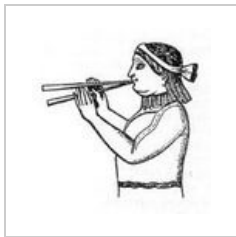T2sag intercostal...
630 × 630; 129 KB



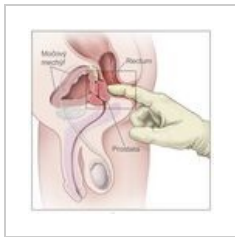
Tabulka kv. cisla...
606 × 371; 49 KB



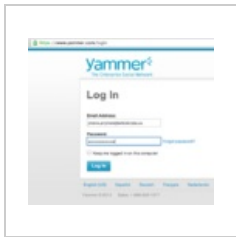Tick.jpg
700 × 475; 46 KB



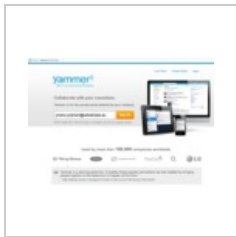Tinnitus.jpg
163 × 168; 6 KB



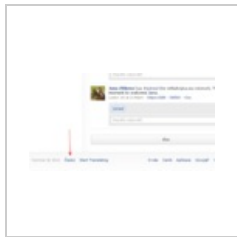Vyšetření per rec...
2,025 × 2,018; 338 KB



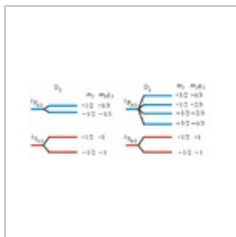
Yammer - log in...
562 × 505; 59 KB



Yammer - sign u...
1,190 × 826; 290 KB



Yammer cestina....
616 × 325; 25 KB



Zeemanův jev.png
504 × 220; 60 KB



Zlata.png
252 × 442; 89 KB