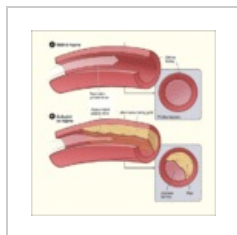


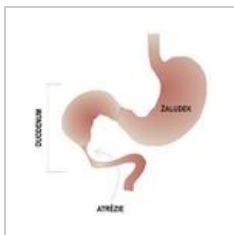
Kategorie:Patologická schémata

Media in category "Patologická schémata"

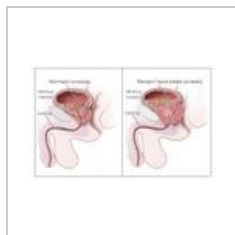
The following 44 files are in this category, out of 44 total.



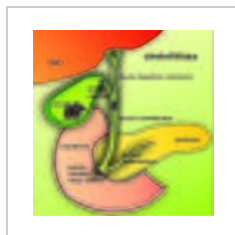
Atherosclerosis d...
450 × 451; 39 KB



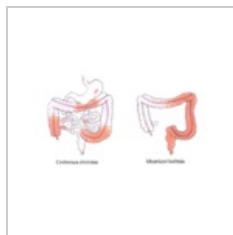Atrezie duodena...
350 × 363; 34 KB



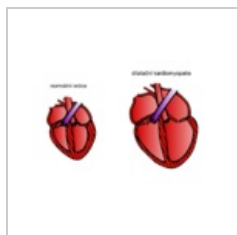
Benign Prostatic ...
1,053 × 650; 96 KB



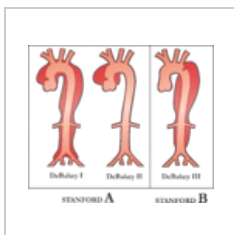
Cholelitiáza.jpg
2,826 × 2,889;
2.96 MB



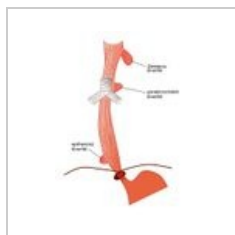
Crohnova chorob...
667 × 409; 148 KB



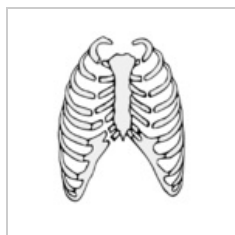
Dilatační kardio...
905 × 615; 180 KB



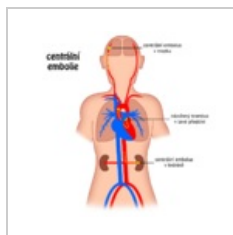
Disekce klasifika...
3,795 × 3,234; 940 KB



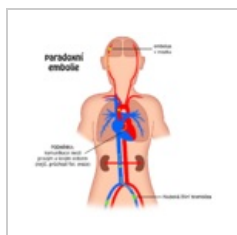
Divertikly jícnu.jpg
465 × 623; 38 KB



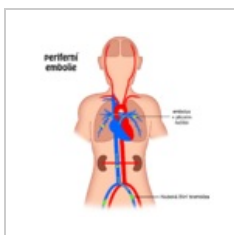
Dvířková zlomeni...
379 × 426; 63 KB



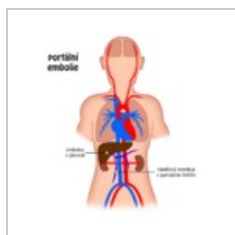
Embolie centrální...
1,024 × 1,024; 80 KB



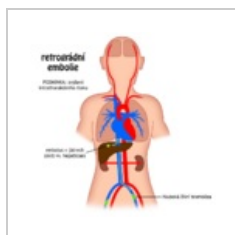
Embolie paradox...
1,024 × 1,024; 85 KB



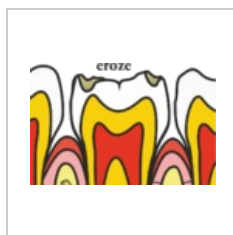
Embolie periferní...
1,024 × 1,024; 77 KB



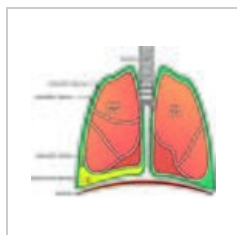
Embolie portální...
1,024 × 1,024; 79 KB



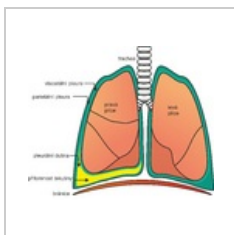
Embolie retrográ...
1,024 × 1,024; 84 KB



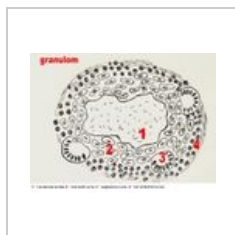Eroze.png
858 × 566; 109 KB



Fluidothorax.jpg
2,674 × 2,198;
3.49 MB



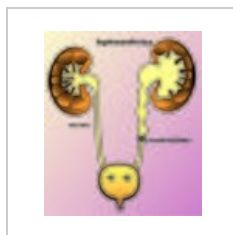
Fluidothorax.png
2,674 × 2,198; 609 KB



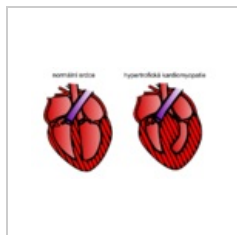
Granulom.jpg
615 × 464; 62 KB



Herniace disku.jpg
300 × 514; 59 KB



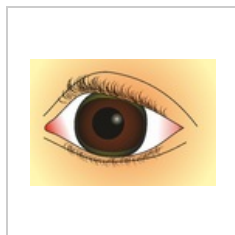
Hydronefróza.jpg
3,980 × 4,674;
3.43 MB



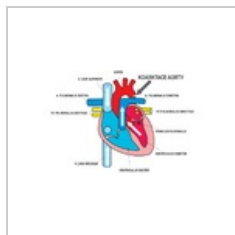
Hypertrofická kar...
759 × 454; 121 KB



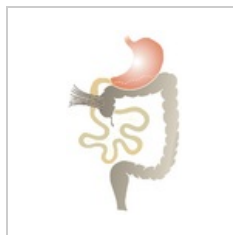
Jícen klasifikace....
1,200 × 400; 51 KB



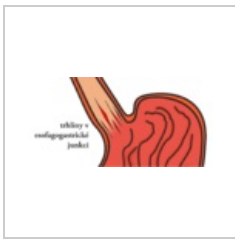
Kayser.Fleischer....
2,344 × 1,611; 911 KB



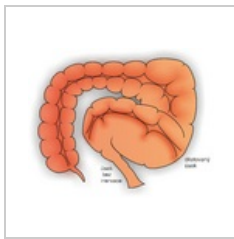
Koarktace aorty...
1,085 × 602; 140 KB



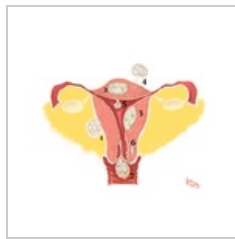Ladduv syndrom...
500 × 794; 215 KB



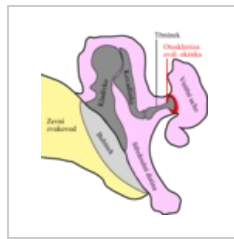Mallory-Weiss sy...
1,143 × 551; 186 KB



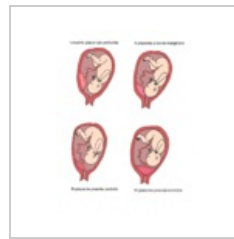
Megacolon.png
3,351 × 2,708; 2.35 MB



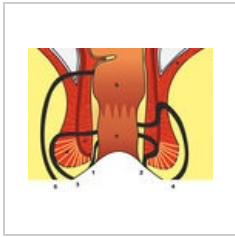
Myoma.png
1,736 × 1,345; 942 KB



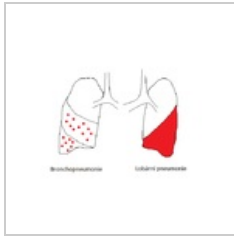
Otosklerose.png
314 × 348; 36 KB



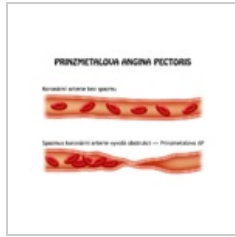
Patologické ulože...
1,040 × 1,368; 614 KB



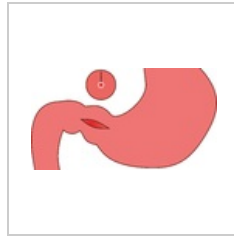
Periprokt.jpg
900 × 698; 150 KB



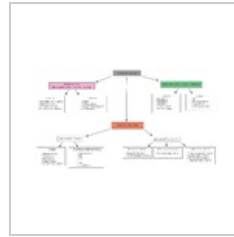
Pneumonie rozlis...
544 × 460; 9 KB




Prinzmetalova AP...
800 × 600; 50 KB



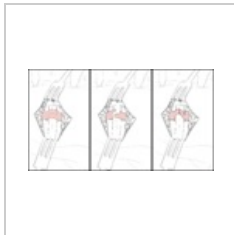Pylorostenóza2.p...
2,700 × 1,479; 130 KB



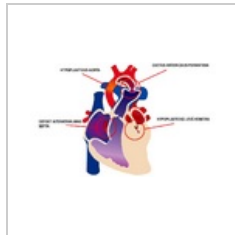
Přehled krvácivý...
4,000 × 2,195; 299 KB



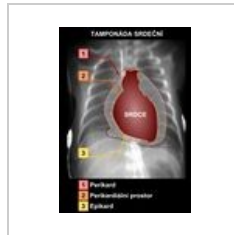
RF aterosklerózy...
800 × 800; 87 KB



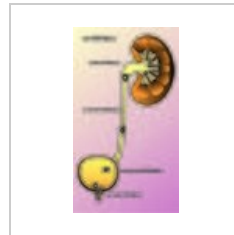
Stenozující tendo...
1,500 × 823; 169 KB



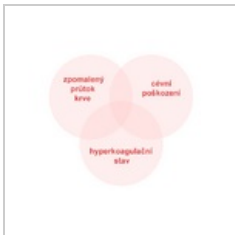
Syndrom hypopl...
967 × 599; 157 KB



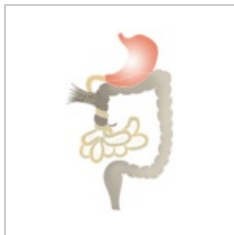Tamponada.jpg
1,240 × 1,754; 183 KB



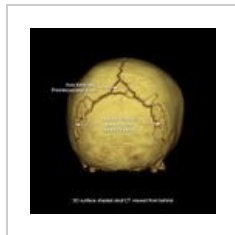
Urolitiáza.jpg
2,732 × 4,834; 3.01 MB



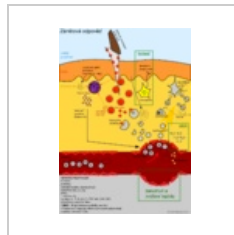
Virchowova triád...
563 × 501; 20 KB



Volvulus.png
500 × 794; 59 KB



WormianBones.jpg
820 × 820; 65 KB



Zánětová odpově...
1,500 × 2,121; 661 KB