

# Kategorie:Patologické preparáty (1. LF UK)

V této kategorii se nachází preparáty převzaté ze sbírky Ústavu patologie 1. LF UK (<http://pau.lf1.cuni.cz/>).

## Pages in category "Patologické preparáty (1. LF UK)"

The following 83 pages are in this category, out of 83 total.

### A

- Adenokarcinom tlustého střeva (preparát)
- Adenom nadledviny (preparát)
- Akutní hemoragická nekróza pankreatu (preparát)
- Aneurysma mozkové arterie (preparát)
- Ateroskleróza koronární arterie (preparát)

### B

- Bakteriální endokarditis (preparát)
- Basaliom (preparát)

### C

- Cholesterolosis vesicae felleae (preparát)
- Chondrom (preparát)
- Choriokarcinom (preparát)
- Chronická gastritis (preparát)
- Chronická lymfadenóza dřeně (preparát)
- Chronická myelóza dřeně (preparát)
- Chronický absces v játrech (preparát)
- Círhóza pseudolobulární (preparát)
- Cystadenoma mucinosum ovarii (preparát)

### D

- Uživatel:Daniels/Pískoviště/Preparáty - patologie
- Diabetická glomeruloskleróza (preparát)
- Dobře diferencovaný uroteliální papilokarcinom (preparát)
- Dyzentérie (preparát)

### E

- Edém plic (preparát)
- Exostosis cartilaginea (preparát)

### F

- Feochromocytom (preparát)
- Fibrinózní perikarditis (preparát)
- Fibroadenom mammy štěrbinovitý (preparát)
- Flegmóna kosterního svalu (preparát)
- Folikulární karcinom štítné žlázy (preparát)
- Funikulární myelopatie (preparát)

### G

- Ganglion (preparát)
- Glomerulonefritis rychle progredující (preparát)

### H

- Hemangiom jater (preparát)
- Hemoragický infarkt plic (preparát)
- Hyperplastické endometrium (preparát)

### I

- Infarkt ledviny (preparát)

- Infarkt myokardu starší (preparát)
- Infarkt myokardu čerstvý (preparát)
- Infiltrující karcinom mammy (preparát)

## K

- Karcinoid appendixu (preparát)
- Karcinom ledviny z jasných buněk (preparát)
- Karcinom prostaty (preparát)
- Karcinom těla děložního (preparát)
- Katarální bronchopneumonie (preparát)

## L

- Uživatel:L.Hoznauerová/Pískoviště/Patologie
- Leiomyoma uteri (preparát)
- Leptomeningitis purulenta (preparát)
- Ložisková velkokapénková steatóza jater (preparát)
- Lymfoplasmocytární thyreoiditis (preparát)

## M

- Maligní lymfogranulom (preparát)
- Malobuněčný karcinom plic (preparát)
- Mastopathia fibrosa et cystica (preparát)
- Meningeom (preparát)
- Metastatické zvěpenění v ledvině (preparát)
- Mikrocystóza ledvin (preparát)
- Miliární tuberkulóza plic (preparát)
- Mola hydatidosa (preparát)
- Myoadenomová hyperplázie prostaty (preparát)

## N

- Nesidiom (preparát)
- Neurilemom (preparát)
- Nodulární melanom (preparát)

## O

- Obrovskobuněčný kostní nádor (preparát)
- Organizovaný trombus s rekanalizací v arterii (preparát)
- Osteosarkom (preparát)

## P

- Papilokarcinom močového měchýře (preparát)
- Perisplenitis cartilaginea (preparát)
- Pigmentový névus smíšený (preparát)
- Polypózní adenom rekta (preparát)
- Pyelonefritis hnisavá s nekrózami papil (preparát)

## R

- Residua post abortum (preparát)
- Retenční cysty cervikálních žlázek (preparát)
- Revmatoidní artritida (preparát)

## S

- Sarkoidóza uzliny (preparát)
- Sekundární amyloidóza jater (preparát)
- Sekundární amyloidóza ledvin (preparát)
- Sekundární amyloidóza sleziny (preparát)
- Seminom varlete (preparát)
- Septické metastatické abscesy plíce (preparát)
- Serózní bordeline nádor ovária (preparát)
- Spinocelulární karcinom plic (preparát)

## T

- Tabes dorsalis (preparát)
- Tuberkulózní perikarditida (preparát)

## U

- Ulceroflegmonózní appendicitis (preparát)
- Ulcus pepticum chronicum (preparát)

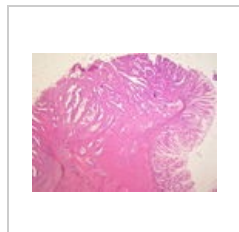
## V

- Verruca vulgaris (preparát)

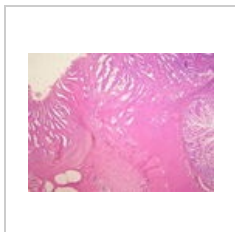
## Media in category "Patologické preparáty (1. LF UK)"

The following 200 files are in this category, out of 215 total.

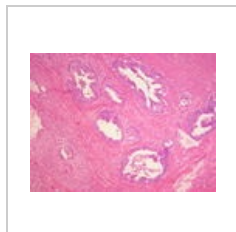
(previous page) (next page)



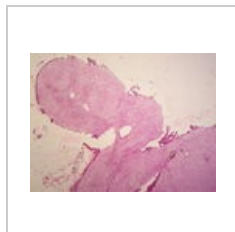
Adenokarcinom t...  
3,264 × 2,448;  
1.63 MB



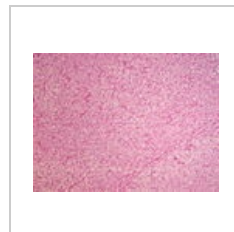Adenokarcinom t...  
3,264 × 2,448;  
1.61 MB



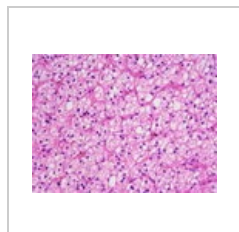
Adenokarcinom t...  
3,264 × 2,448;  
1.36 MB



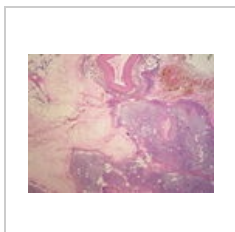Adenom nadledvi...  
3,264 × 2,448;  
1.42 MB



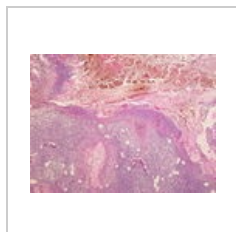
Adenom nadledvi...  
3,264 × 2,448;  
1.31 MB



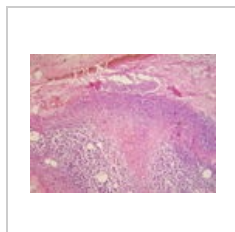
Adenom nadledvi...  
3,264 × 2,448;  
1.39 MB



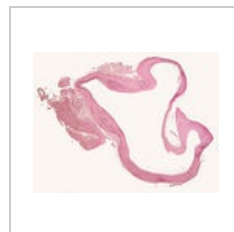
Akutní hemoragi...  
3,264 × 2,448;  
1.77 MB



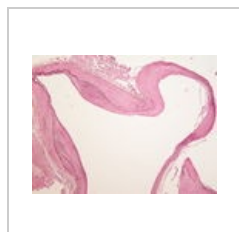
Akutní hemoragi...  
3,264 × 2,448;  
1.34 MB



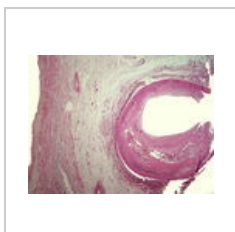
Akutní hemoragi...  
3,264 × 2,448; 1.6  
MB



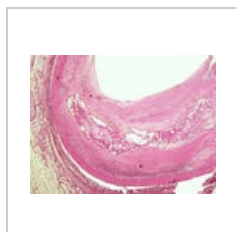
Aneurysma mozkk...  
2,800 × 2,132; 625  
KB



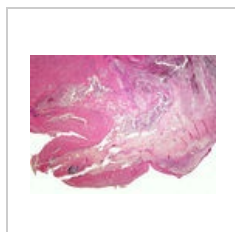
Aneurysma mozkk...  
3,264 × 2,448;  
1.55 MB



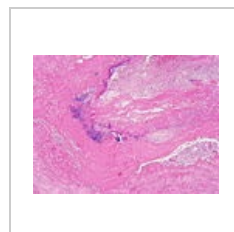
Ateroskleróza kor...  
3,264 × 2,448; 3  
MB



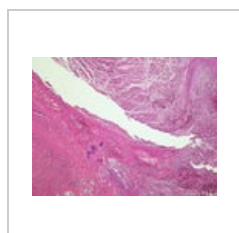
Ateroskleróza kor...  
3,264 × 2,448;  
3.13 MB



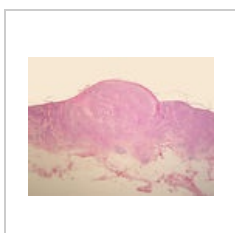Bakteriální endok...  
3,264 × 2,448;  
3.48 MB



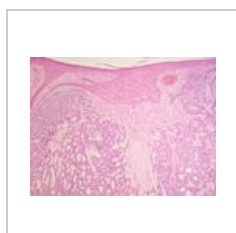
Bakteriální endok...  
3,264 × 2,448;  
4.54 MB



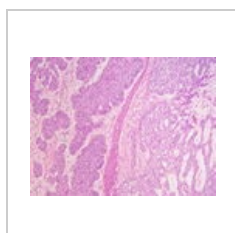
Bakteriální endok...  
3,264 × 2,448;  
4.57 MB



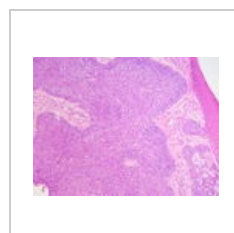Bazaliom (81A).jpg  
3,264 × 2,448;  
1.75 MB



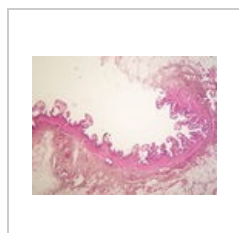
Bazaliom (81B).jpg  
3,264 × 2,448;  
1.51 MB



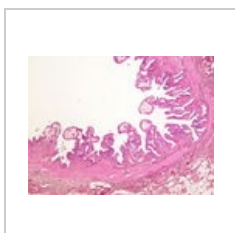
Bazaliom (81C).jpg  
3,264 × 2,448;  
1.38 MB



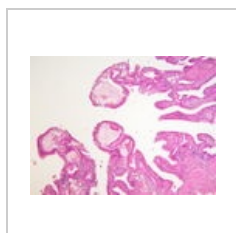
Bazaliom (81D).jpg  
3,264 × 2,448; 1.4  
MB



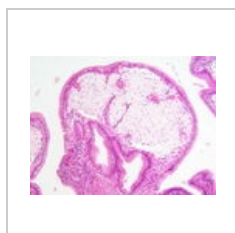
Cholesterolosis v...  
3,264 × 2,448;  
1.39 MB



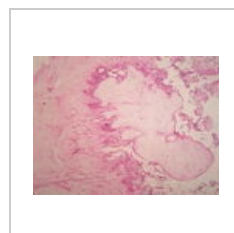
Cholesterolosis v...  
3,264 × 2,448;  
1.38 MB



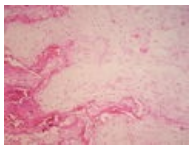
Cholesterolosis v...  
3,264 × 2,448;  
1.56 MB



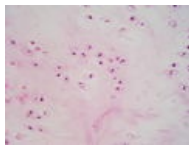
Cholesterolosis v...  
3,264 × 2,448;  
1.44 MB



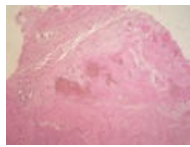
Chondrom (22A)....  
3,264 × 2,448;  
1.43 MB



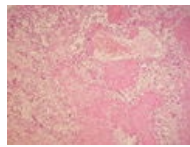
Chondrom (22B)....  
3,264 × 2,448;  
1.75 MB



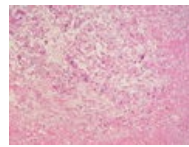
Chondrom (22C)....  
3,264 × 2,448;  
1.76 MB



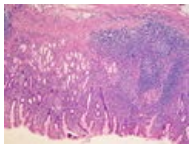
Choriokarcinom (...  
3,264 × 2,448;  
1.45 MB



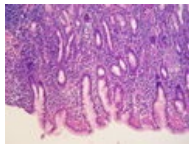
Choriokarcinom (...  
3,264 × 2,448;  
1.57 MB



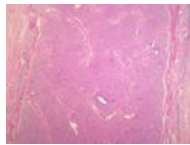
Choriokarcinom (...  
3,264 × 2,448;  
1.36 MB



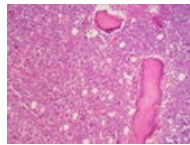
Chronická gastrit...  
3,264 × 2,448; 4.1  
MB



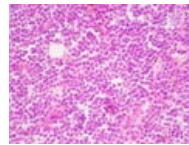
Chronická gastrit...  
3,264 × 2,448;  
3.61 MB



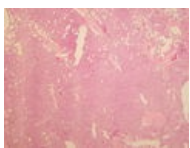
Chronická lymfaden...  
3,264 × 2,448;  
4.13 MB



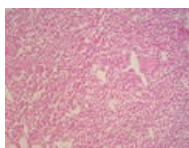
Chronická lymfaden...  
3,264 × 2,448;  
1.61 MB



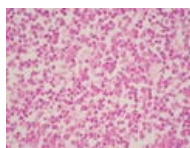
Chronická lymfaden...  
3,264 × 2,448;  
1.56 MB



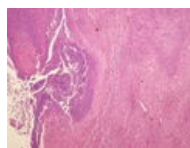
Chronická myeloidní...  
3,264 × 2,448; 1.7  
MB



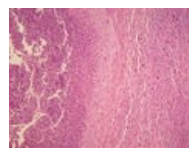
Chronická myeloidní...  
3,264 × 2,448;  
1.36 MB



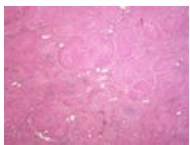
Chronická myeloidní...  
3,264 × 2,448;  
1.59 MB



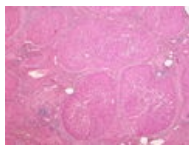
Chronický absces...  
3,264 × 2,448;  
1.34 MB



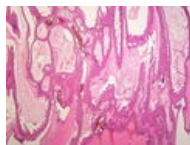
Chronický absces...  
3,264 × 2,448;  
1.29 MB



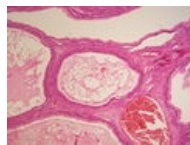
Cirhóza (41A).jpg  
3,264 × 2,448; 1.3  
MB



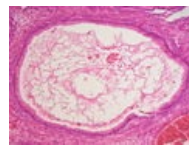
Cirhóza (41B).jpg  
3,264 × 2,448;  
1.34 MB



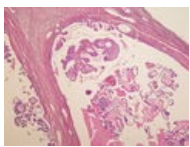
Cystadenoma m...  
3,264 × 2,448;  
1.71 MB



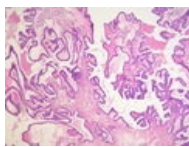
Cystadenoma m...  
3,264 × 2,448;  
1.54 MB



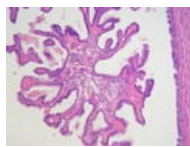
Cystadenoma m...  
3,264 × 2,448;  
1.62 MB



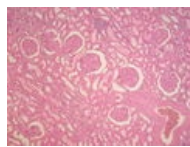
Cystadenoma ser...  
3,264 × 2,448;  
1.51 MB



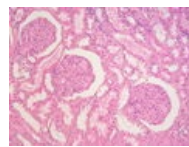
Cystadenoma ser...  
3,264 × 2,448;  
1.51 MB



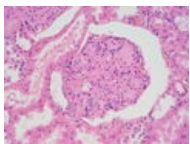
Cystadenoma ser...  
3,264 × 2,448;  
1.78 MB



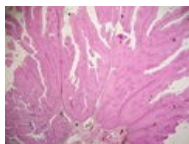
Diabetická glome...  
3,264 × 2,448;  
1.35 MB



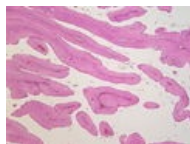
Diabetická glome...  
3,264 × 2,448;  
1.47 MB



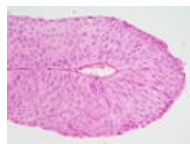
Diabetická glome...  
3,264 × 2,448;  
1.58 MB



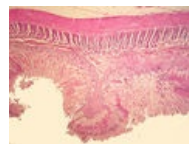Dobře diferencov...  
3,264 × 2,448;  
1.73 MB



Dobře diferencov...  
3,264 × 2,448;  
1.36 MB

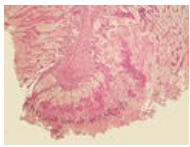


Dobře diferencov...  
3,264 × 2,448;  
1.67 MB

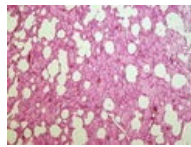


Dyzentérie (18A)...  
3,264 × 2,448;  
2.44 MB

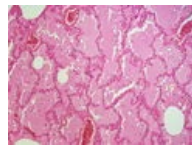




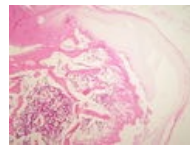
Dyzentérie (18B)...  
3,264 × 2,448;  
2.04 MB



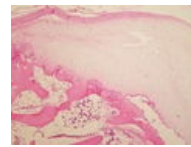
Edém plic (10A).j...  
3,264 × 2,448;  
3.69 MB



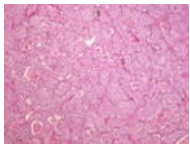
Edém plic (10B).j...  
3,264 × 2,448;  
3.28 MB



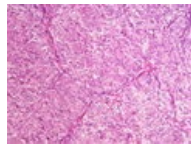
Exostosis cartilag...  
3,264 × 2,448;  
3.29 MB



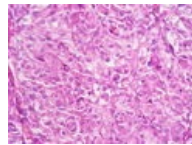
Exostosis cartilag...  
3,264 × 2,448;  
3.08 MB



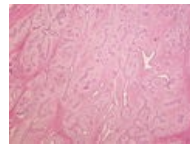
Feochromocytom...  
3,264 × 2,448;  
1.32 MB



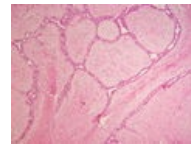
Feochromocytom...  
3,264 × 2,448;  
3.41 MB



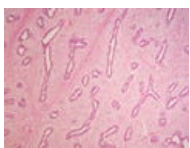Feochromocytom...  
3,264 × 2,448; 1.4  
MB



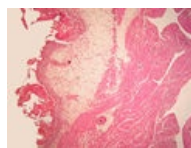
Fibroadenom ma...  
3,264 × 2,448;  
1.68 MB



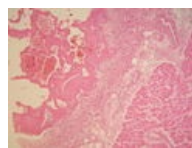
Fibroadenom ma...  
3,264 × 2,448;  
1.36 MB



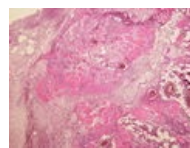
Fibroadenom ma...  
3,264 × 2,448;  
1.54 MB



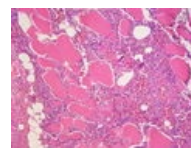
Fibrózní perikardi...  
3,264 × 2,448;  
2.53 MB



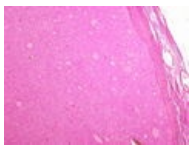Fibrózní perikardi...  
3,264 × 2,448;  
1.42 MB



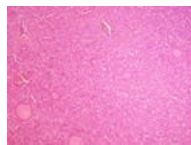
Flegmóna koster...  
3,264 × 2,448;  
4.52 MB



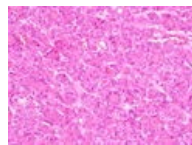
Flegmóna koster...  
3,264 × 2,448;  
1.34 MB



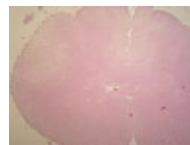
Folikulární karcin...  
3,264 × 2,448;  
3.45 MB



Folikulární karcin...  
3,264 × 2,448;  
4.51 MB



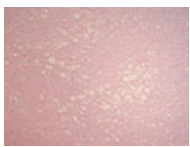
Folikulární karcin...  
3,264 × 2,448;  
3.56 MB



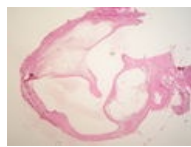
Funikulární myel...  
3,264 × 2,448;  
1.37 MB



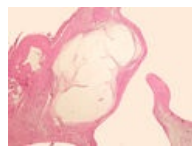
Funikulární myel...  
3,264 × 2,448;  
1.63 MB



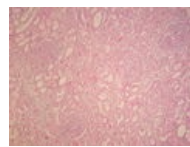
Funikulární myel...  
3,264 × 2,448;  
1.44 MB



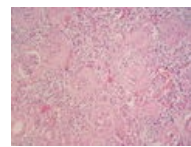
Ganglion (74A).jpg  
3,264 × 2,448;  
1.84 MB



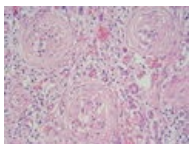
Ganglion (74B).jpg  
3,264 × 2,448;  
1.41 MB



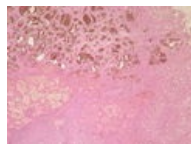
Glomerulonefritis...  
3,264 × 2,448;  
1.56 MB



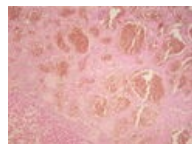Glomerulonefritis...  
3,264 × 2,448;  
1.44 MB



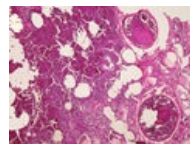
Glomerulonefritis...  
3,264 × 2,448;  
1.56 MB



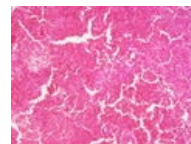
Hemangiom jater...  
3,264 × 2,448;  
1.62 MB



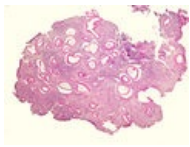
Hemangiom jater...  
3,264 × 2,448;  
1.31 MB



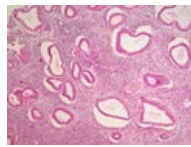
Hemoragický infa...  
3,264 × 2,448;  
3.55 MB



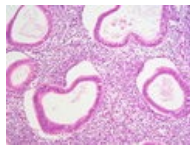
Hemoragický infa...  
3,264 × 2,448;  
4.57 MB



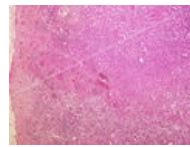
Hyperplastické e...  
3,264 × 2,448;  
2.22 MB



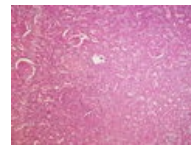
Hyperplastické e...  
3,264 × 2,448;  
1.75 MB



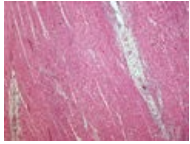
Hyperplastické e...  
3,264 × 2,448;  
1.39 MB



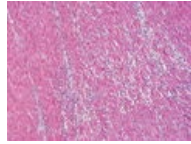
Infarkt ledviny (2...  
3,264 × 2,448;  
5.08 MB



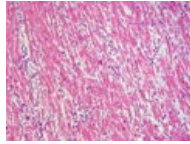
Infarkt ledviny (2...  
3,264 × 2,448;  
4.43 MB



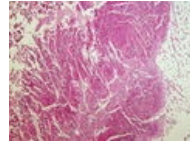
Infarkt myokardu...  
3,264 × 2,448;  
4.56 MB



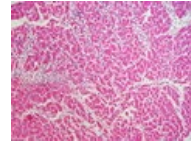
Infarkt myokardu...  
3,264 × 2,448;  
4.56 MB



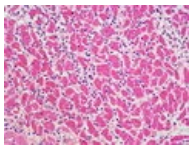
Infarkt myokardu...  
3,264 × 2,448; 3.6  
MB



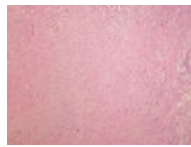
Infarkt myokardu...  
3,264 × 2,448;  
4.43 MB



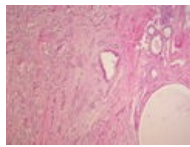
Infarkt myokardu...  
3,264 × 2,448;  
3.62 MB



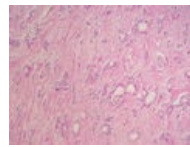
Infarkt myokardu...  
3,264 × 2,448;  
3.41 MB



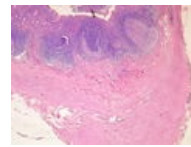
Infiltrující karcino...  
3,264 × 2,448;  
3.71 MB



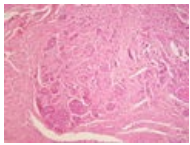
Infiltrující karcino...  
3,264 × 2,448;  
3.54 MB



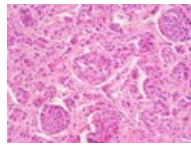
Infiltrující karcino...  
3,264 × 2,448;  
3.91 MB



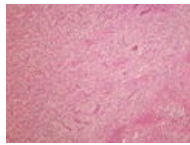
Karcinoid append...  
3,264 × 2,448;  
1.35 MB



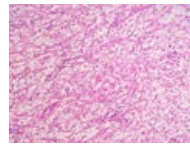
Karcinoid append...  
3,264 × 2,448;  
1.36 MB



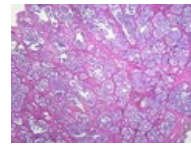
Karcinoid append...  
3,264 × 2,448;  
1.42 MB



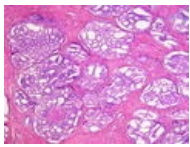
Karcinom ledviny...  
3,264 × 2,448;  
1.36 MB



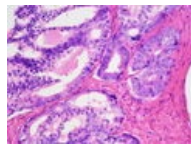
Karcinom ledviny...  
3,264 × 2,448; 1.4  
MB



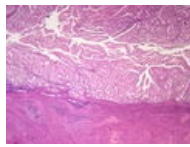
Karcinom prostat...  
3,264 × 2,448;  
1.37 MB



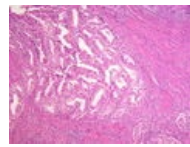
Karcinom prostat...  
3,264 × 2,448;  
1.76 MB



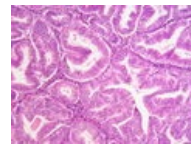
Karcinom prostat...  
3,264 × 2,448;  
1.53 MB



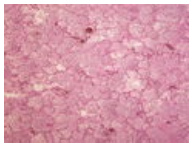
Karcinom těla děl...  
3,264 × 2,448;  
1.64 MB



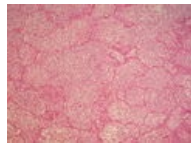
Karcinom těla děl...  
3,264 × 2,448;  
1.67 MB



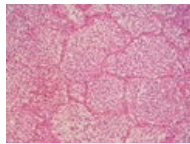
Karcinom těla děl...  
3,264 × 2,448;  
1.62 MB



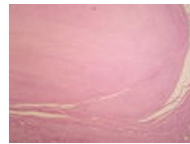
Katarální bronch...  
3,264 × 2,448;  
1.31 MB



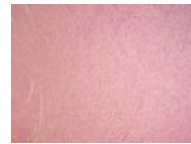Katarální bronch...  
3,264 × 2,448;  
1.85 MB



Katarální bronch...  
3,264 × 2,448;  
1.64 MB

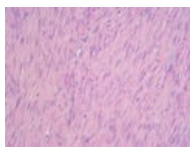


Leiomyoma uteri ...  
3,264 × 2,448;  
1.39 MB

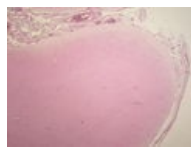


Leiomyoma uteri ...  
3,264 × 2,448;  
1.48 MB

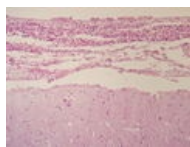




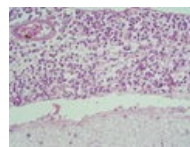
Leiomyoma uteri ...  
3,264 × 2,448;  
1.56 MB



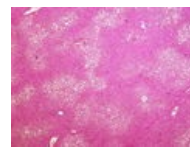
Leptomeningitis ...  
3,264 × 2,448;  
1.59 MB



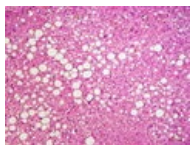
Leptomeningitis ...  
3,264 × 2,448;  
1.47 MB



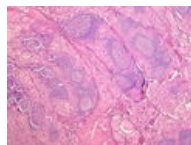
Leptomeningitis ...  
3,264 × 2,448; 1.6  
MB



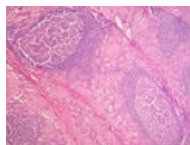
Ložisková velkok...  
3,264 × 2,448;  
4.71 MB



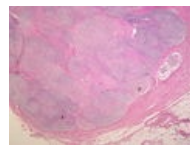
Ložisková velkok...  
3,264 × 2,448;  
3.62 MB



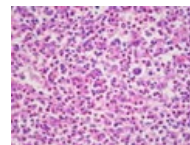
Lymfoplasmocyt...  
3,264 × 2,448;  
3.92 MB



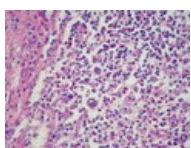
Lymfoplasmocyt...  
3,264 × 2,448;  
4.29 MB



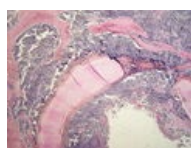
Maligní lymfogra...  
3,264 × 2,448;  
1.29 MB



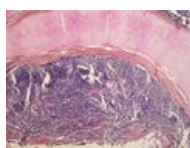
Maligní lymfogra...  
3,264 × 2,448;  
1.67 MB



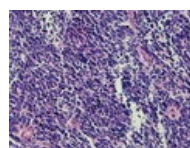
Maligní lymfogra...  
3,264 × 2,448;  
1.59 MB



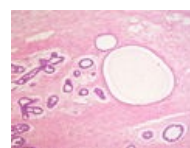
Malobuněčný kar...  
3,264 × 2,448;  
1.91 MB



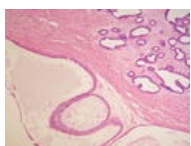
Malobuněčný kar...  
3,264 × 2,448;  
1.31 MB



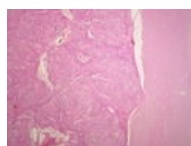
Malobuněčný kar...  
3,264 × 2,448;  
1.34 MB



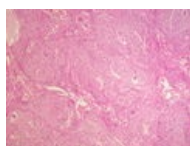
Mastopathia fibro...  
3,264 × 2,448; 1.5  
MB



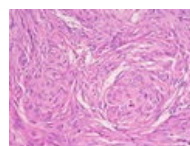
Mastopathia fibro...  
3,264 × 2,448;  
1.54 MB



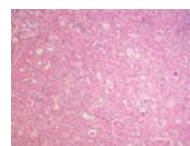
Meningeom (69A...  
3,264 × 2,448;  
1.54 MB



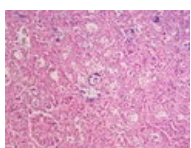
Meningeom (69B...  
3,264 × 2,448;  
1.65 MB



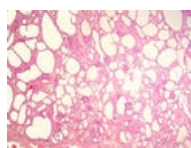
Meningeom (69C...  
3,264 × 2,448;  
1.39 MB



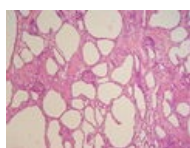
Metastatické zvá...  
3,264 × 2,448;  
1.37 MB



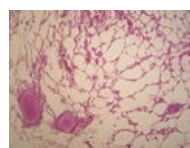
Metastatické zvá...  
3,264 × 2,448;  
1.54 MB



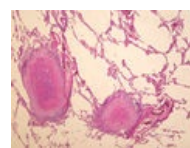
Mikrocystóza led...  
3,264 × 2,448;  
2.34 MB



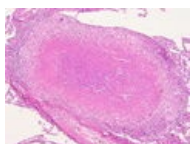
Mikrocystóza led...  
3,264 × 2,448;  
3.05 MB



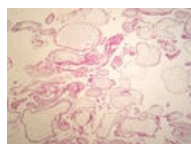
Miliární TBC plic (...  
3,264 × 2,448; 1.5  
MB



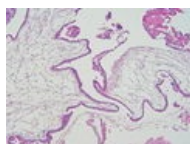
Miliární TBC plic (...  
3,264 × 2,448;  
1.93 MB



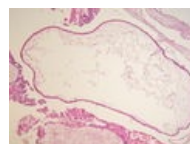
Miliární TBC plic (...  
3,264 × 2,448;  
1.74 MB



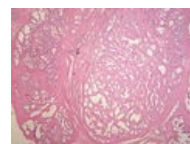
Mola hydatidosa ...  
3,264 × 2,448;  
1.93 MB



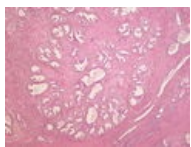
Mola hydatidosa ...  
3,264 × 2,448;  
1.48 MB



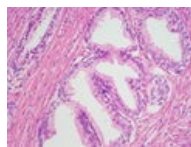
Mola hydatidosa ...  
3,264 × 2,448;  
1.71 MB



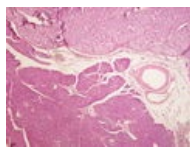
Myoadenomová ...  
3,264 × 2,448;  
1.66 MB



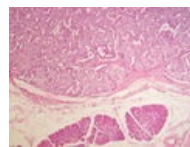
Myoadenomová ...  
3,264 × 2,448; 1.3 MB



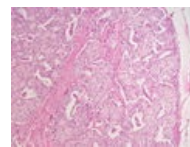
Myoadenomová ...  
3,264 × 2,448; 1.53 MB



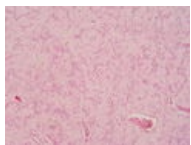
Nesidiom (79A).jpg  
3,264 × 2,448; 4.35 MB



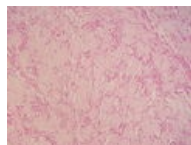
Nesidiom (79B).jpg  
3,264 × 2,448; 4 MB



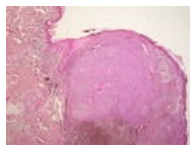
Nesidiom (79C).jpg  
3,264 × 2,448; 1.46 MB



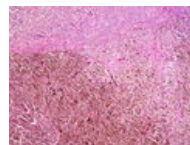
Neurilemom (25A)...  
3,264 × 2,448; 1.38 MB



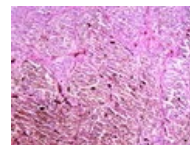
Neurilemom (25B)...  
3,264 × 2,448; 1.51 MB



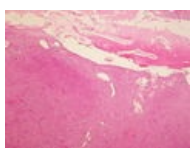
Nodulární melan...  
3,264 × 2,448; 4.44 MB



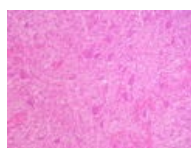
Nodulární melan...  
3,264 × 2,448; 1.3 MB



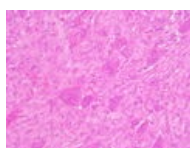
Nodulární melan...  
3,264 × 2,448; 1.79 MB



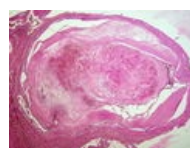
Obrovskobuněčn...  
3,264 × 2,448; 3.97 MB



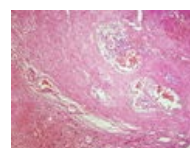
Obrovskobuněčn...  
3,264 × 2,448; 1.44 MB



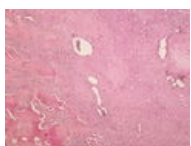Obrovskobuněčn...  
3,264 × 2,448; 1.52 MB



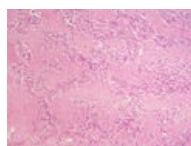
Organizovaný tro...  
3,264 × 2,448; 3.62 MB



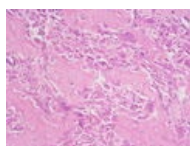
Organizovaný tro...  
3,264 × 2,448; 3.64 MB



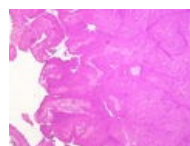
Osteosarkom (72...  
3,264 × 2,448; 1.38 MB



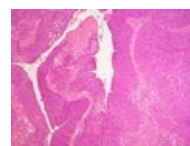
Osteosarkom (72...  
3,264 × 2,448; 1.46 MB



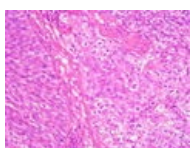
Osteosarkom (72...  
3,264 × 2,448; 1.69 MB



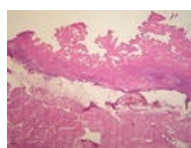
Papilokarcinom ...  
3,264 × 2,448; 1.35 MB



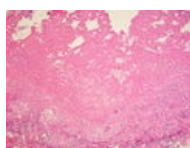
Papilokarcinom ...  
3,264 × 2,448; 1.36 MB



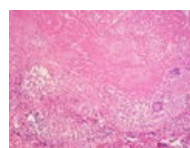
Papilokarcinom ...  
3,264 × 2,448; 1.43 MB



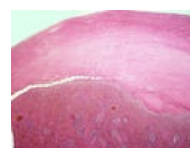Pericarditis TBC (...  
3,264 × 2,448; 1.58 MB



Pericarditis TBC (...  
3,264 × 2,448; 1.39 MB



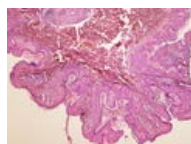
Pericarditis TBC (...  
3,264 × 2,448; 1.35 MB



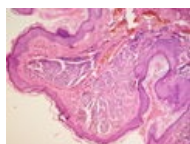
Perisplenitis carti...  
3,264 × 2,448; 3.03 MB



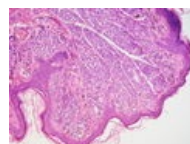
Perisplenitis carti...  
3,264 × 2,448; 4.27 MB



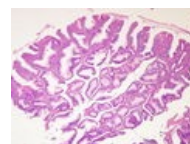
Pigmentový névu...  
3,264 × 2,448; 1.78 MB



Pigmentový névu...  
3,264 × 2,448; 1.38 MB

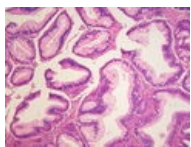


Pigmentový névu...  
3,264 × 2,448; 1.48 MB

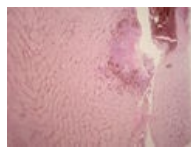

Polypózní adeno...  
3,264 × 2,448; 1.39 MB

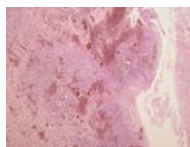



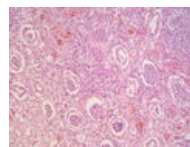
Polypózní adeno...  
3,264 × 2,448;  
1.42 MB



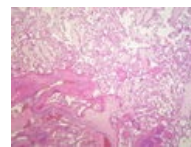
Pyelonefritis hnis...  
3,264 × 2,448; 1.4  
MB



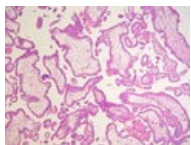
Pyelonefritis hnis...  
3,264 × 2,448;  
1.88 MB



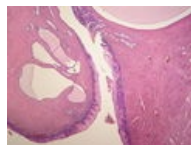
Pyelonefritis hnis...  
3,264 × 2,448;  
1.55 MB



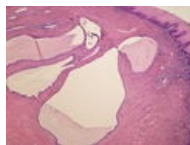Residua post abo...  
3,264 × 2,448;  
1.66 MB



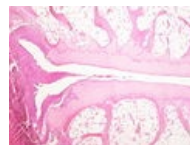
Residua post abo...  
3,264 × 2,448;  
1.47 MB



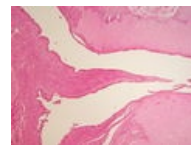
Retenční cysty c...  
3,264 × 2,448;  
1.55 MB



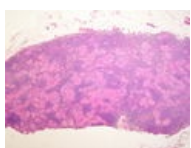
Retenční cysty c...  
3,264 × 2,448;  
1.63 MB



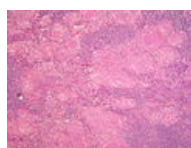Revmatoidní artri...  
3,264 × 2,448;  
1.42 MB



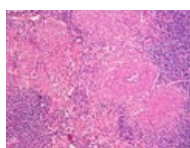
Revmatoidní artri...  
3,264 × 2,448;  
1.54 MB



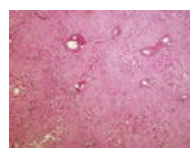
Sarkoidóza uzliny...  
3,264 × 2,448;  
1.72 MB



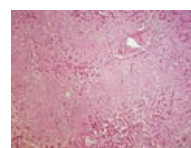
Sarkoidóza uzliny...  
3,264 × 2,448;  
1.54 MB



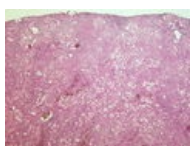
Sarkoidóza uzliny...  
3,264 × 2,448;  
1.84 MB



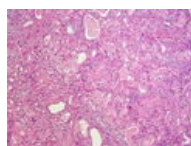
Sekundární amyl...  
3,264 × 2,448;  
3.83 MB



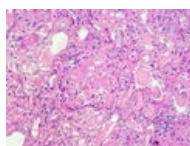
Sekundární amyl...  
3,264 × 2,448; 3.7  
MB



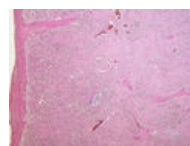
Sekundární amyl...  
3,264 × 2,448;  
4.41 MB



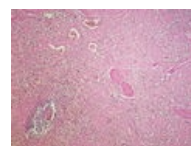Sekundární amyl...  
3,264 × 2,448;  
3.58 MB



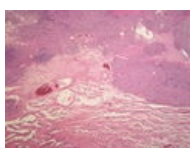
Sekundární amyl...  
3,264 × 2,448;  
3.28 MB



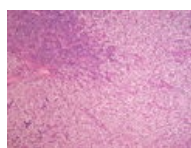
Sekundární amyl...  
3,264 × 2,448;  
3.98 MB



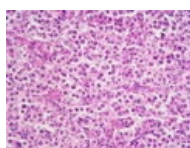
Sekundární amyl...  
3,264 × 2,448;  
4.41 MB



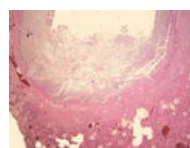
Seminom varlete...  
3,264 × 2,448;  
1.31 MB



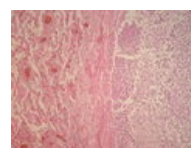
Seminom varlete...  
3,264 × 2,448; 1.3  
MB



Seminom varlete...  
3,264 × 2,448;  
1.49 MB



Septické metasta...  
3,264 × 2,448;  
2.78 MB



Septické metasta...  
3,264 × 2,448;  
1.36 MB

(previous page) (next page)