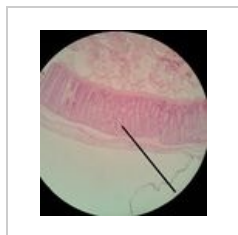


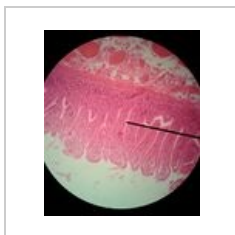
Kategorie:Poznávačka - Histologie - Trávicí systém

Media in category "Poznávačka - Histologie - Trávicí systém"

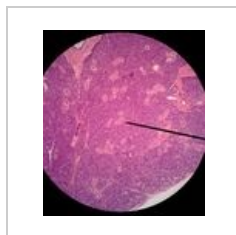
The following 67 files are in this category, out of 67 total.



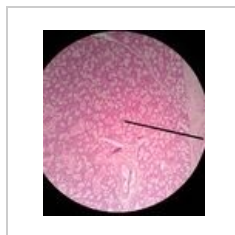04 Tluste strevo.j...
1,920 × 2,127;
1.03 MB



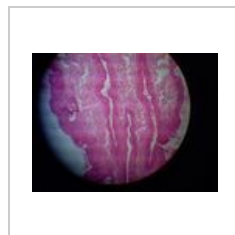
12 Tenke strevo.j...
1,920 × 2,279;
1.26 MB



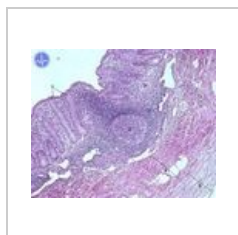
14 Parotis.jpg
1,920 × 2,201;
1.49 MB



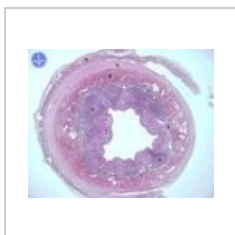
15 Submandibula...
1,910 × 2,191;
1.41 MB



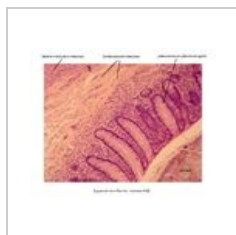
Anus1.jpg
640 × 480; 88 KB



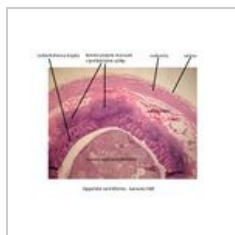
Appendix 2.jpg
600 × 480; 96 KB



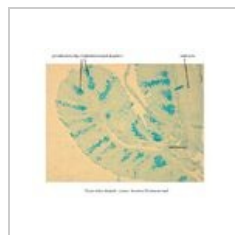Appendix.jpg
600 × 480; 42 KB



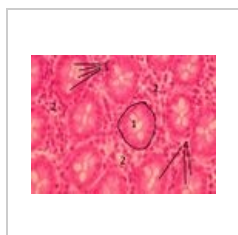Appendix - detail...
3,046 × 2,454;
1.11 MB



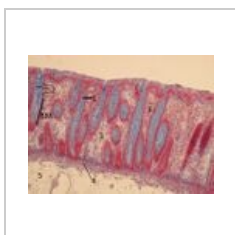Appendix2.jpg
1,595 × 1,275; 303 KB



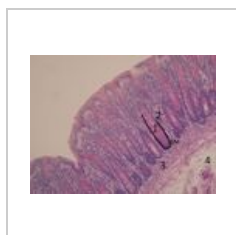
Colon - alciánová...
3,046 × 2,454; 899 KB



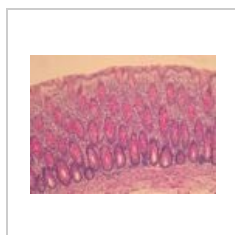
Colon 3lf.jpg
1,037 × 778; 238 KB



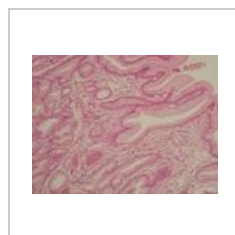Colon AZAN 3lf.jpg
1,037 × 778; 303 KB



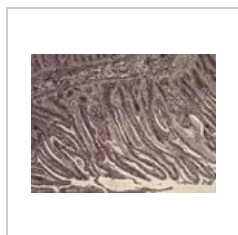
Colon PAS 3lf.jpg
1,037 × 778; 263 KB



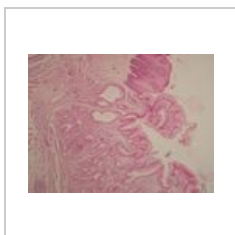
Colon PAS2.jpg
1,037 × 778; 252 KB



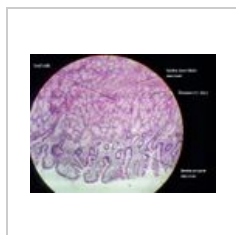
Duodenum 4.jpg
1,296 × 972; 192 KB



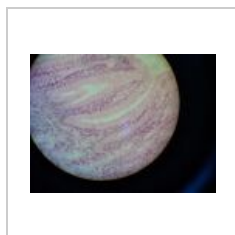
Duodenum Ag 3.j...
2,592 × 1,944;
2.54 MB



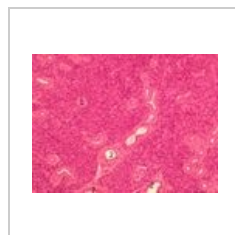
Duodenum1.jpg
1,296 × 972; 183 KB



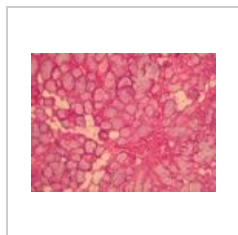
Duodenum4 -a.jpg
640 × 480; 60 KB



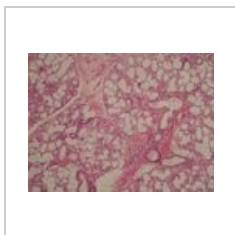
Fundus žaludku4...
640 × 480; 94 KB



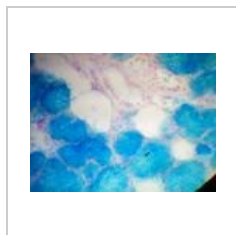Gl parotis9.jpg
1,037 × 778; 349 KB




Gl sublingualis Z...
1,296 × 972; 233 KB



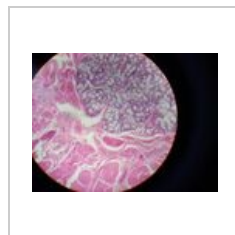
Gl submandibula...
1,037 × 778; 276 KB



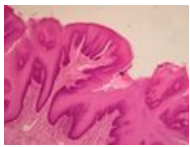
Glandula subling...
640 × 480; 115 KB



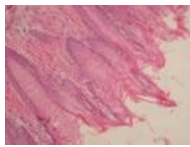
Hrazená papila 4...
1,296 × 972; 171 KB



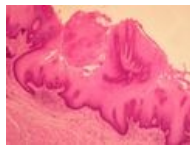
Hrot jazyka4 - jaz...
640 × 480; 122 KB



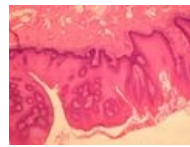
Jazyk houbovitá ...
1,296 × 972; 152
KB



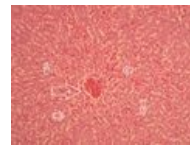
Jazyk nitkovitá p...
1,296 × 972; 187
KB




Jazyk nitkovitá p...
1,296 × 972; 193
KB



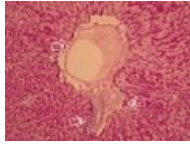
Jazyk papily 2.jpg
1,296 × 972; 199
KB



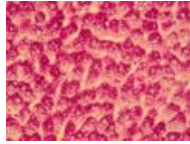
Játra 3 upr2.jpg
1,296 × 972; 562
KB



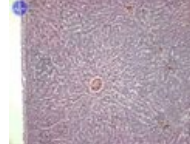
Játra Ag 2 upr2.jpg
1,296 × 972; 969
KB



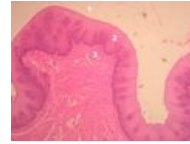
Játra PAS 13 upr2...
1,296 × 972; 601
KB



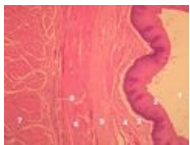
Játra PAS 3 upr.jpg
1,296 × 972; 608
KB



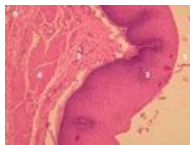Játra.jpg
600 × 480; 68 KB



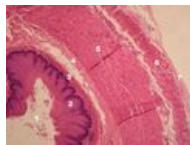
Jícen 13 upr.jpg
2,592 × 1,944;
1.61 MB



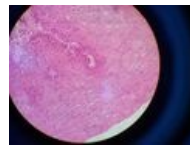
Jícen 2 upr.jpg
2,592 × 1,944; 1.6
MB



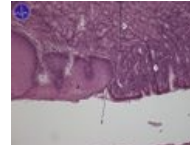
Jícen upr.jpg
2,592 × 1,944;
1.59 MB



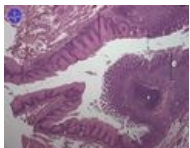Jícen3 upr.jpg
2,592 × 1,944;
1.71 MB



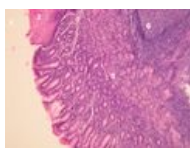Jícen3.jpg
640 × 480; 120 KB



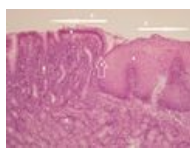
Kardie 2.jpg
600 × 480; 59 KB



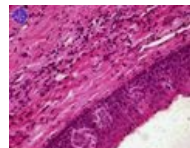
Kardie 3.jpg
600 × 480; 70 KB



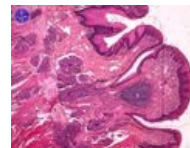
Kardie 4 upr.jpg
2,592 × 1,944; 1.7
MB



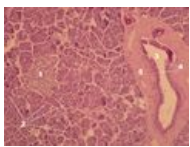
Kardie.jpg
2,592 × 1,944;
1.49 MB



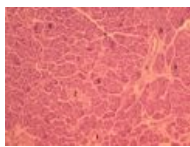
Kořen jazyka 3.jpg
600 × 480; 73 KB



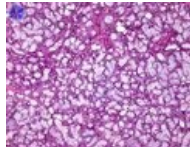
Kořen jazyka.jpg
600 × 480; 78 KB



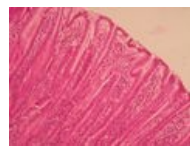
Pankreas 24 upr.j...
2,592 × 1,944;
1.61 MB



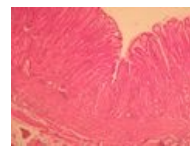
Pankreas 5.jpg
1,037 × 778; 326
KB



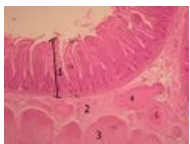
Podjazyková žláz...
600 × 480; 117 KB



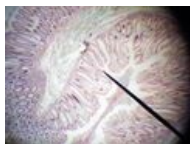
Pylorus 2.jpg
1,296 × 972; 219
KB



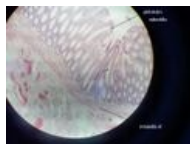
Pylorus 9.jpg
1,296 × 972; 264
KB



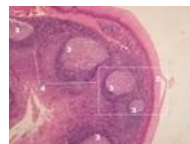Tenké střevo lf3.j...
1,037 × 778; 320
KB



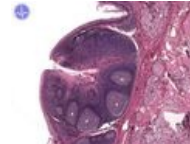
Tlusté střevo - ze...
640 × 480; 155 KB



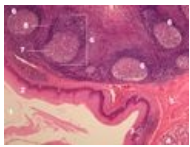
Tlusté střevo2 - a...
640 × 480; 38 KB



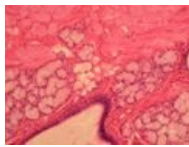
Tonsilla lingualis ...
2,592 × 1,944; 2.1
MB



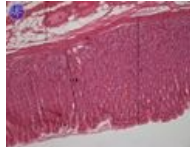
Tonsilla lingualis ...
600 × 480; 65 KB



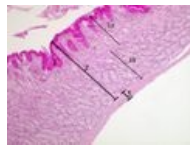
Tonsilla lingualis....
2,592 × 1,944;
2.16 MB



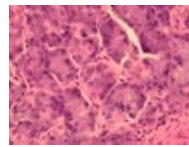
Weberovy žlázy...
1,296 × 972; 184
KB



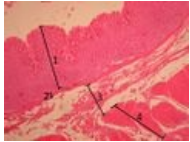
Žaludek 2.jpg
600 × 480; 58 KB



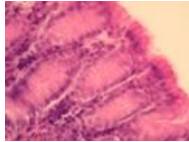
Žaludek fundus 2...
1,037 × 778; 283
KB



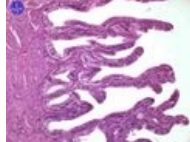
Žaludek fundus ž...
1,296 × 972; 162
KB



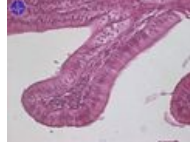Žaludek fundus.jpg
1,037 × 778; 325
KB



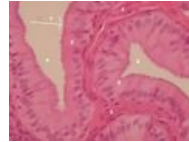Žaludek jamky.jpg
1,296 × 972; 131
KB



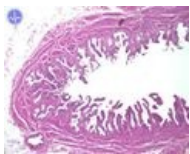
Žlučník 10.jpg
600 × 480; 55 KB



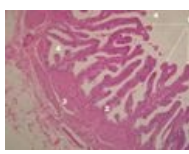
Žlučník 11.jpg
600 × 479; 46 KB



Žlučník 12 upr.jpg
1,296 × 972; 399
KB



Žlučník 7.jpg
600 × 480; 59 KB



Žlučník6 upr.jpg
1,296 × 972; 512
KB