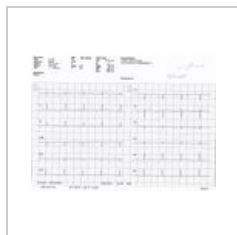

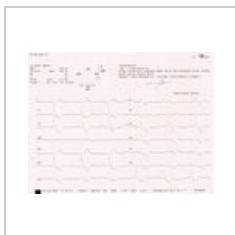Kategorie:Stefajir.cz (EKG)

Media in category "Stefajir.cz (EKG)"

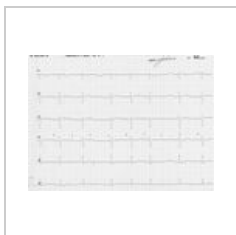
The following 38 files are in this category, out of 38 total.



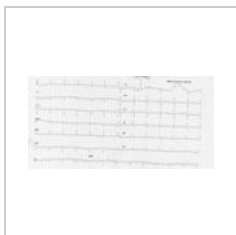
Atypický AV blok ...
720 × 527; 157 KB



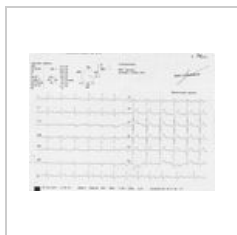
AV blok III.st. (2)....
700 × 538; 182 KB



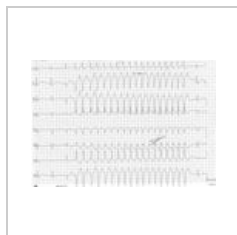
AV blok III.st..jpg
700 × 516; 181 KB



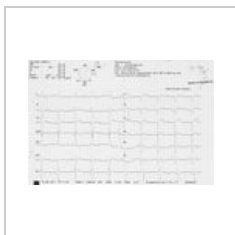
Flutter síní.jpg
871 × 435; 126 KB



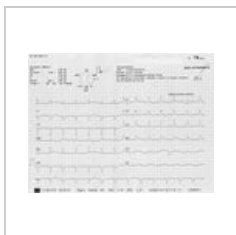
IRBBB.jpg
723 × 534; 121 KB



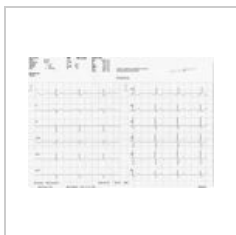
Komorová tachyk...
860 × 585; 159 KB



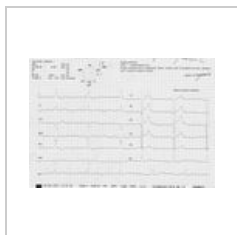
LAH, jizva přední ...
720 × 483; 187 KB



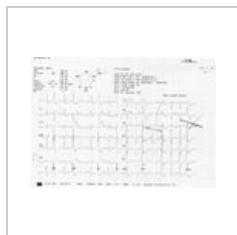
LAH, RBBB, STEM...
720 × 539; 212 KB



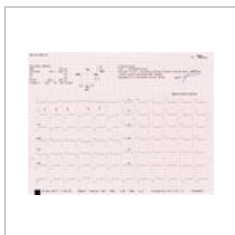
LAH, RBBB.jpg
700 × 494; 96 KB




LBBB, AV blok III....
800 × 561; 246 KB



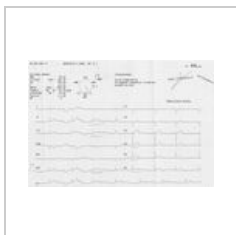
Obraz masivní pli...
720 × 508; 164 KB



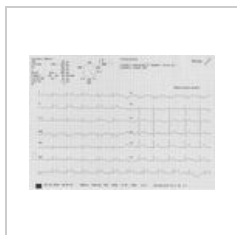
Patol. změny při ...
720 × 549; 219 KB



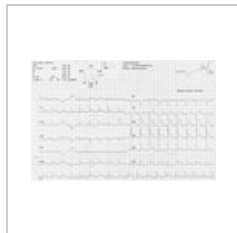
Patol. změny při ...
720 × 530; 197 KB



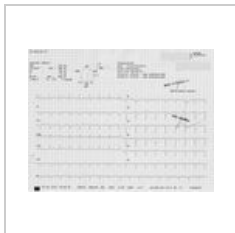
Perikarditida 2.jpg
700 × 478; 171 KB



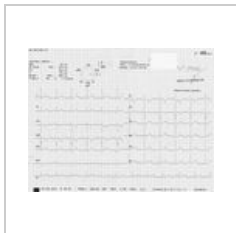
Perikarditida 3.jpg
720 × 521; 203 KB




Perikarditida.jpg
780 × 505; 143 KB



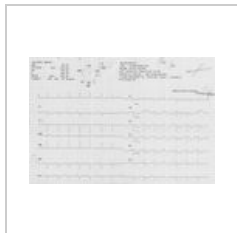
Plicní embolie 2.jpg
700 × 535; 214 KB



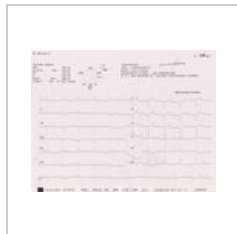
Plicní embolie 3.jpg
720 × 559; 192 KB




Plicní embolie 4.jpg
720 × 553; 170 KB



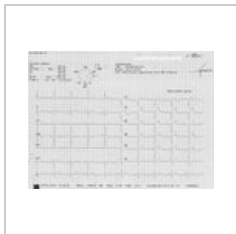
Plicní embolie.jpg
720 × 491; 174 KB



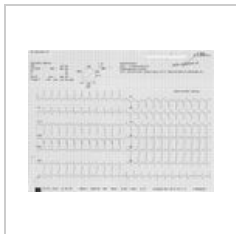
Poinfarkt. jizva, s...
720 × 551; 184 KB



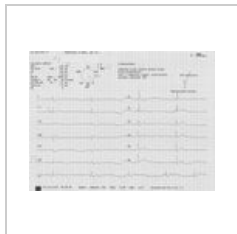
Poinfarkt. změny....
720 × 461; 129 KB



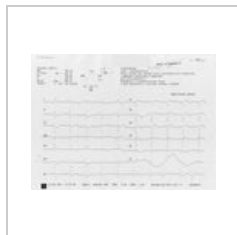
Pravidelná SVT s ...
720 × 531; 193 KB



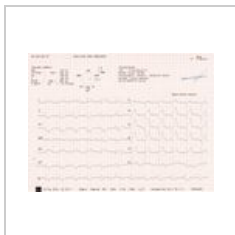
Pravidelná SVT s ...
720 × 551; 205 KB



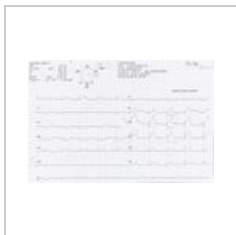Sinusová bradyk...
720 × 540; 178 KB



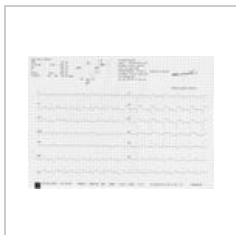
Stará jizva, nový ...
720 × 527; 178 KB




STEMI přední stě...
720 × 541; 245 KB




STEMI přední stě...
1,044 × 684; 189 KB




STEMI přední stě...
641 × 458; 149 KB



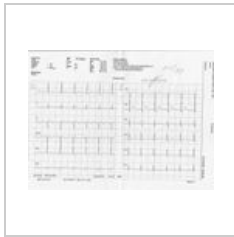STEMI spodní stě...
720 × 554; 248 KB



STEMI spodní stě...
930 × 635; 126 KB




Stimulovaný ryt...
720 × 554; 191 KB



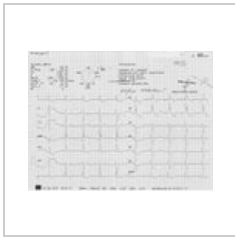
Subakutní STEMI ...
720 × 541; 122 KB



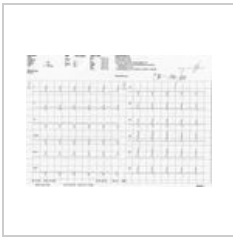Subakutní STEMI ...
720 × 509; 197 KB



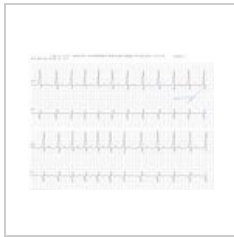
Subtotální stenóz...
720 × 538; 205 KB



Trifascikulární bl...
720 × 545; 183 KB



WPW syndrom (2...
720 × 510; 131 KB



WPW syndrom.jpg
720 × 534; 164 KB