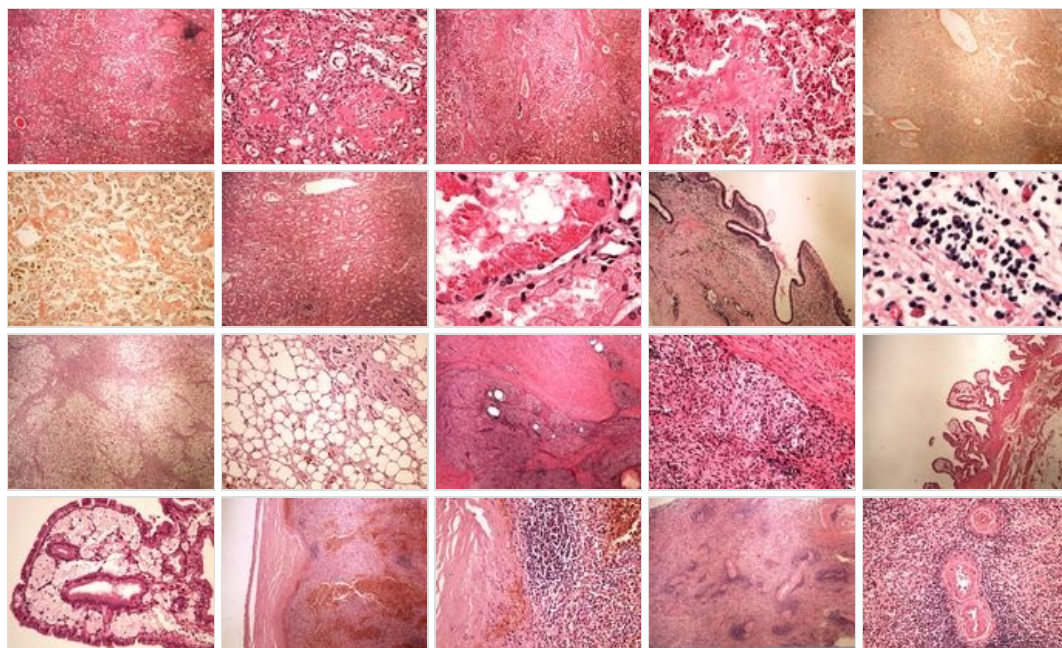
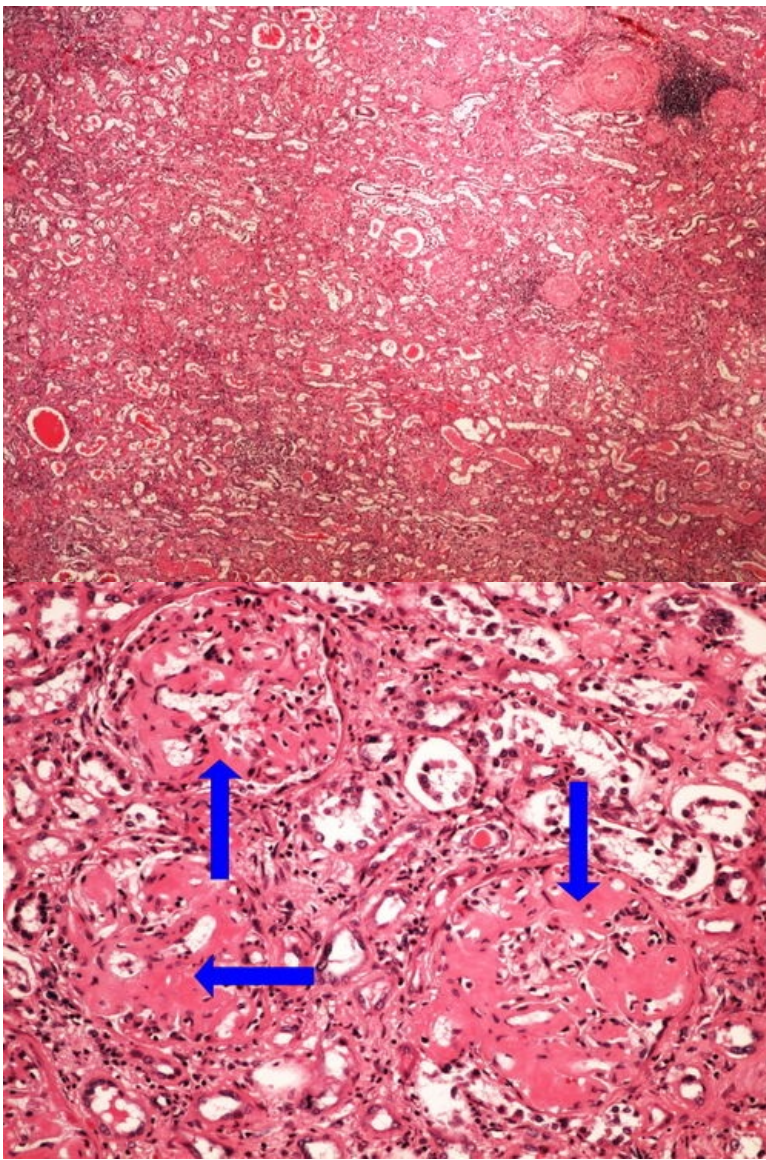


Modul OZPP - Praktikum č. 3 (zoom)

Přehled



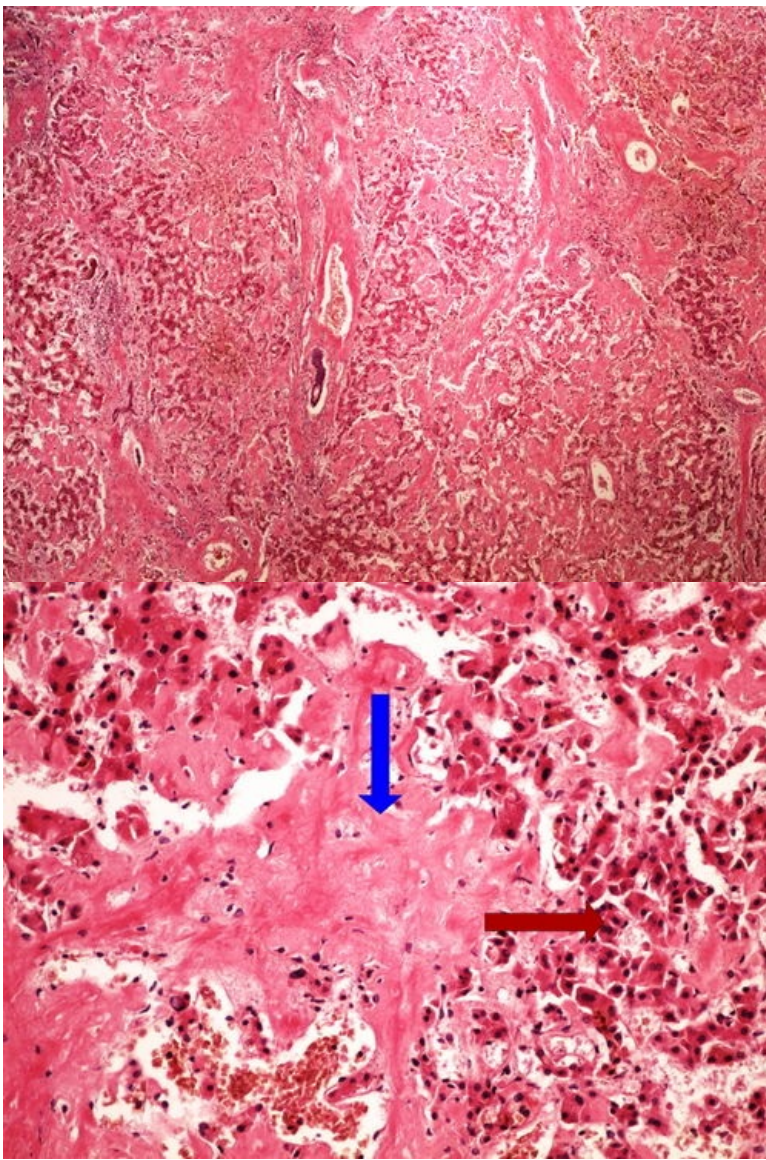
Preparát č.1 a č.2 - amyloidóza ledviny (HE)



Struktury

[Expand]

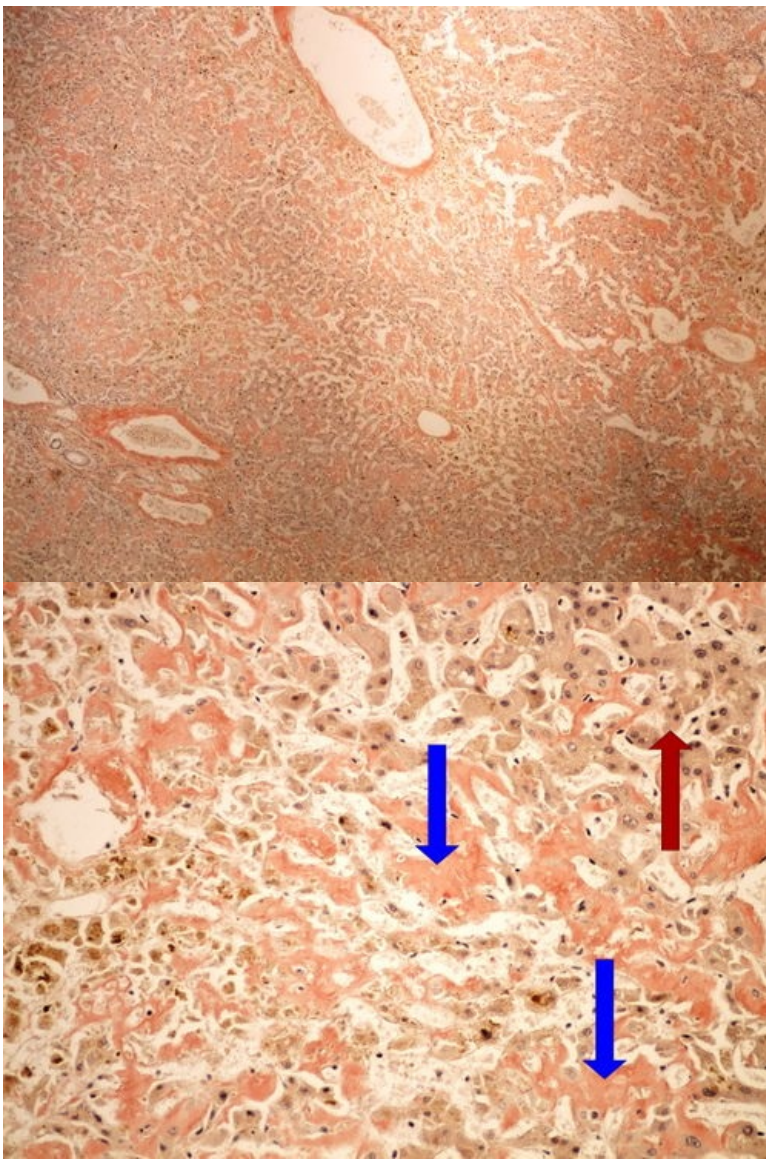
Preparát č.3 a č.4 - amyloidóza jater (HE)



Struktury

[Expand]

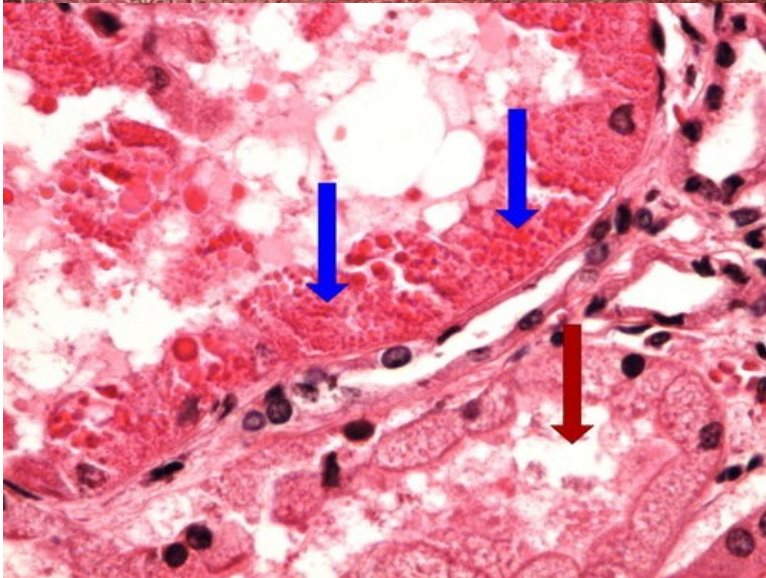
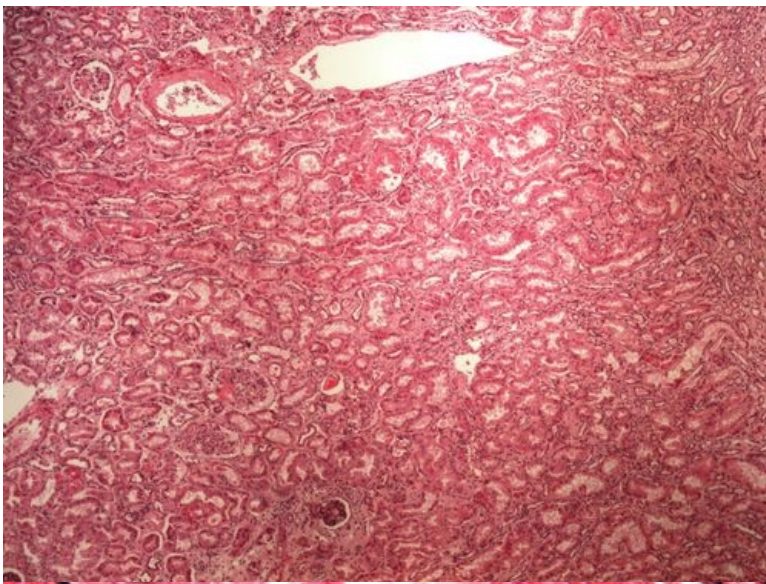
Preparát č.5 a č.6 - amyloidóza jater (kongo červen)



Struktury

[Expand]

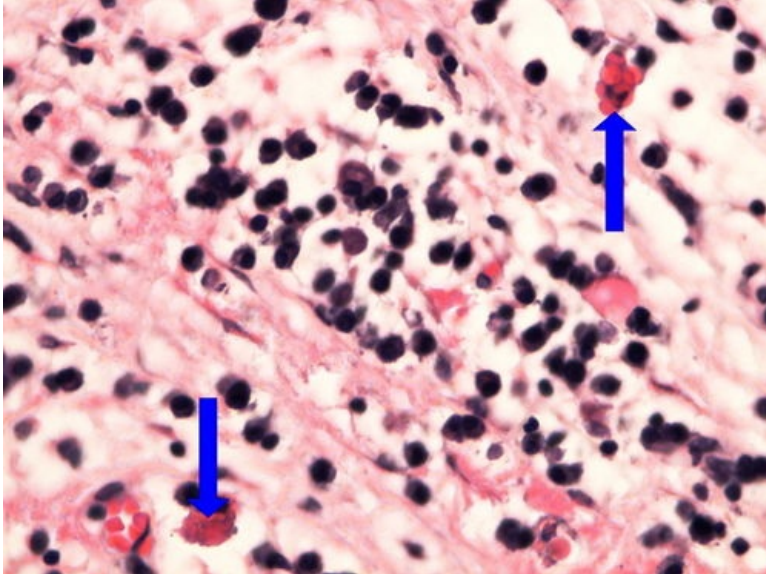
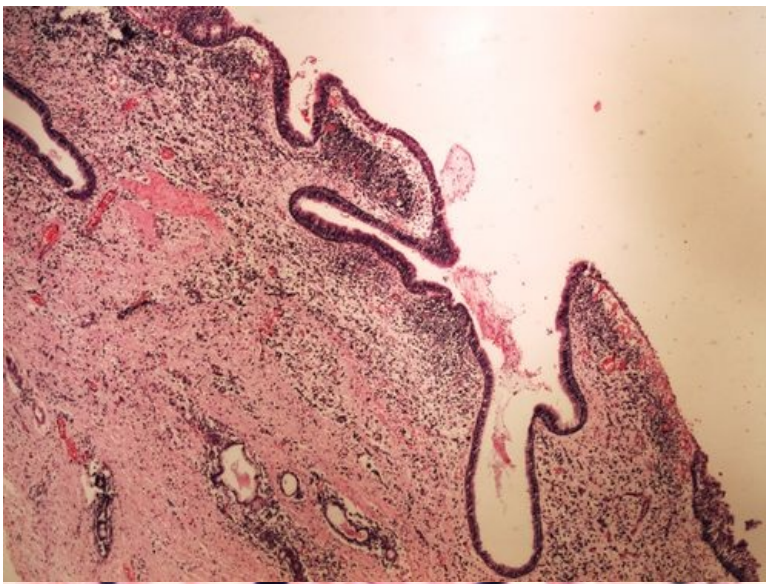
Preparát č.7 a č.8 - hyalinní zkapénkovatění ledviny



Struktury

[Expand]

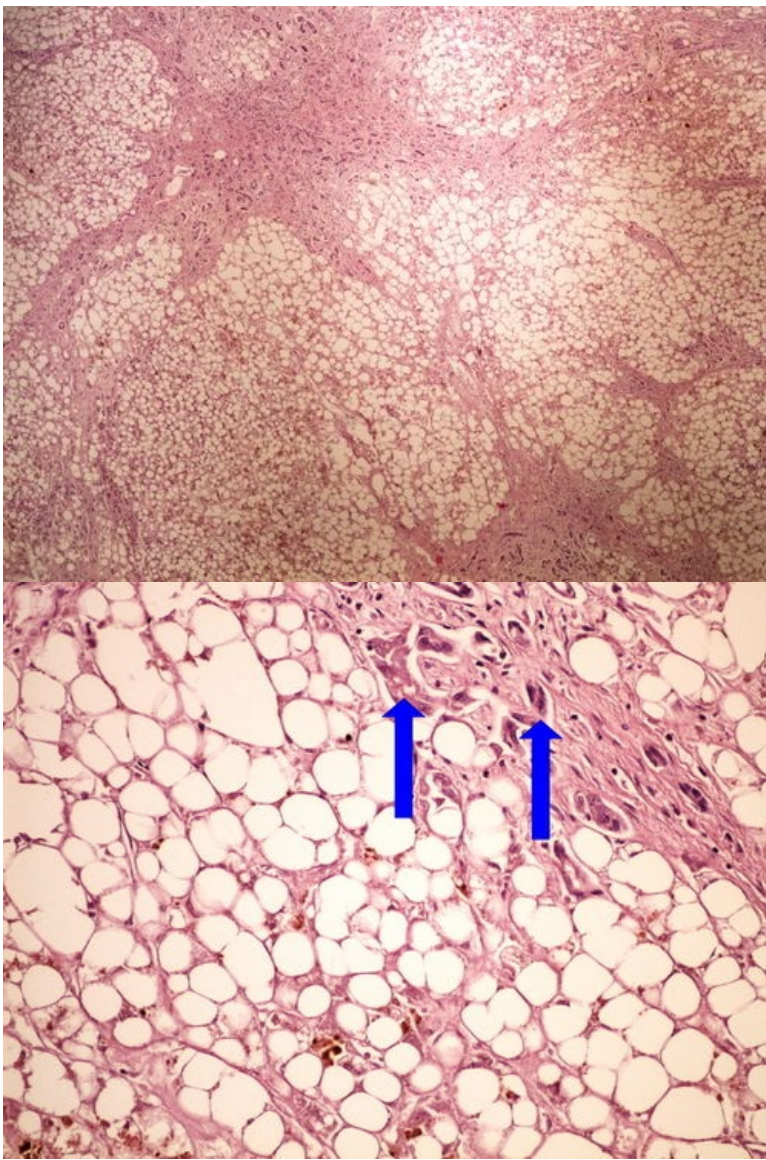
Preparát č.9 a č.10 - Russelova tělíska



Struktury

[Expand]

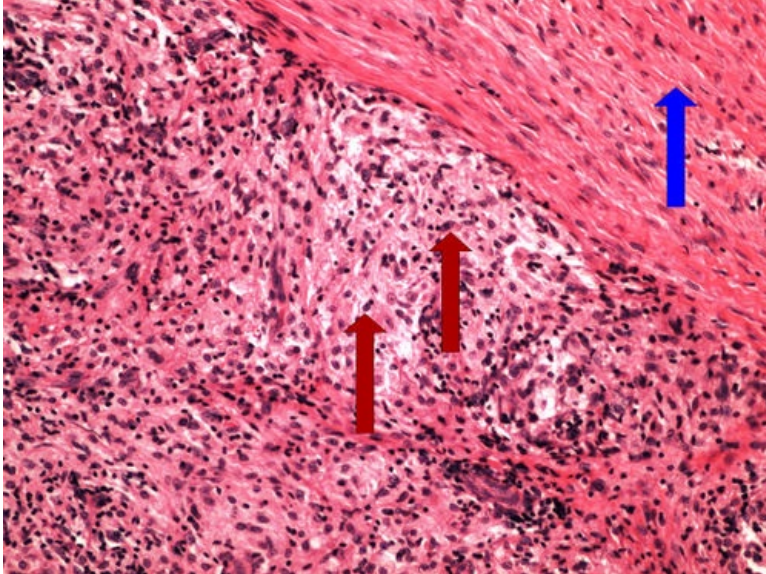
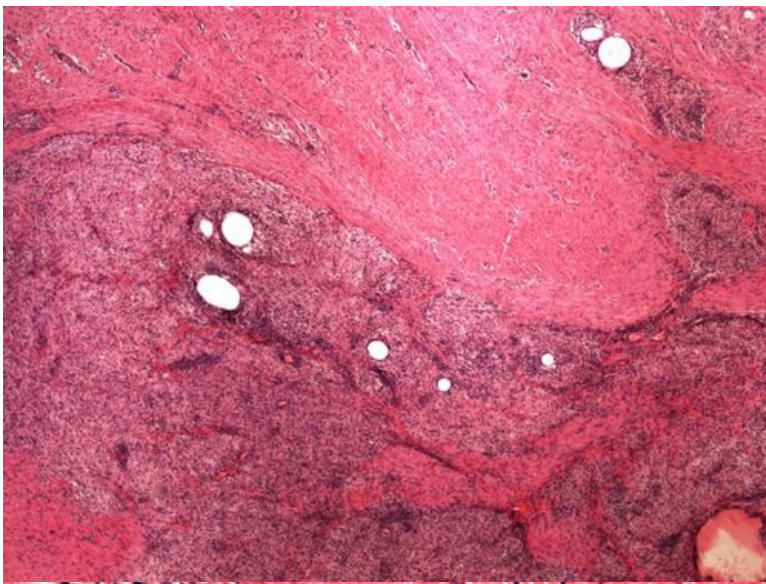
Preparát č.11 a č.12 - steatosa jater



Struktury

[Expand]

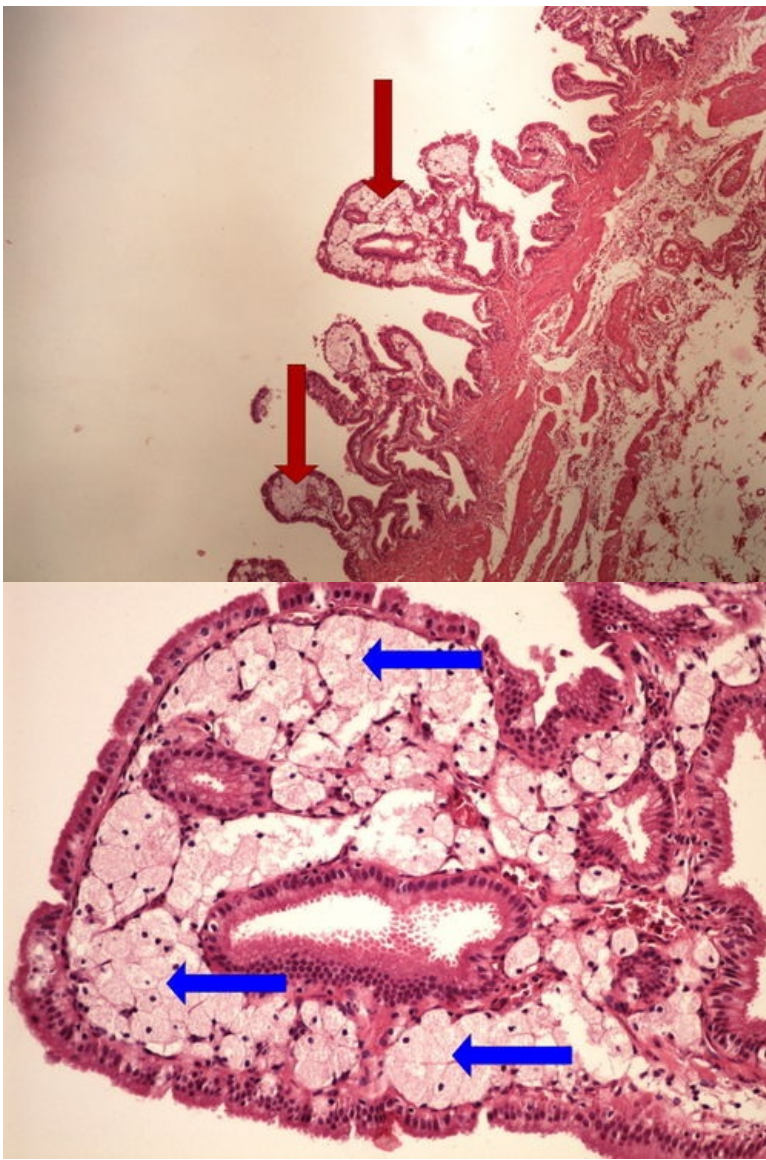
Preparát č.13 a č.14 - zánětlivý pseudoxantom



Struktury

[Expand]

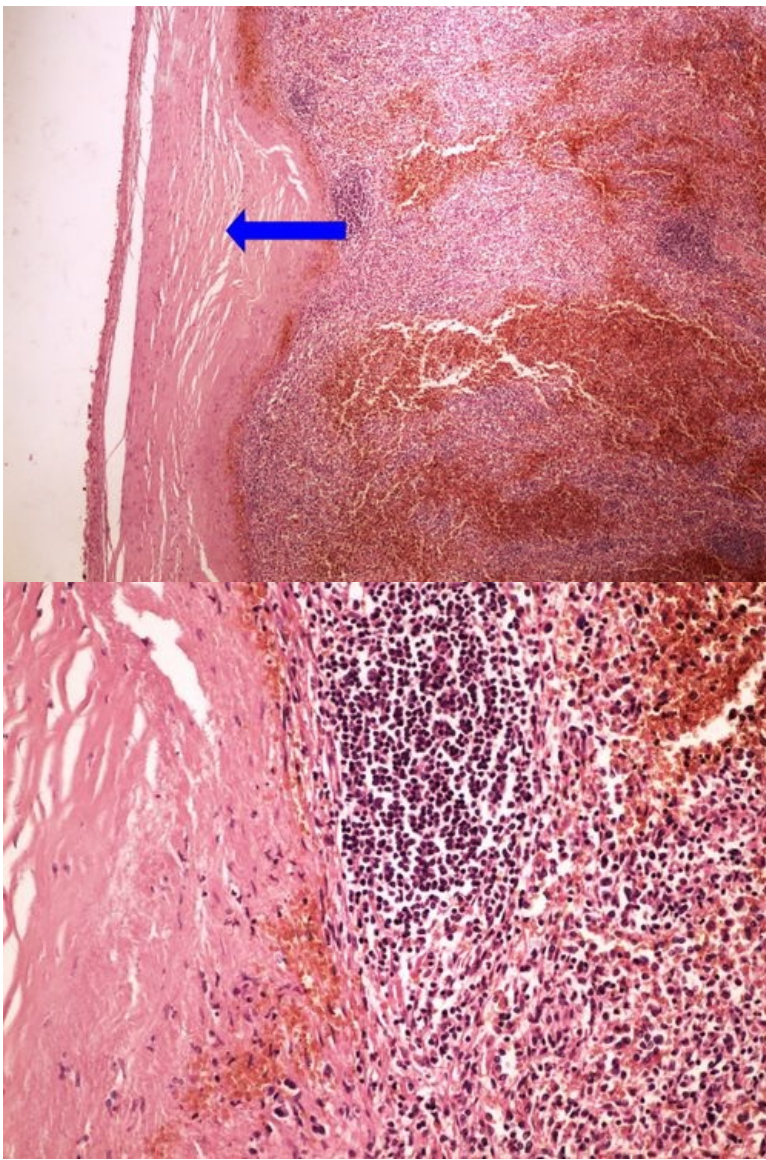
Preparát č.15 a č.16 - cholesterolosa žlučníku



Struktury

[Expand]

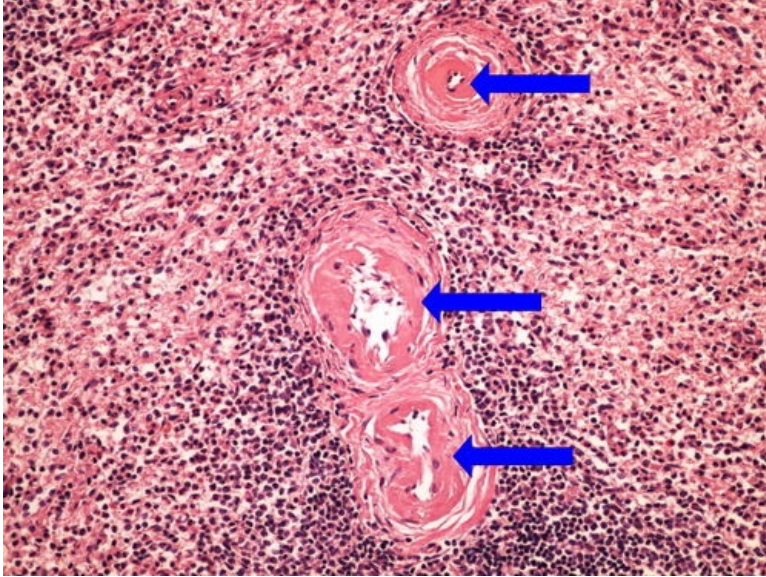
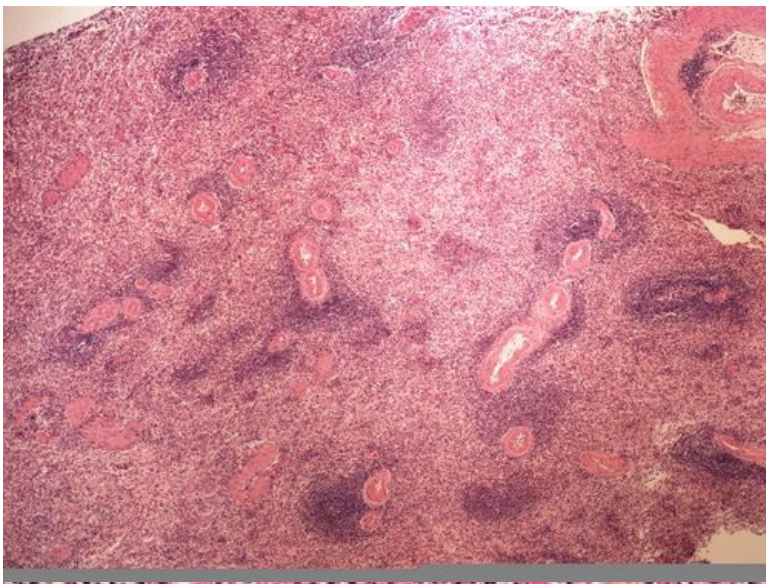
Preparát č.17 a č.18 - perisplenitis cartilaginea



Struktury

[Expand]

Preparát č.19 a č.20 - fibrinodní dystrofie



Struktury

[Expand]

Odkazy

Navigace

← Praktikum č. 2

Modul Obecné základy
patologie a patofyziologie (3.
LF UK)

Praktikum č. 4 →