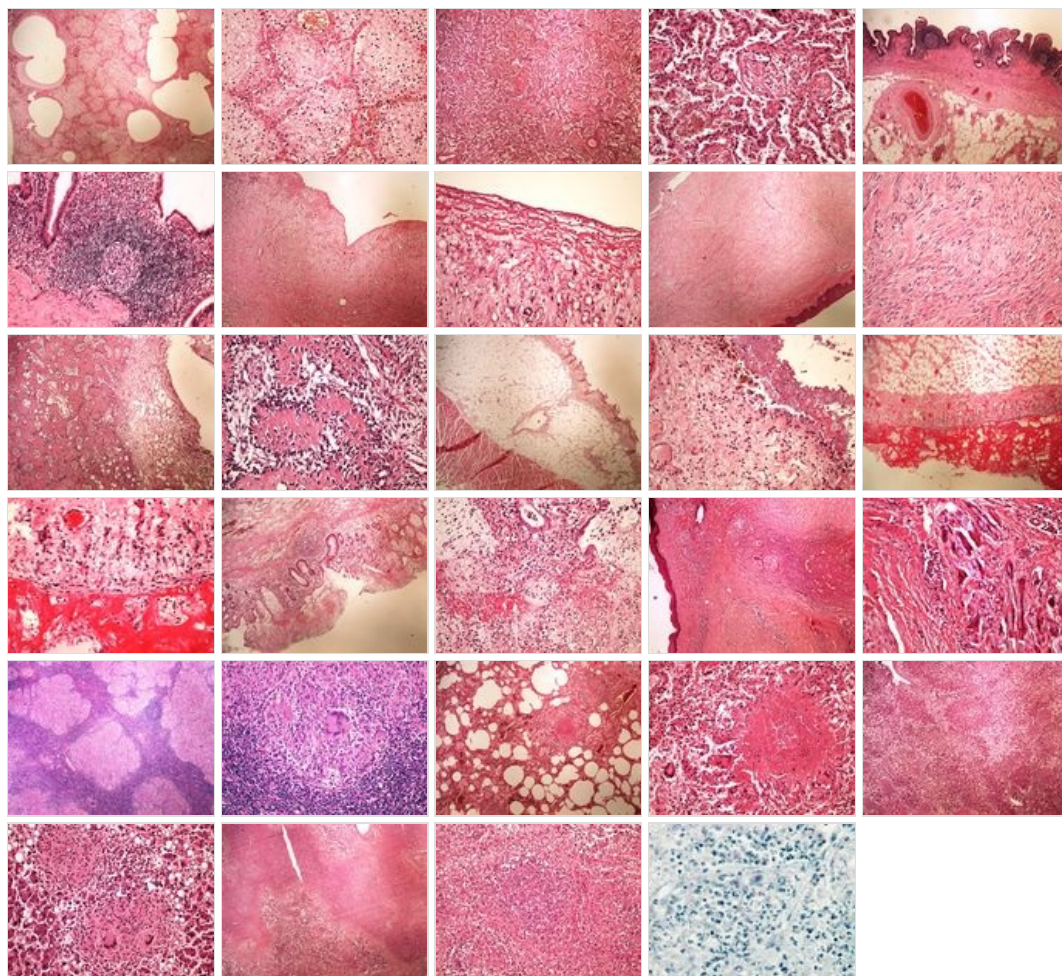
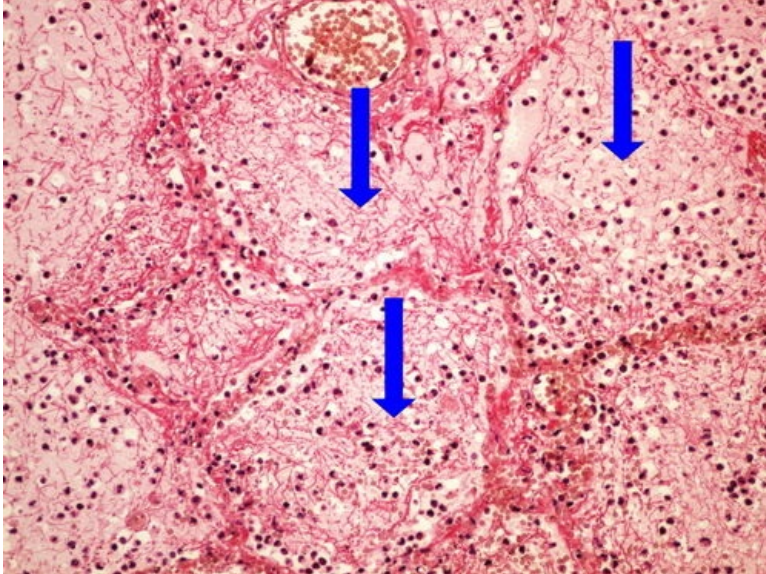
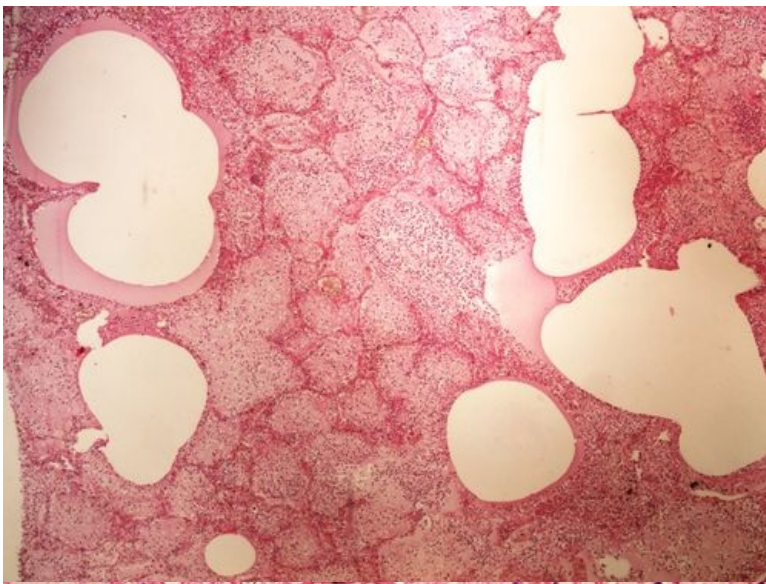


# Modul OZPP - Praktikum č. 7

## Přehled



## Preparát č.1 a č.2 - krupózní pneumonie

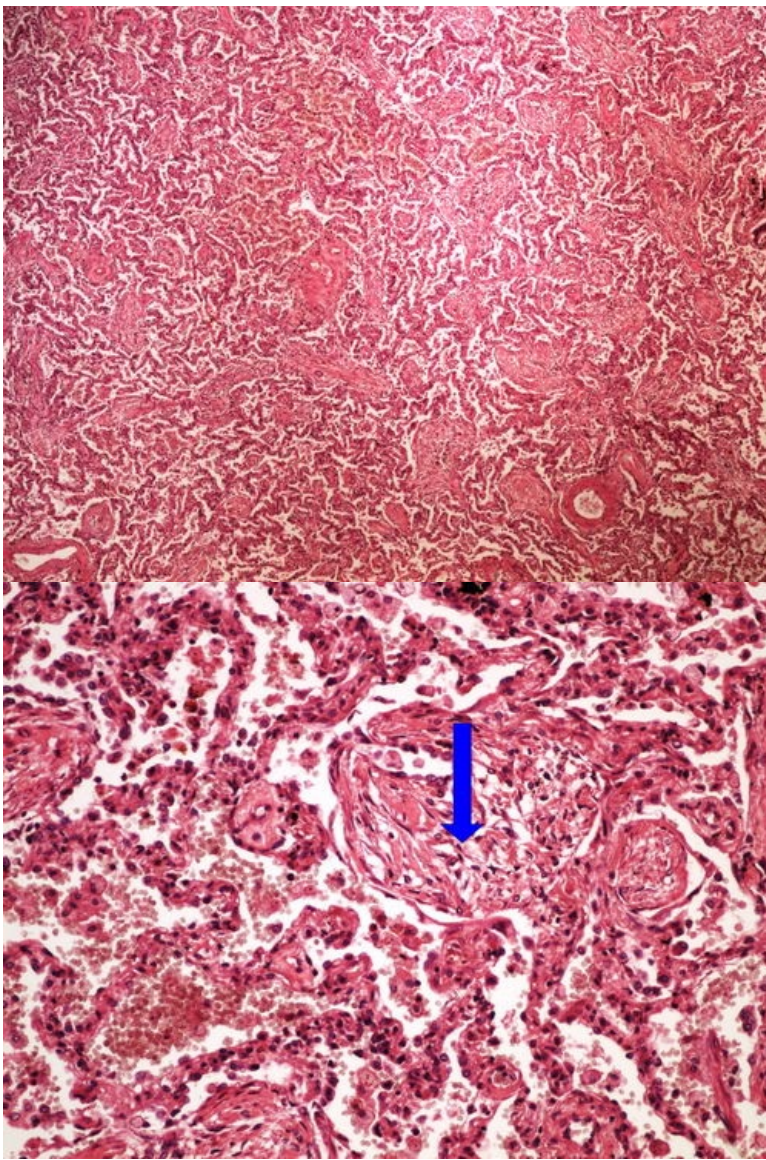


**Struktury**

[Expand]

**Preparát č.3 a č.4 - karnifikace plic**

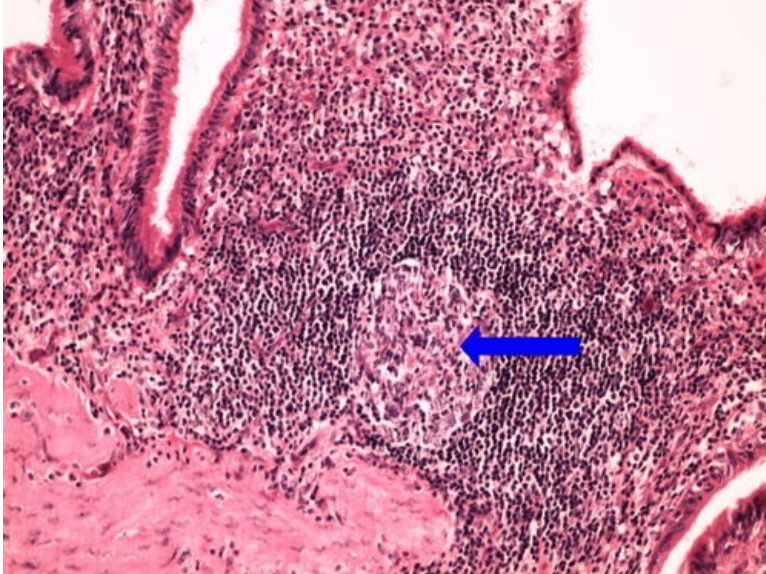
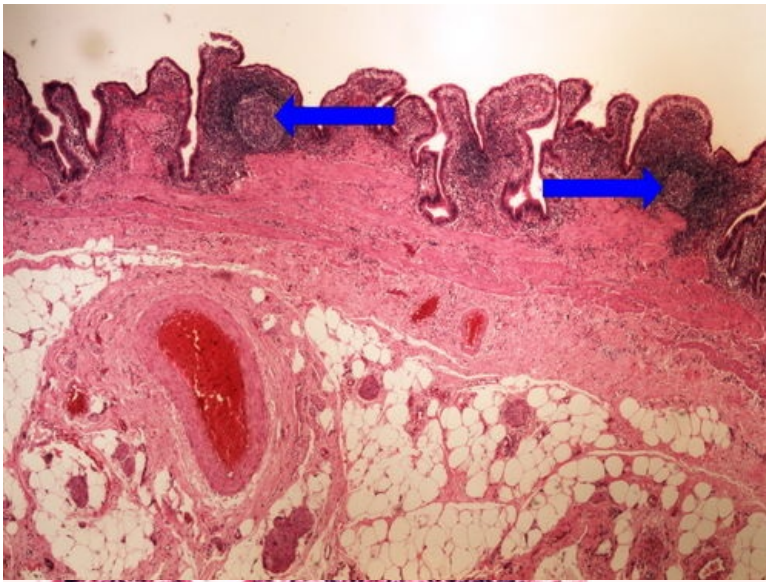




**Struktury**

[Expand]

**Preparát č.5 a č.6 - chronická cholecystitis**

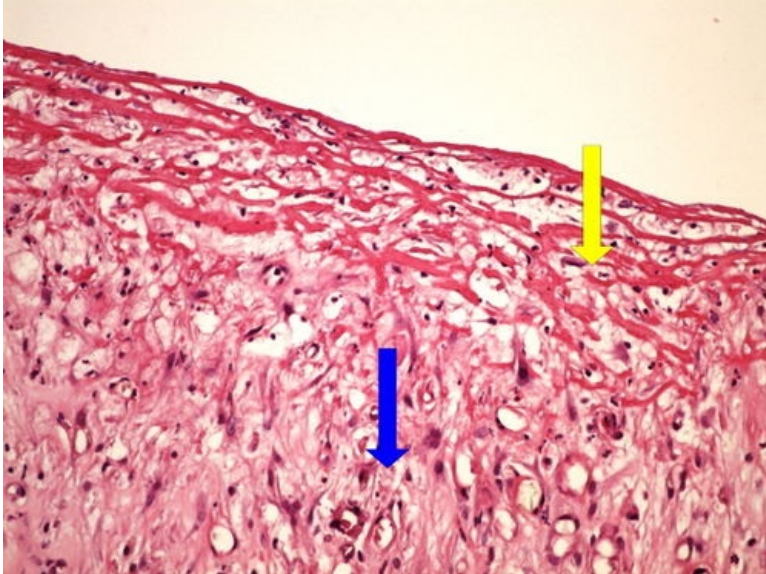
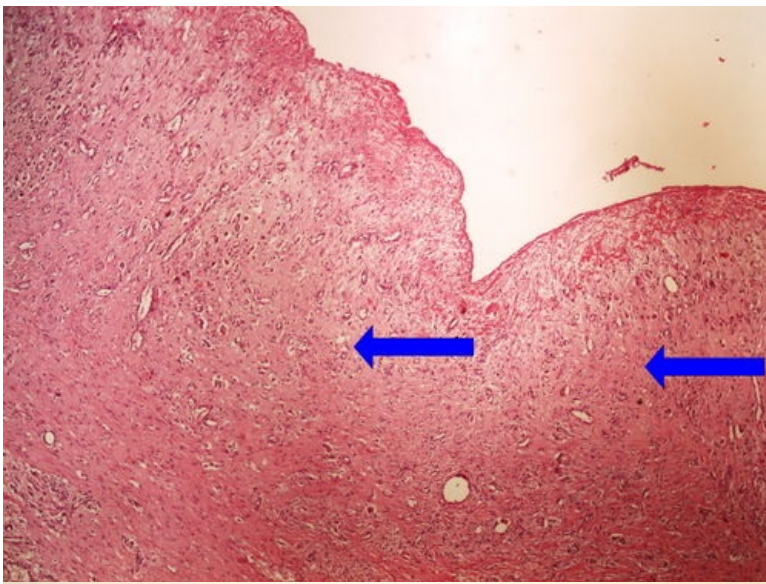


**Struktury**

[Expand]

**Preparát č.7 a č.8 - granulační tkáň spodiny bér cového vředu**

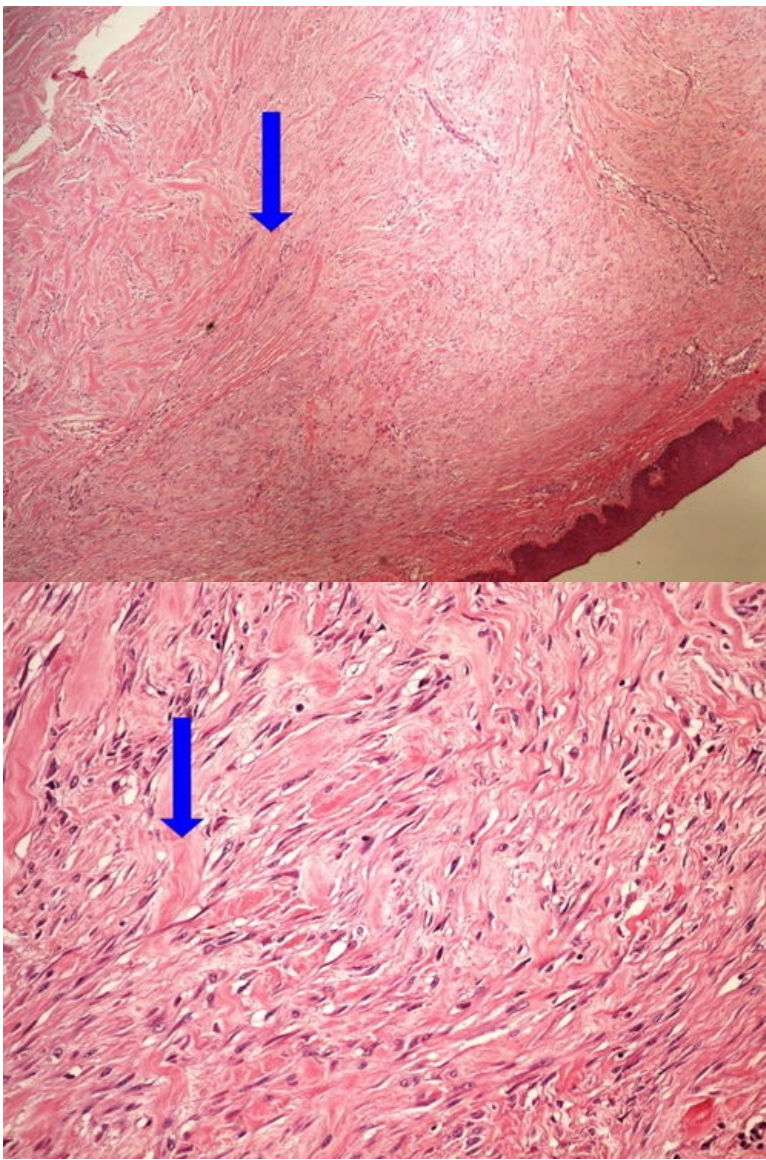




**Struktury**

[Expand]

**Preparát č.9 a č.10 - keloid**

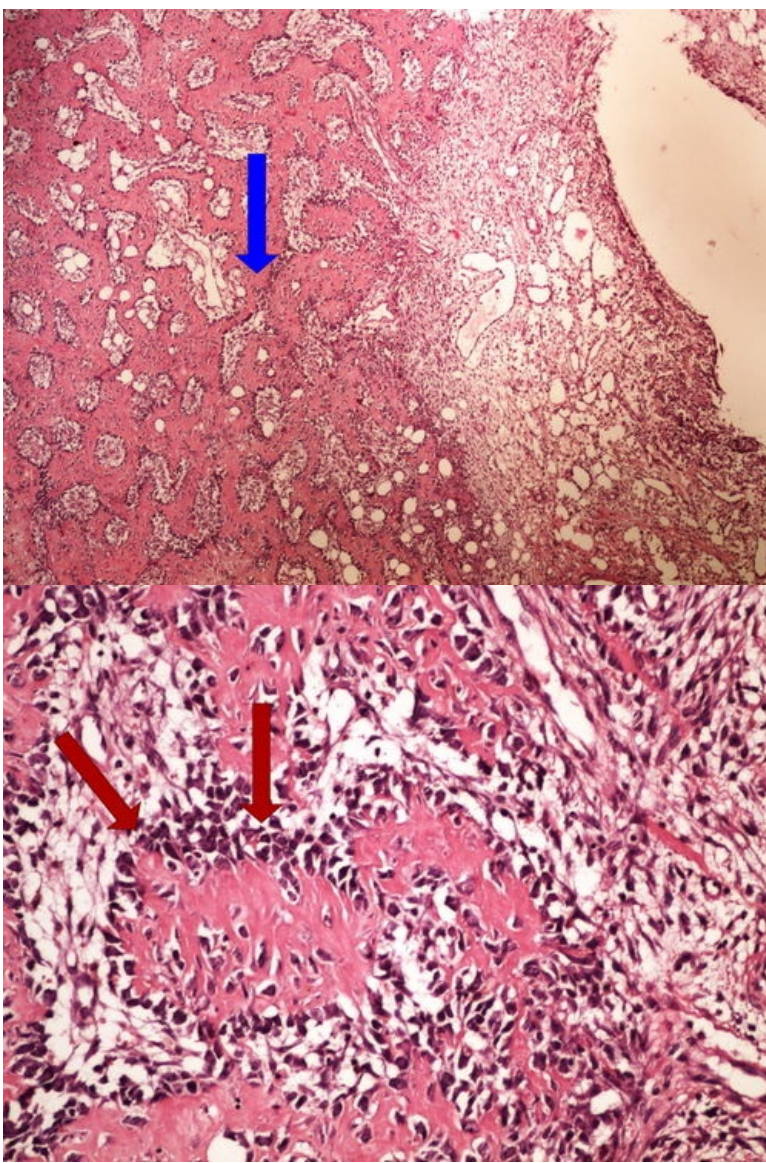


**Struktury**

[Expand]

**Preparát č.11 a č.12 - hojení kostní zlomeniny**

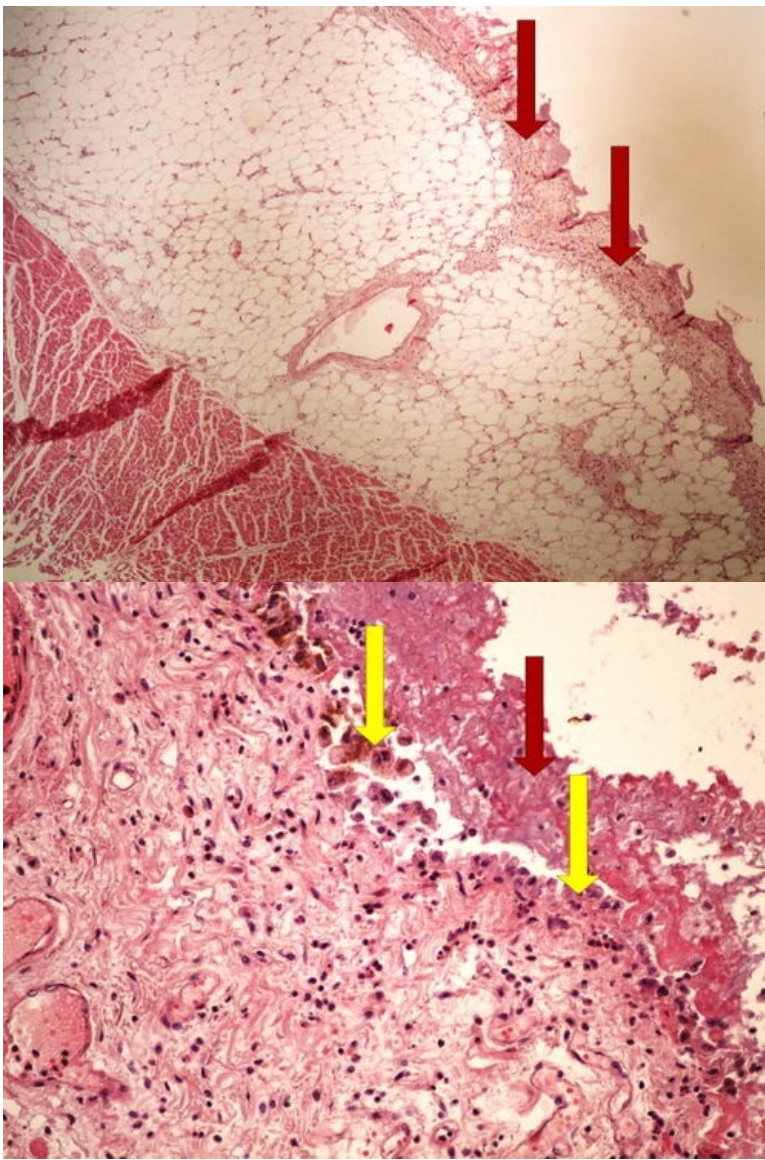




**Struktury**

[Expand]

**Preparát č.13 a č.14 - čerstvá fibrinózní perikarditis**

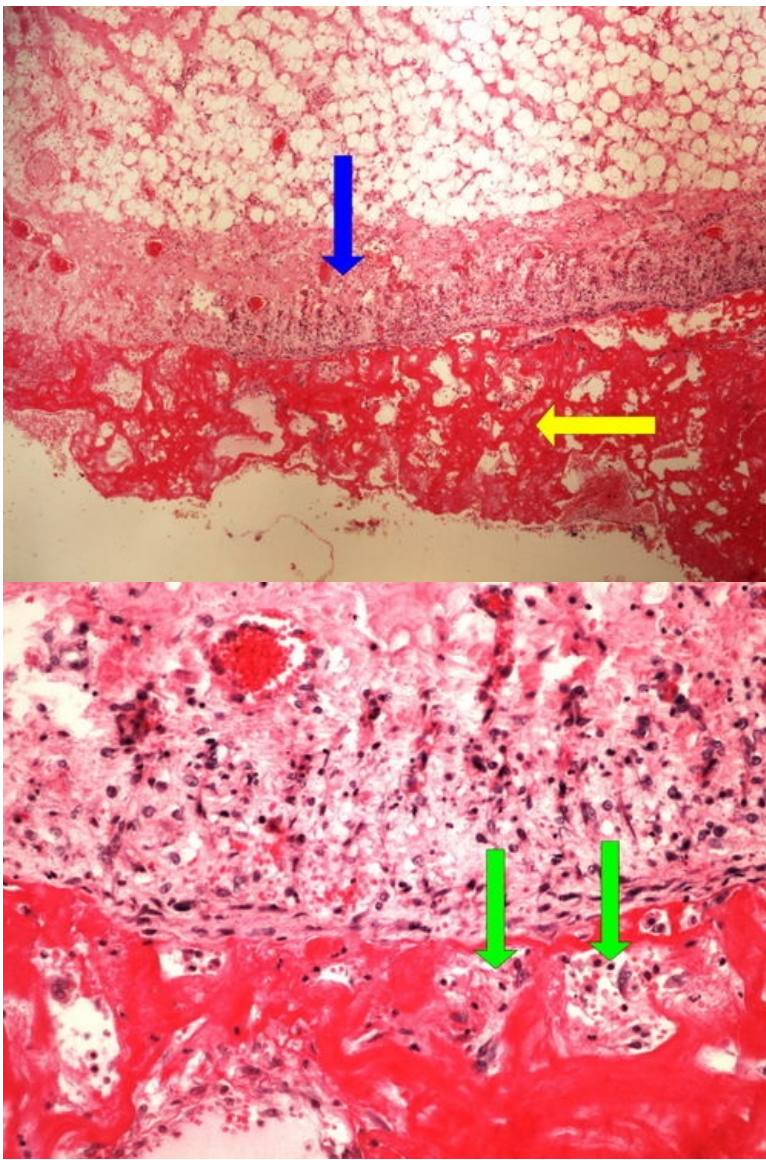


**Struktury**

[Expand]

**Preparát č.15 a č.16 - chronická fibrinózní perikarditis**

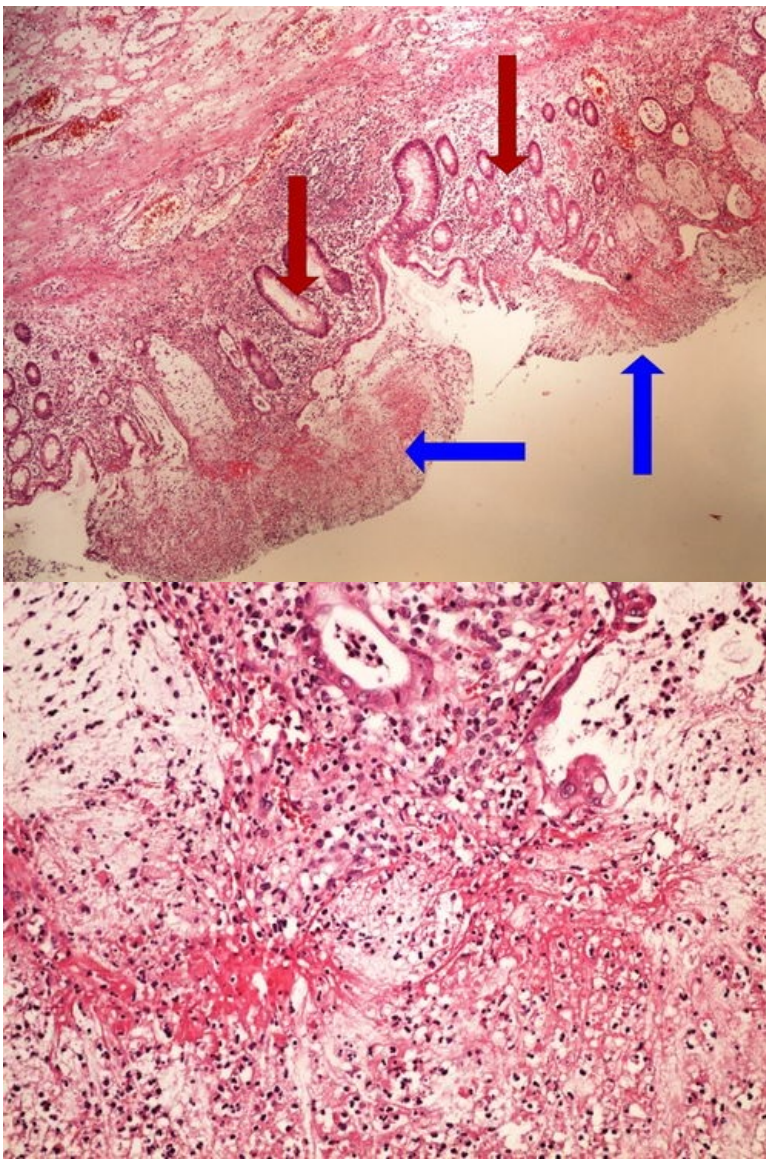




**Struktury**

[Expand]

**Preparát č.17 a č.18 - pablánová kolitis**

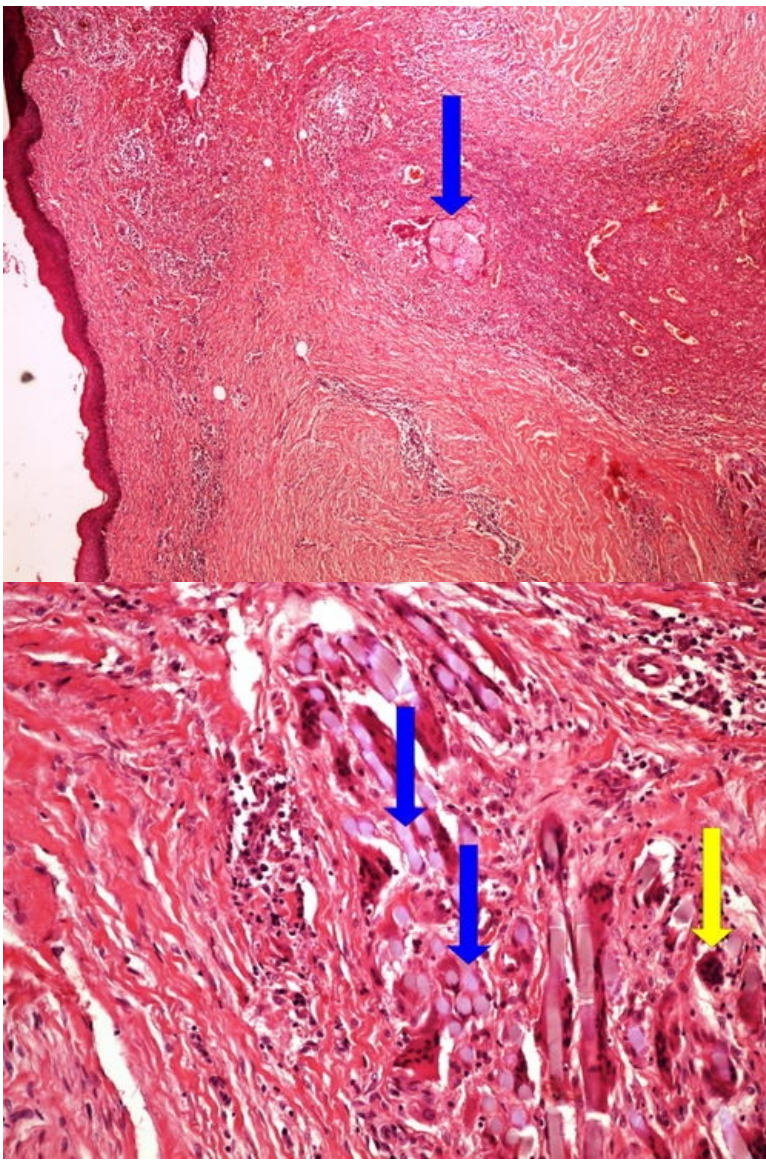


**Struktury**

[Expand]

**Preparát č.19 a č.20 - obrovskobuněčný granulom**

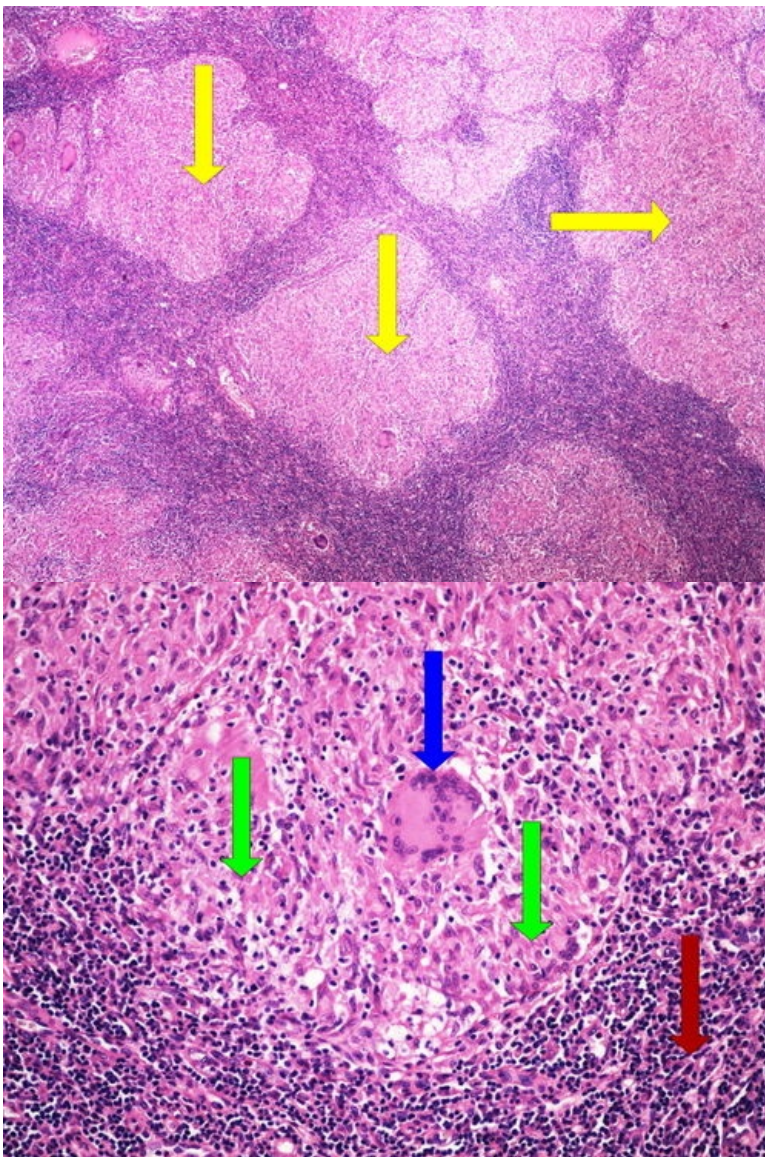




**Struktury**

[Expand]

**Preparát č.21 a č.22 - sarkoidóza**

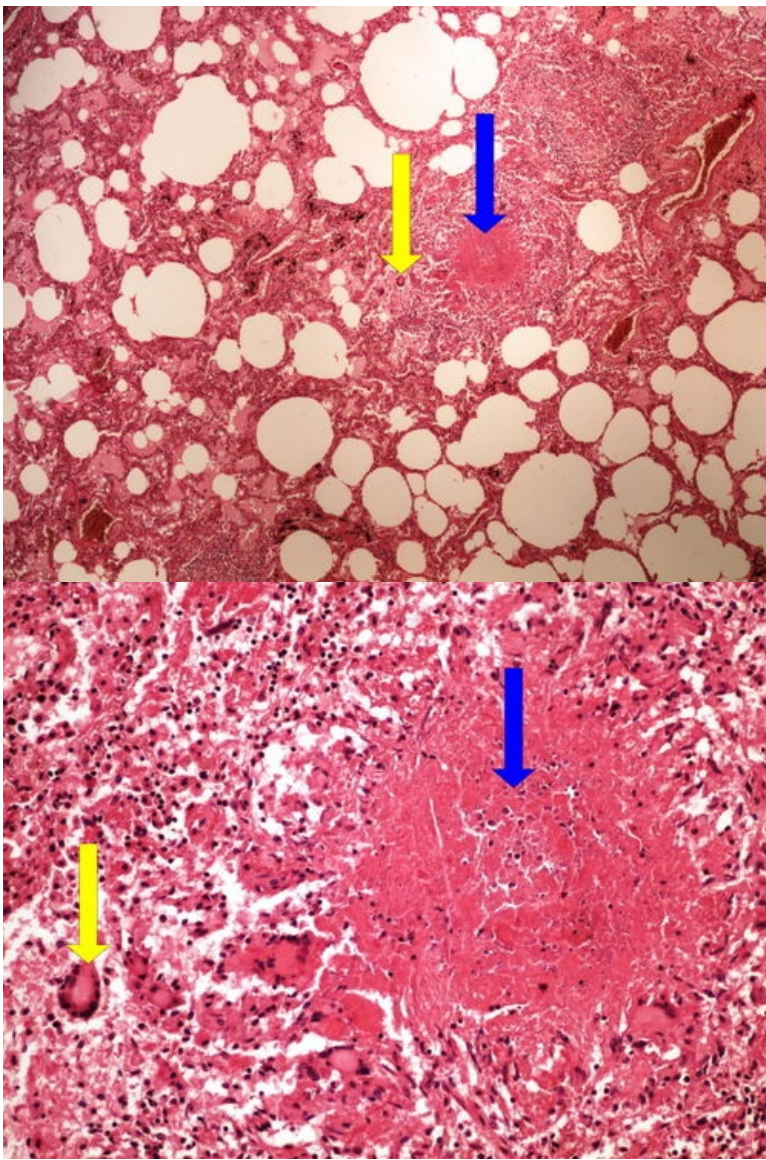


**Struktury**

[Expand]

**Preparát č.23 a č.24 - miliární TBC plic**

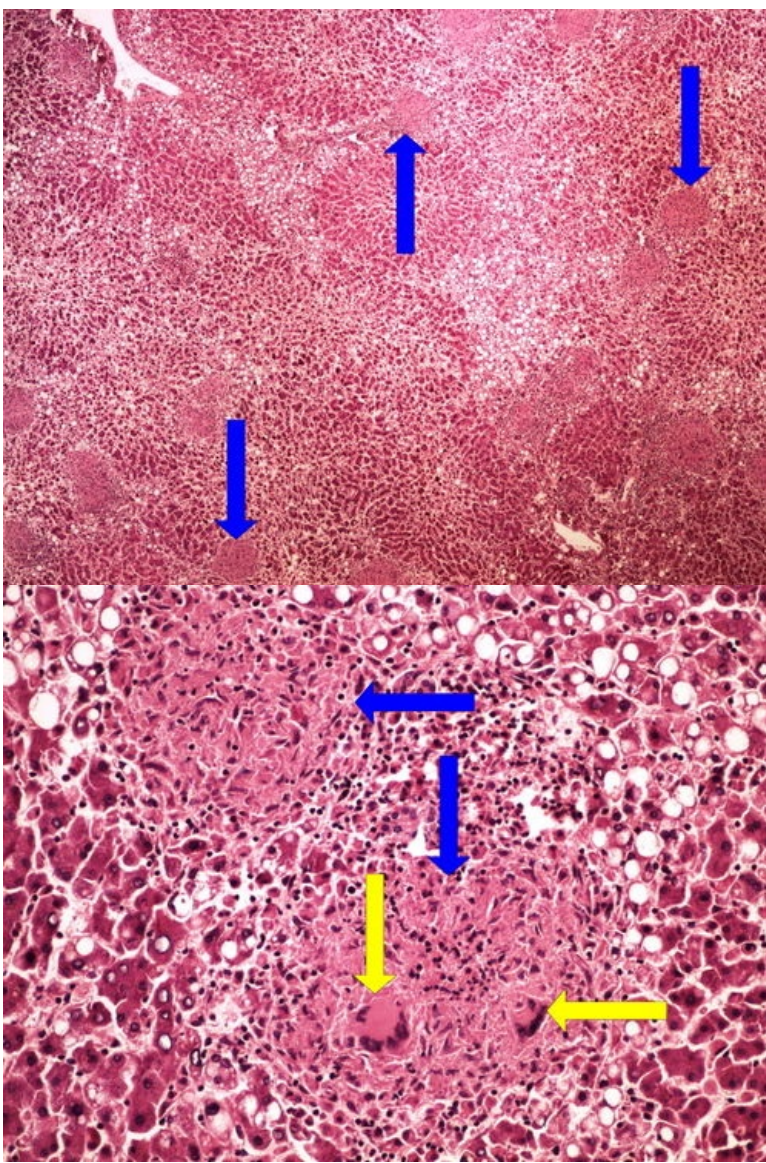




**Struktury**

[Expand]

**Preparát č.25 a č.26 - miliární TBC jater**

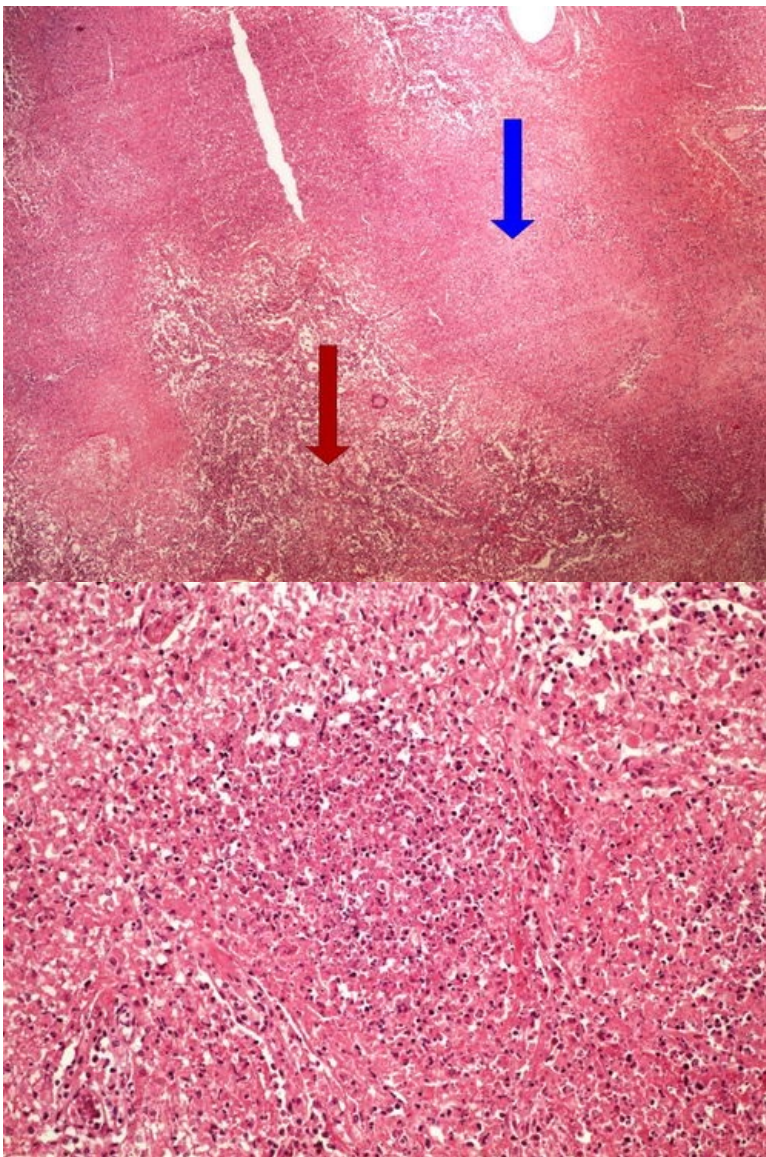


**Struktury**

[Expand]

**Preparát č.27 a č.28 - kaseózní pneumonie**

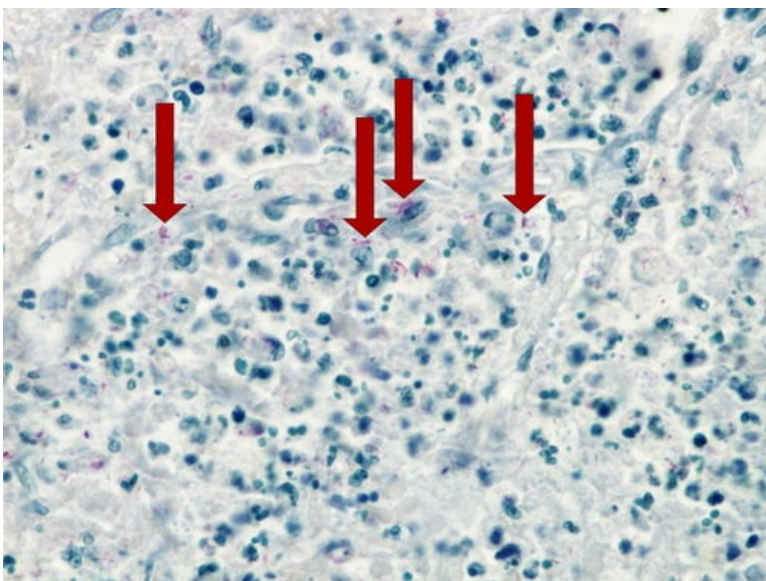




**Struktury**

[Expand]

## Preparát č.29 - kaseózní pneumonie (Ziehl Nielsen)



**Struktury**

[Expand]

**Odkazy**

**Navigace**

