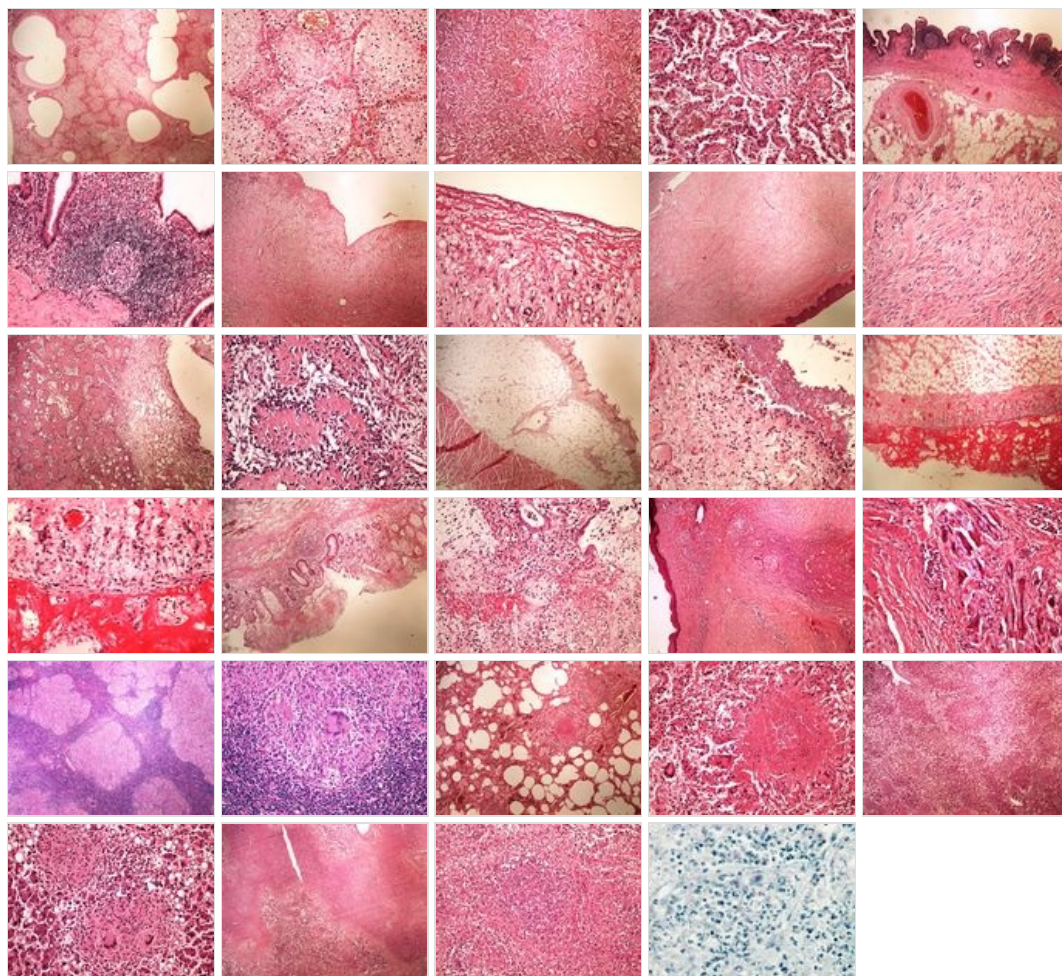
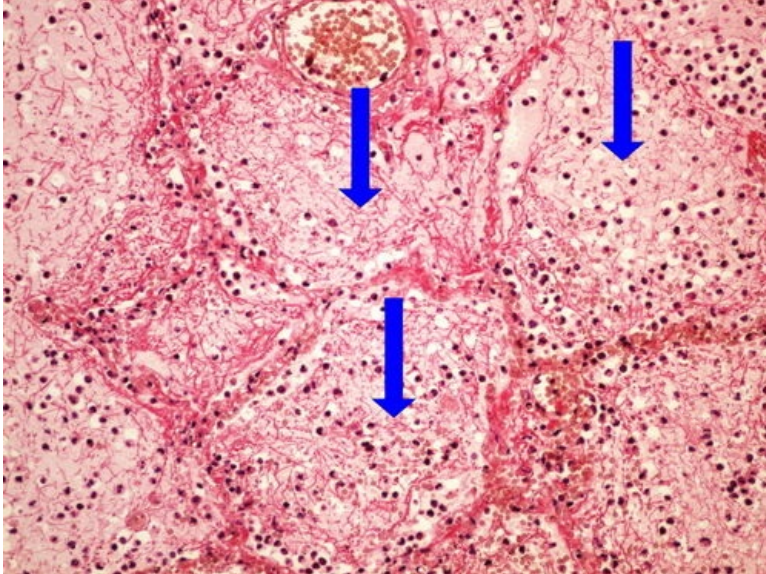
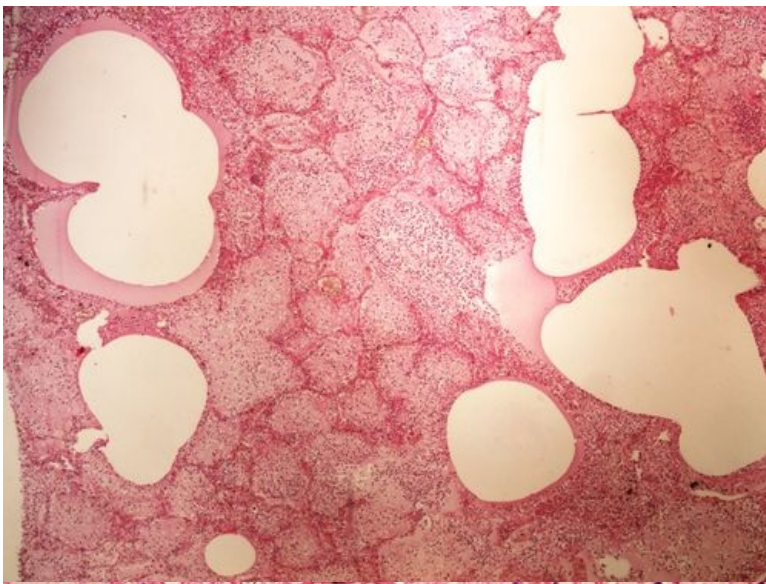


Modul OZPP - Praktikum č. 7 (zoom)

Přehled



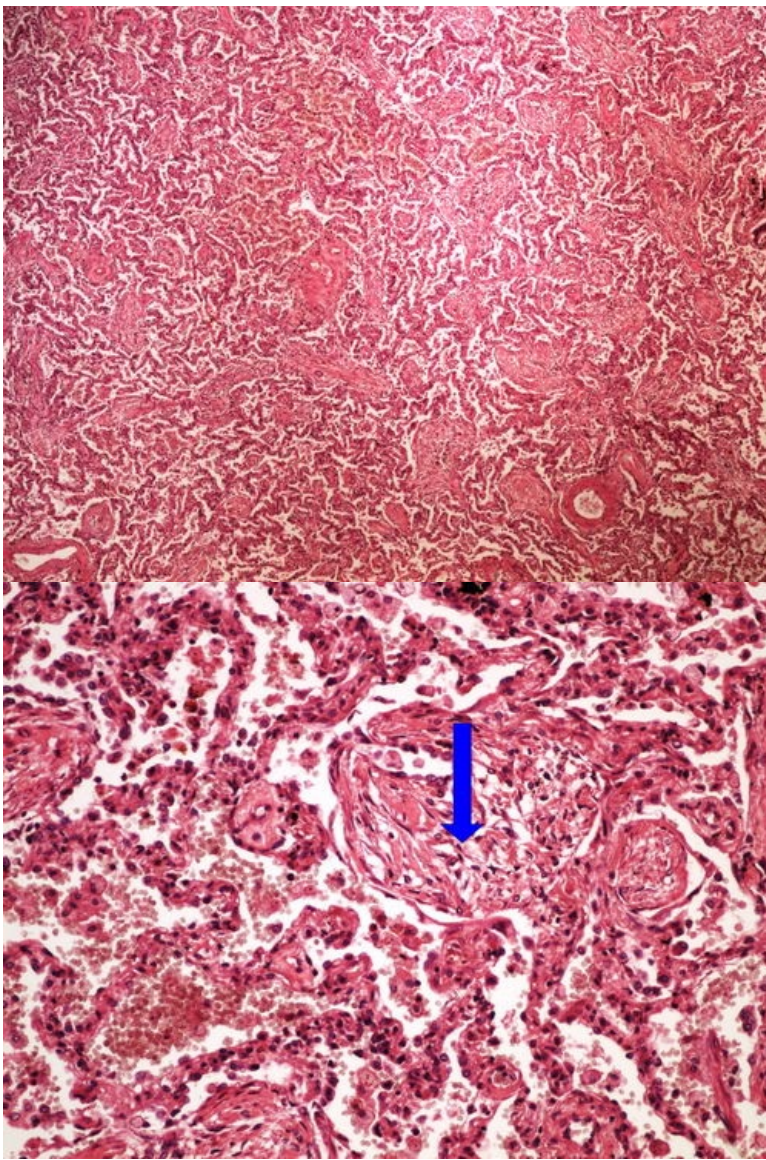
Preparát č.1 a č.2 - krupózní pneumonie



Struktury

[Expand]

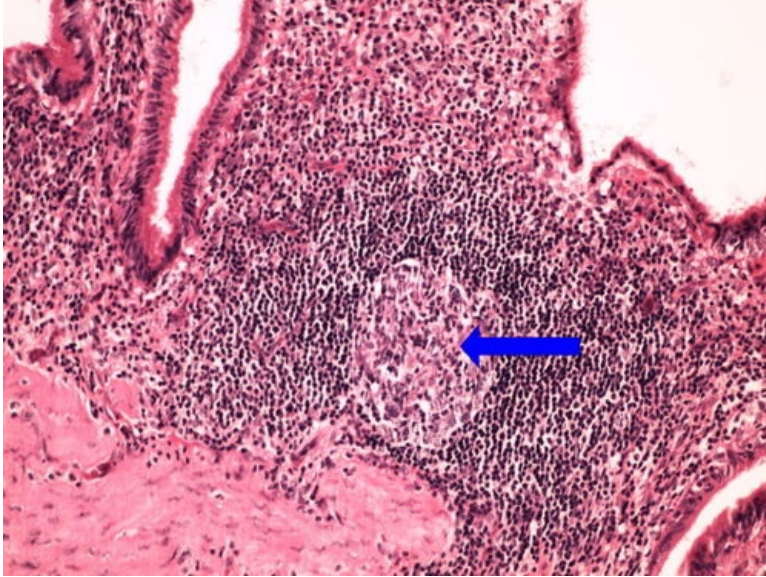
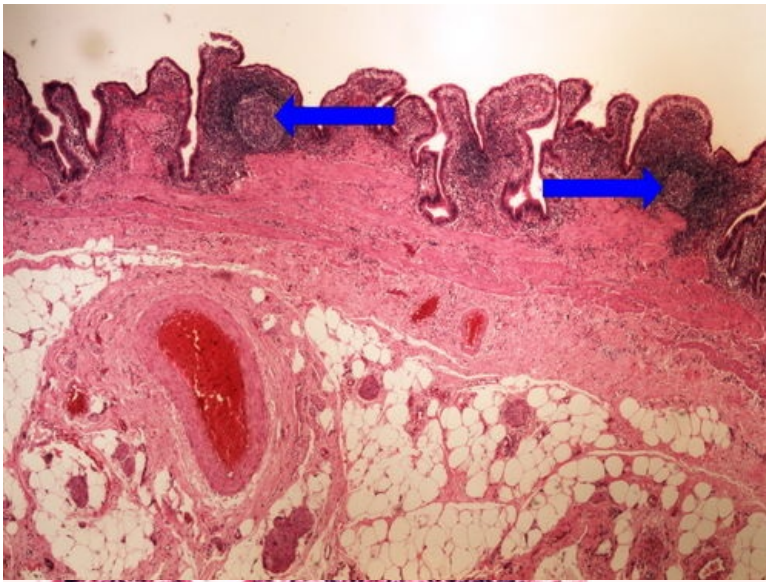
Preparát č.3 a č.4 - karnifikace plic



Struktury

[\[Expand\]](#)

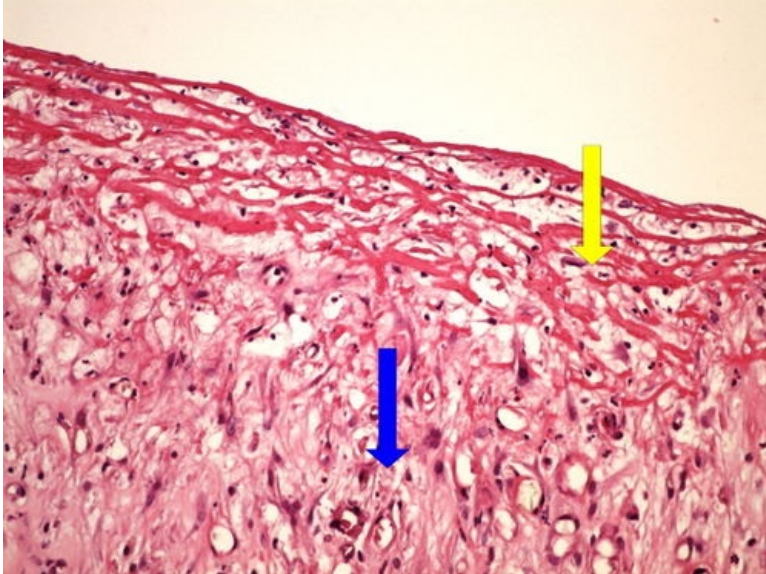
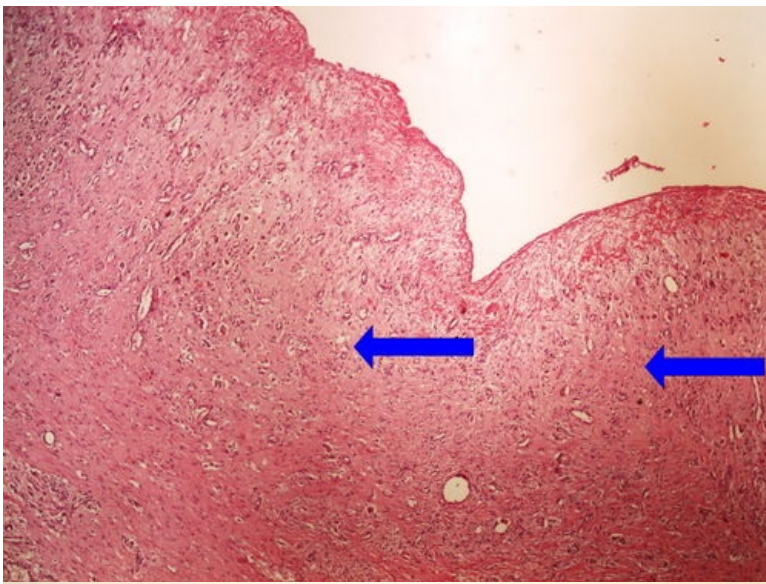
Preparát č.5 a č.6 - chronická cholecystitis



Struktury

[Expand]

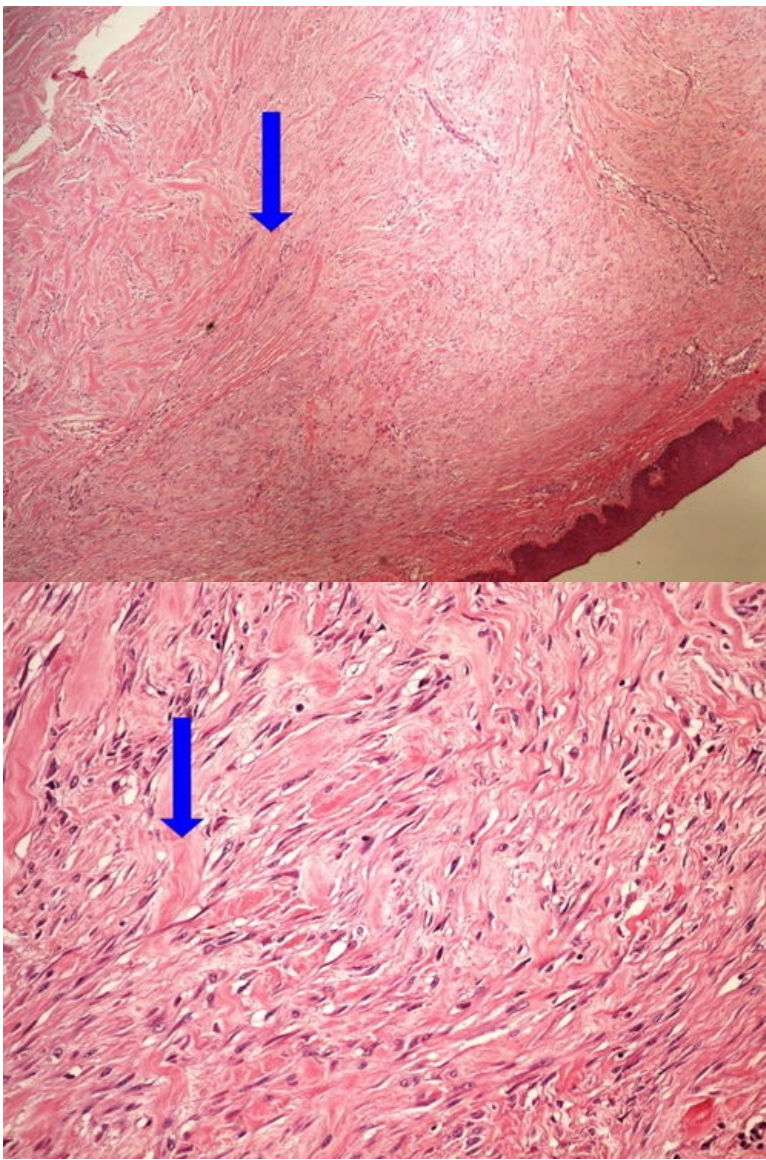
Preparát č.7 a č.8 - granulační tkáň spodiny bércového vředu



Struktury

[Expand]

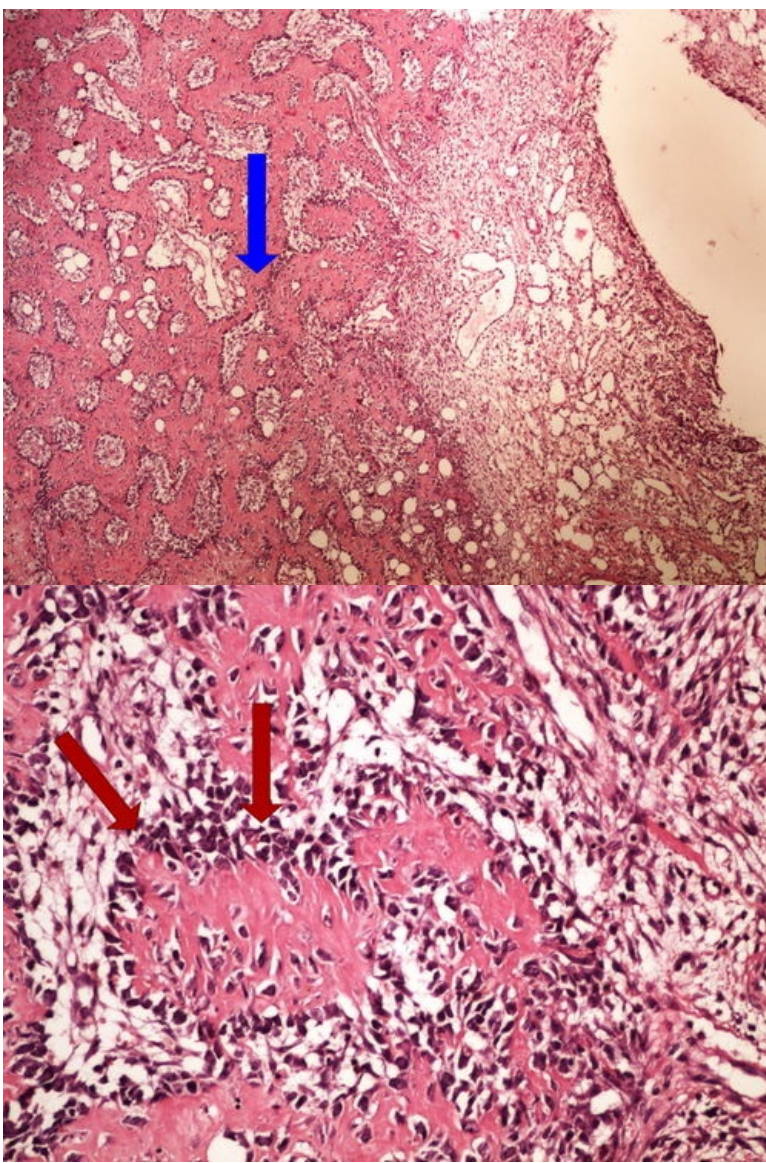
Preparát č.9 a č.10 - keloid



Struktury

[Expand]

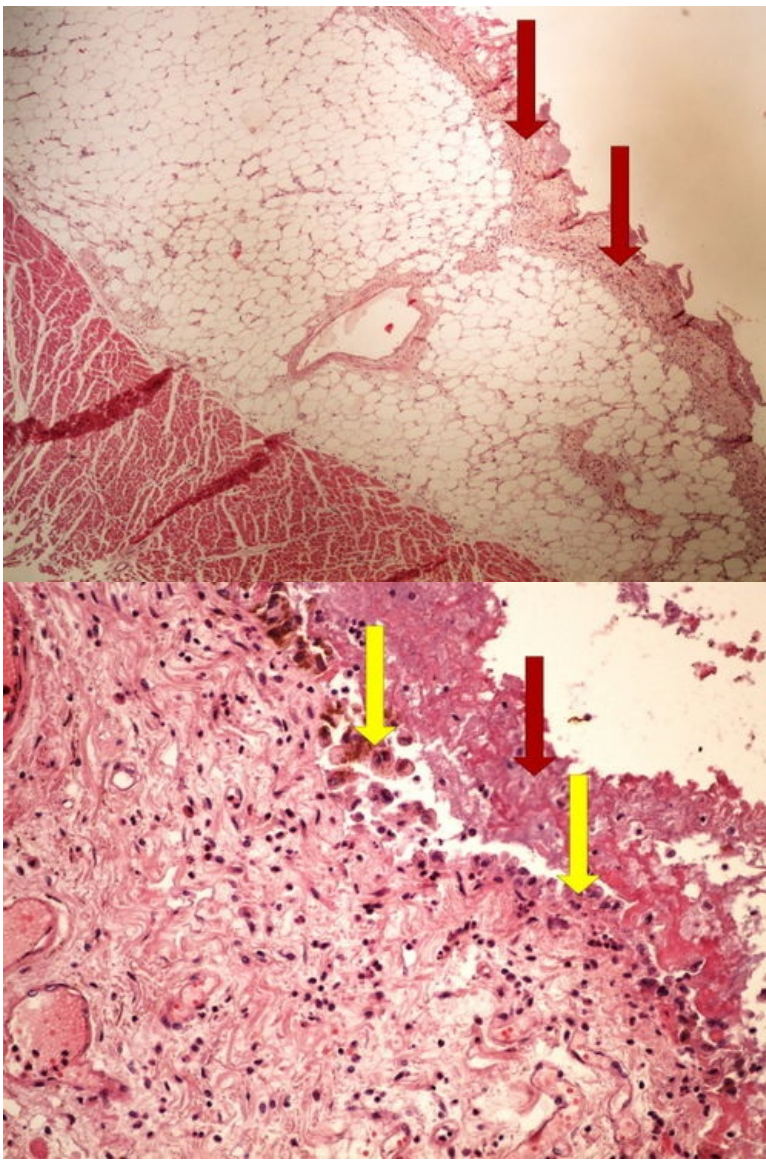
Preparát č.11 a č.12 - hojení kostní zlomeniny



Struktury

[Expand]

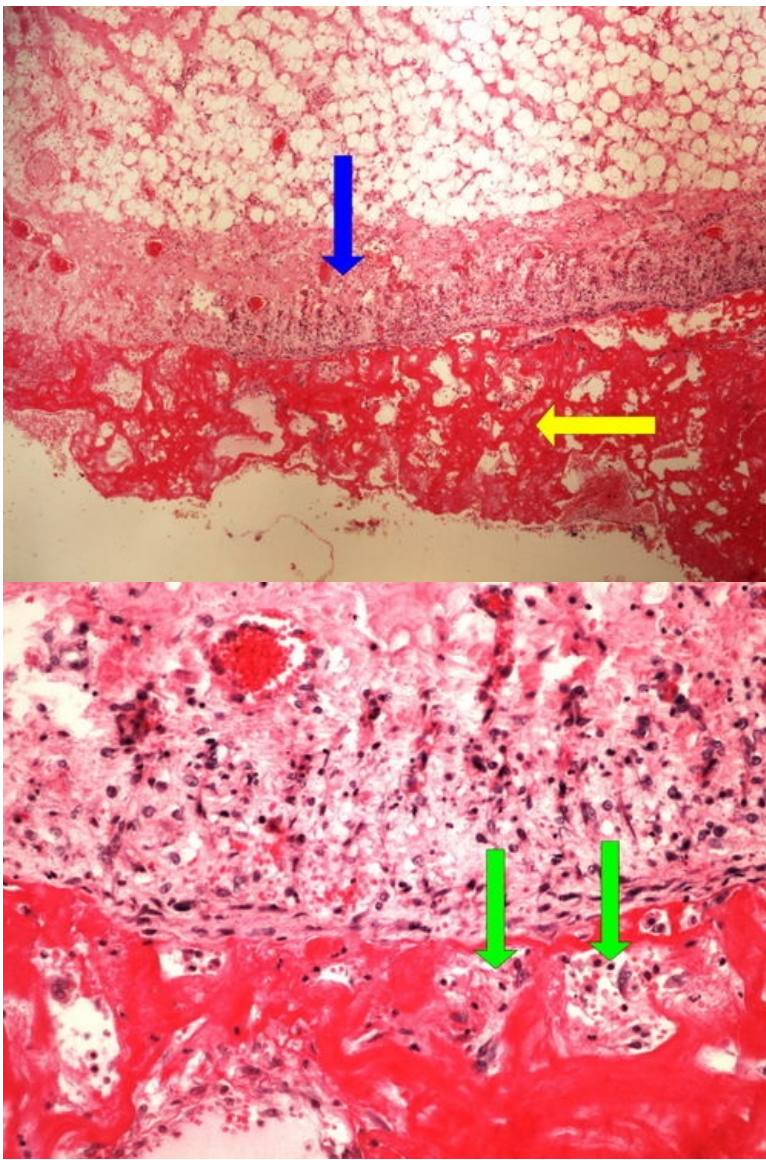
Preparát č.13 a č.14 - čerstvá fibrinózní perikarditis



Struktury

[Expand]

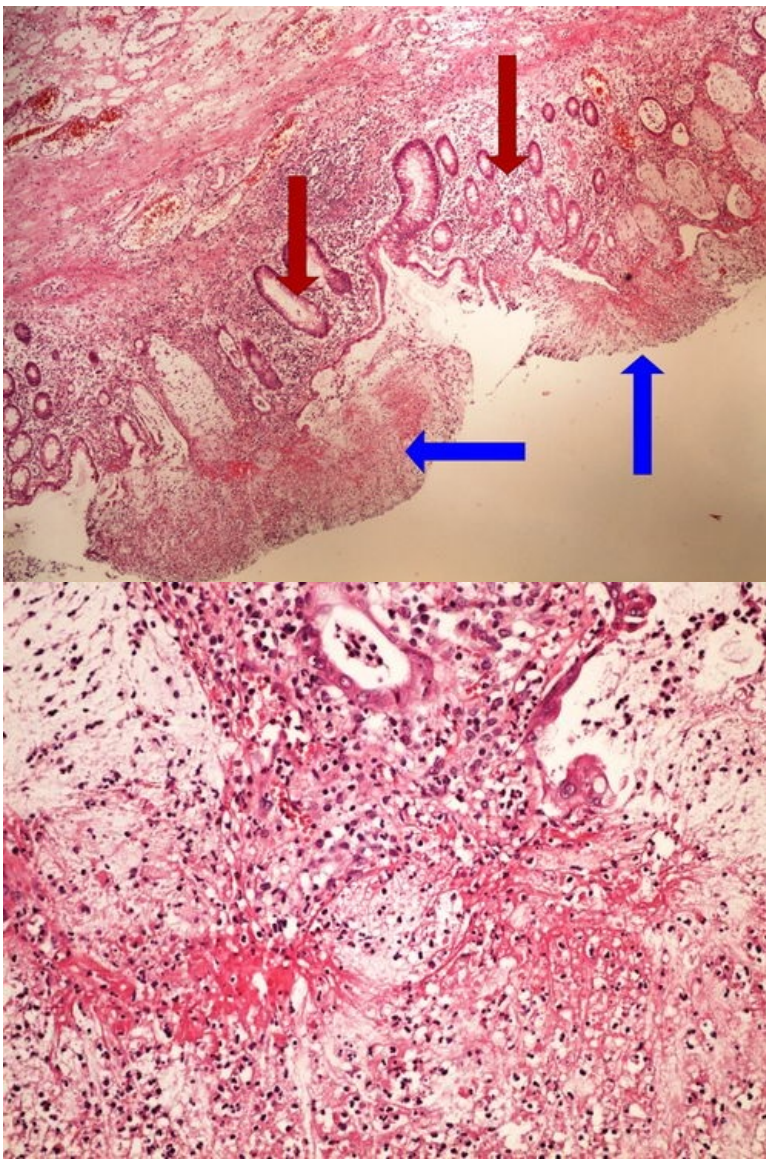
Preparát č.15 a č.16 - chronická fibrinózní perikarditis



Struktury

[Expand]

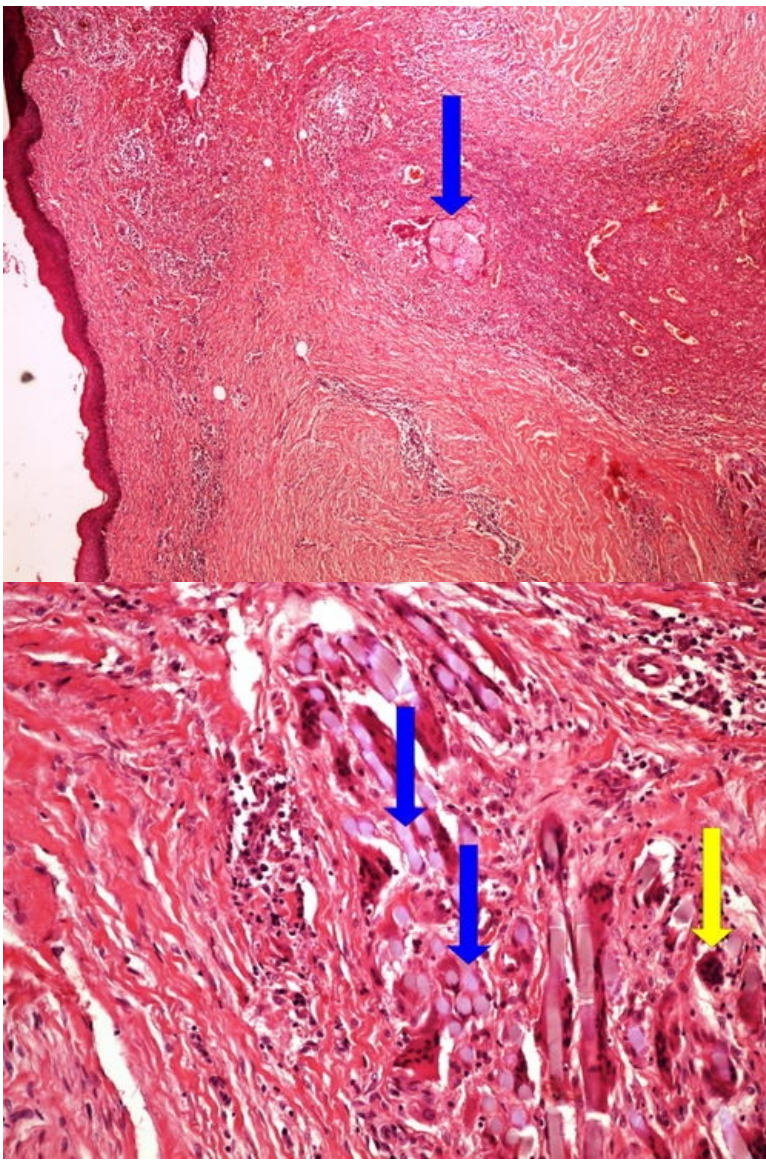
Preparát č.17 a č.18 - pablánová kolitis



Struktury

[Expand]

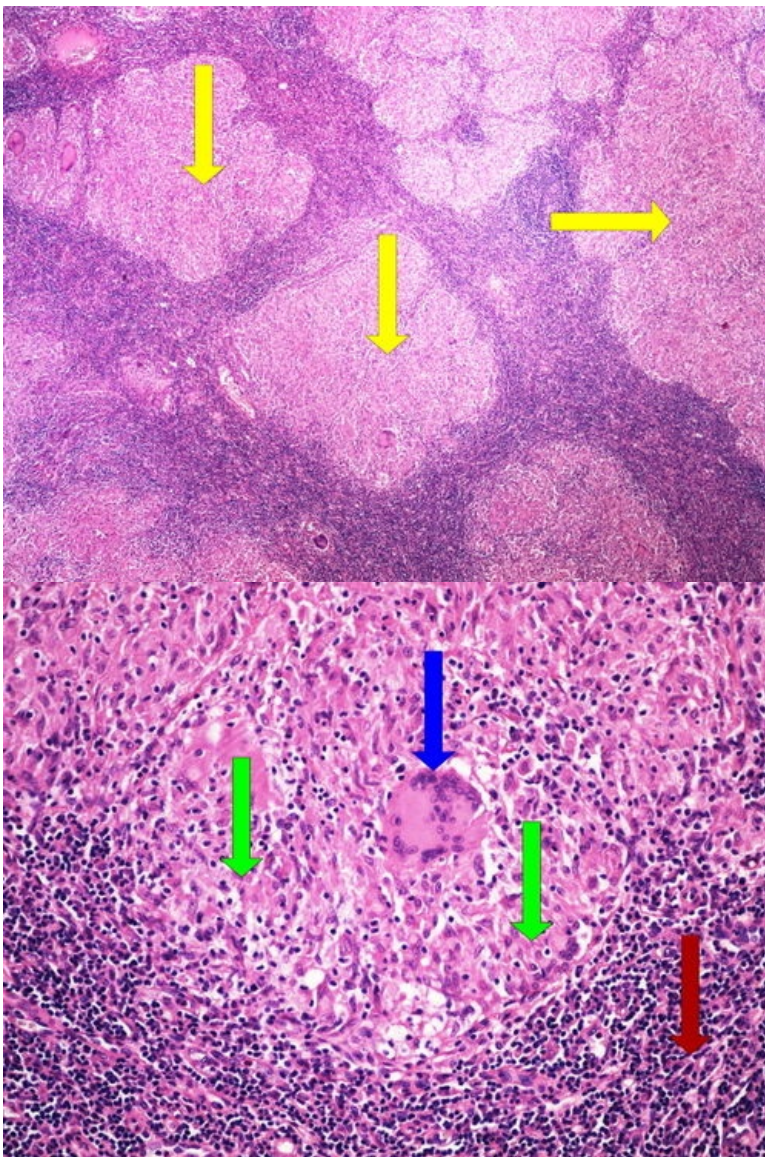
Preparát č.19 a č.20 - obrovskobuněčný granulom



Struktury

[Expand]

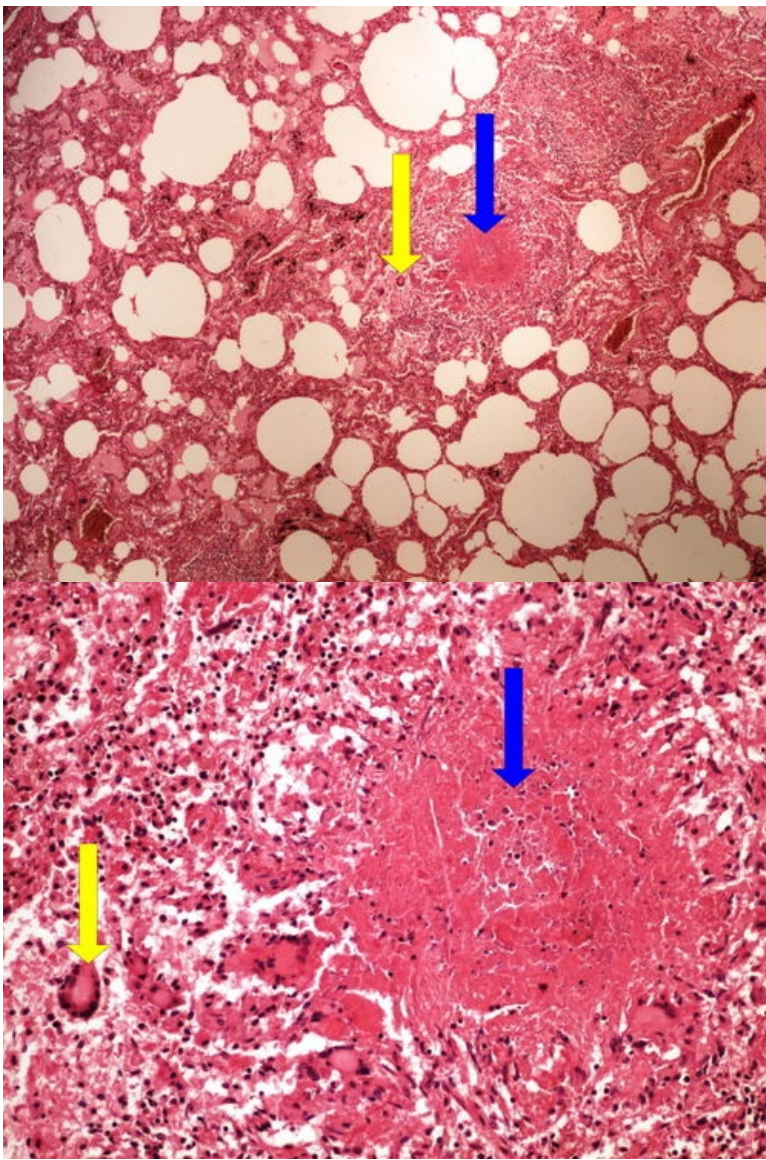
Preparát č.21 a č.22 - sarkoidóza



Struktury

[Expand]

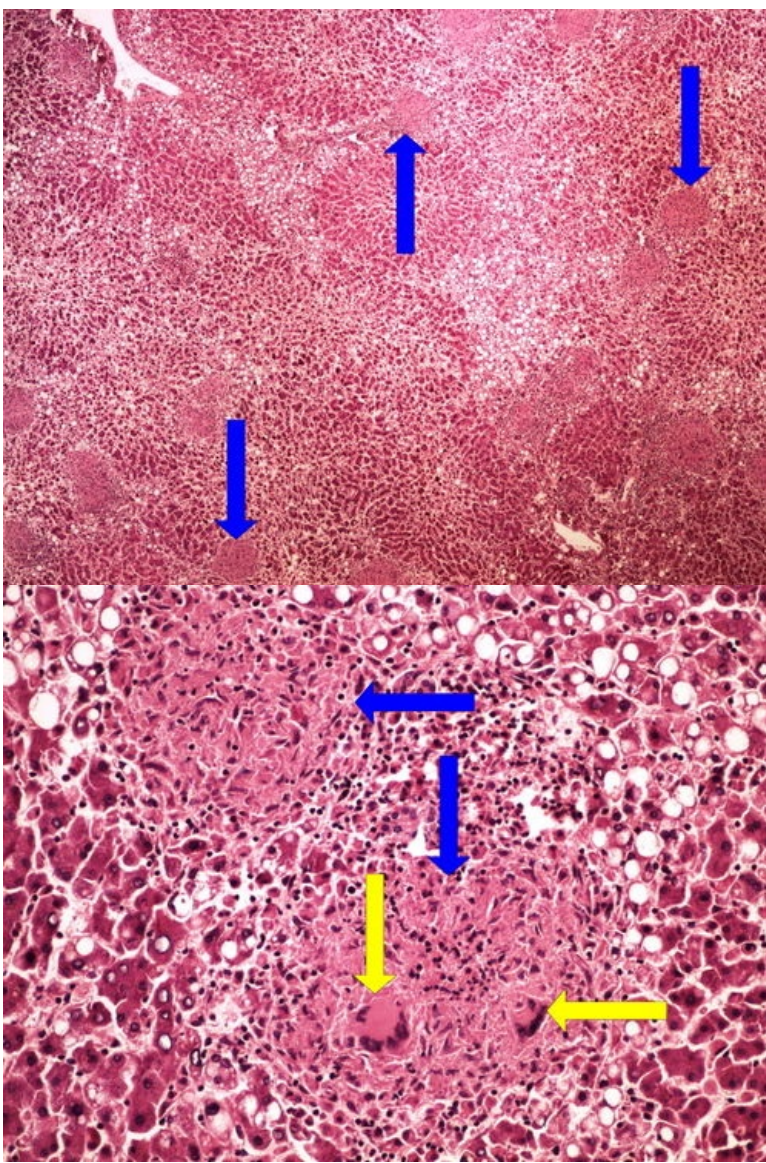
Preparát č.23 a č.24 - miliární TBC plic



Struktury

[Expand]

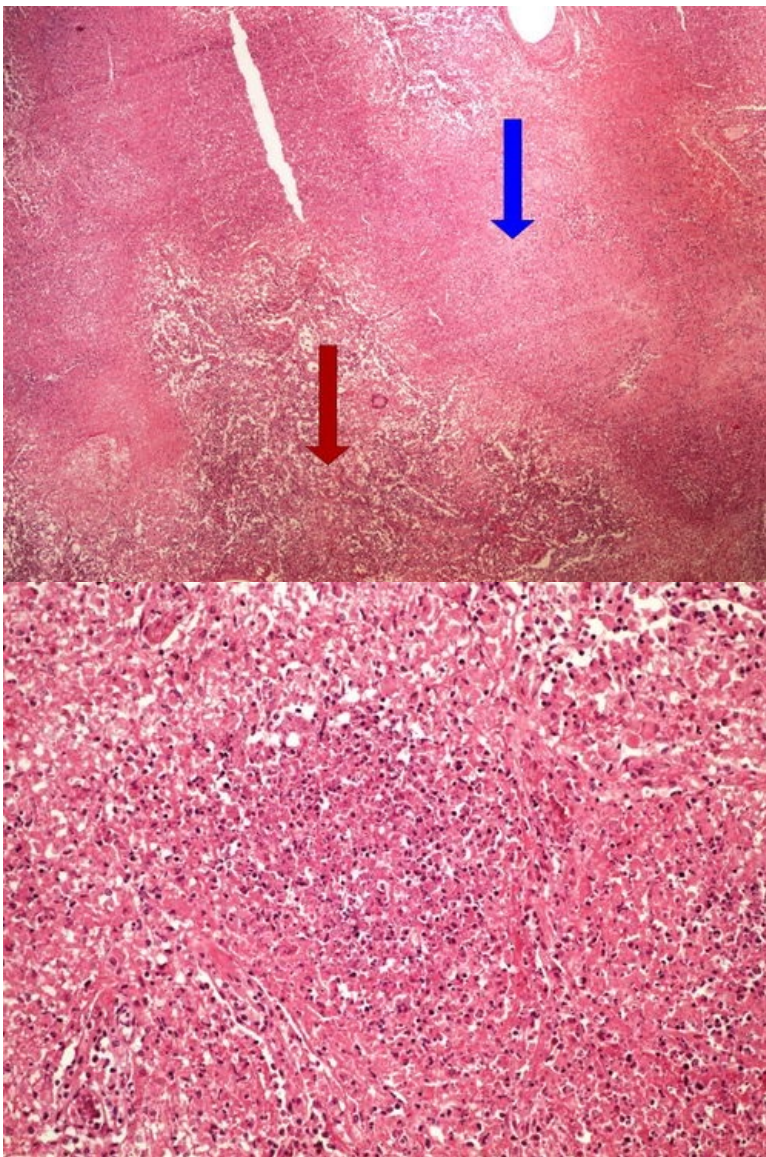
Preparát č.25 a č.26 - miliární TBC jater



Struktury

[Expand]

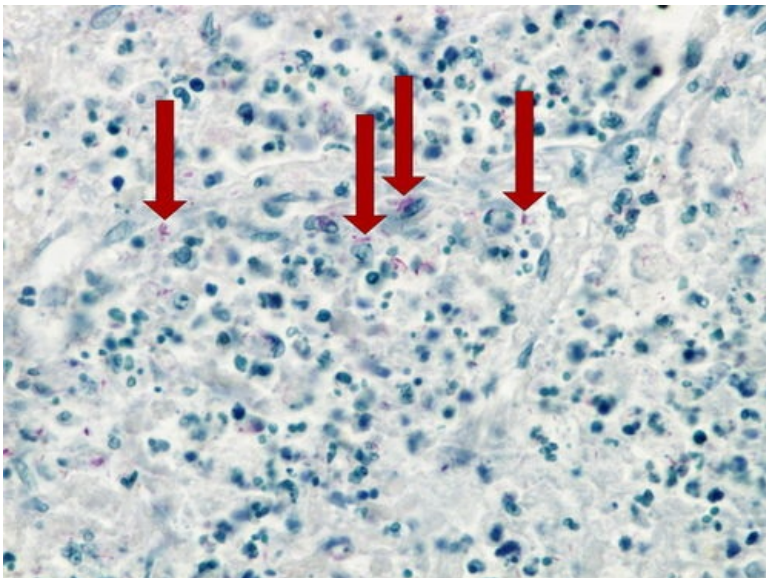
Preparát č.27 a č.28 - kaseózní pneumonie



Struktury

[Expand]

Preparát č.29 - kaseózní pneumonie (Ziehl Nielsen)



Struktury

[Expand]

Odkazy

Navigace

