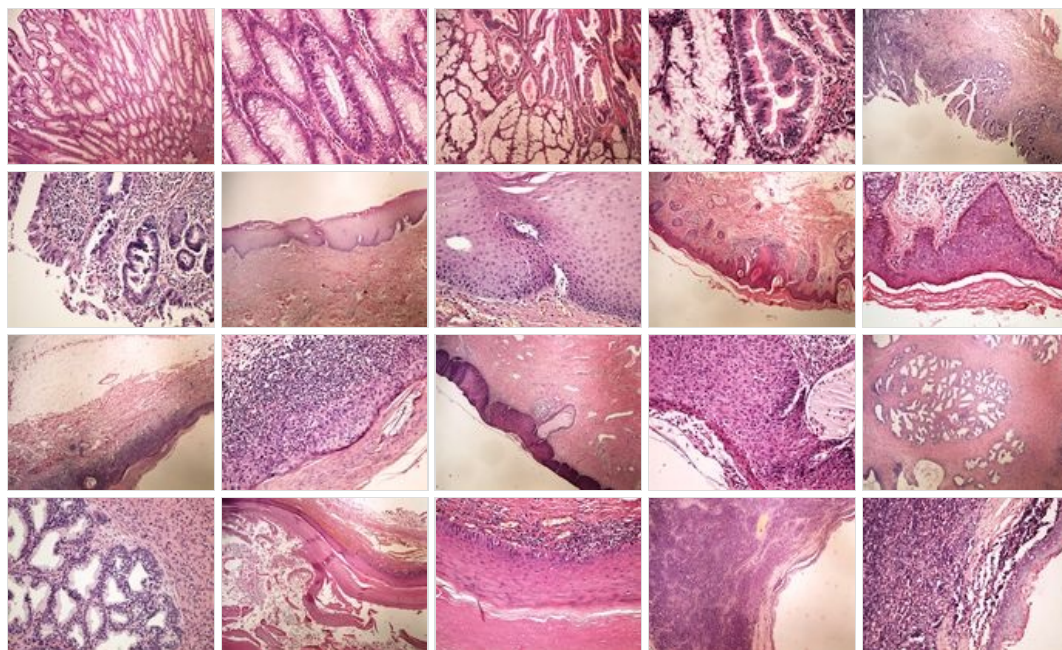
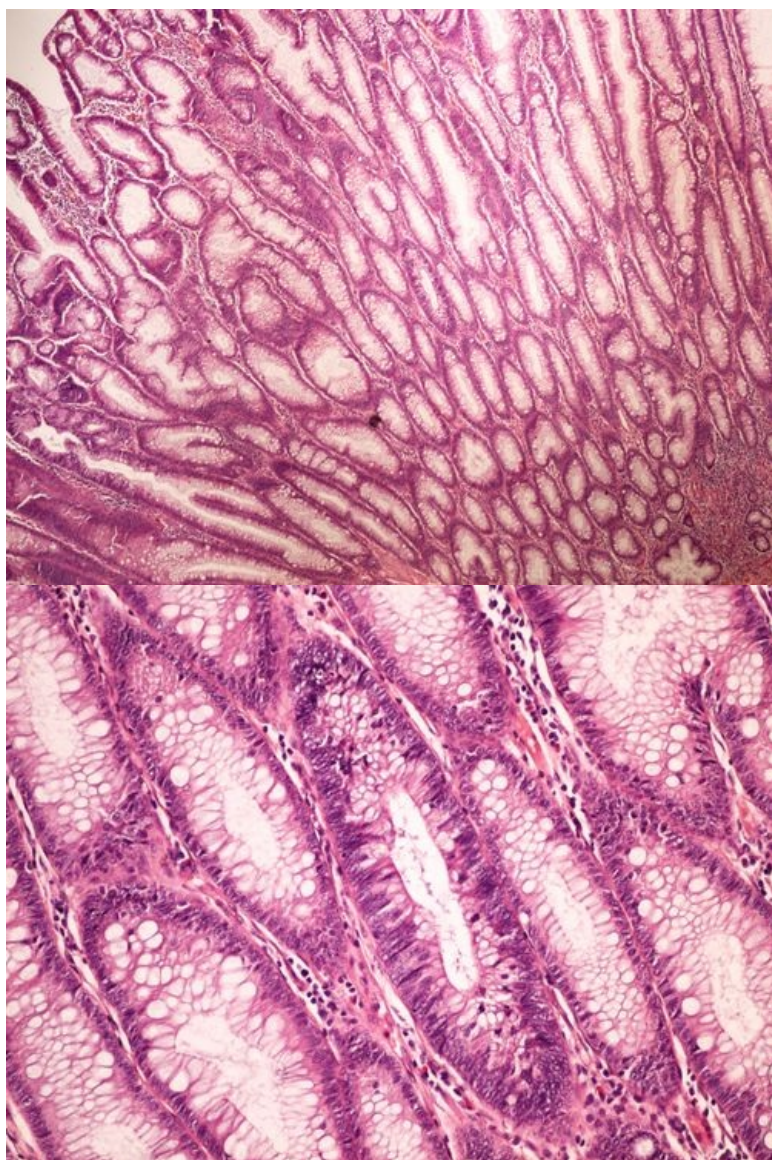


Modul OZPP - Praktikum č. 9 (zoom)

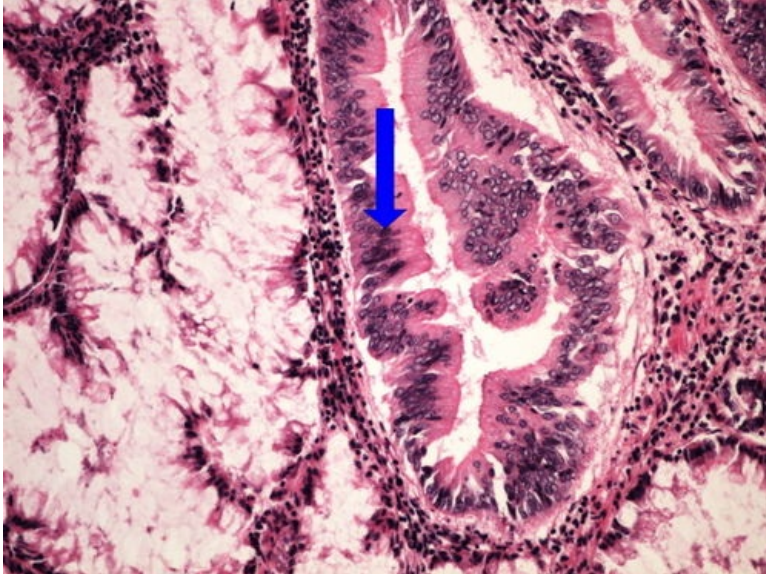
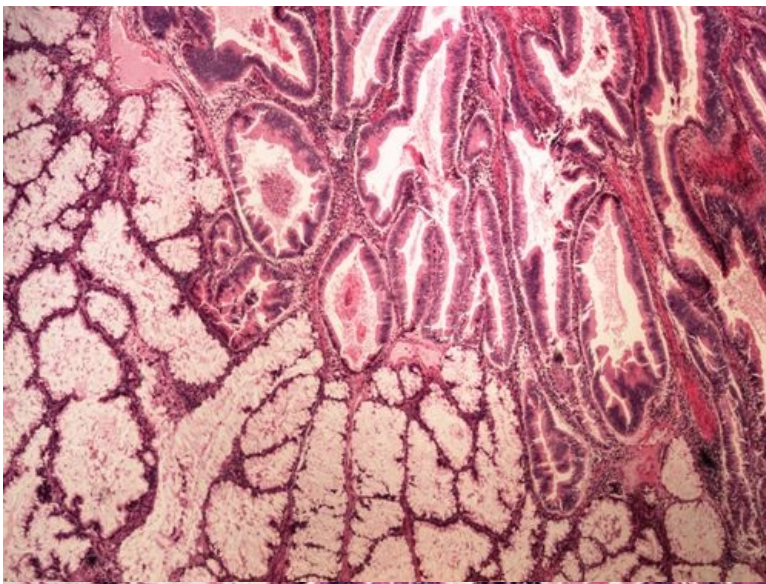
Přehled



Preparát č.1 a č.2 - tubulovilózní adenom tlustého střeva



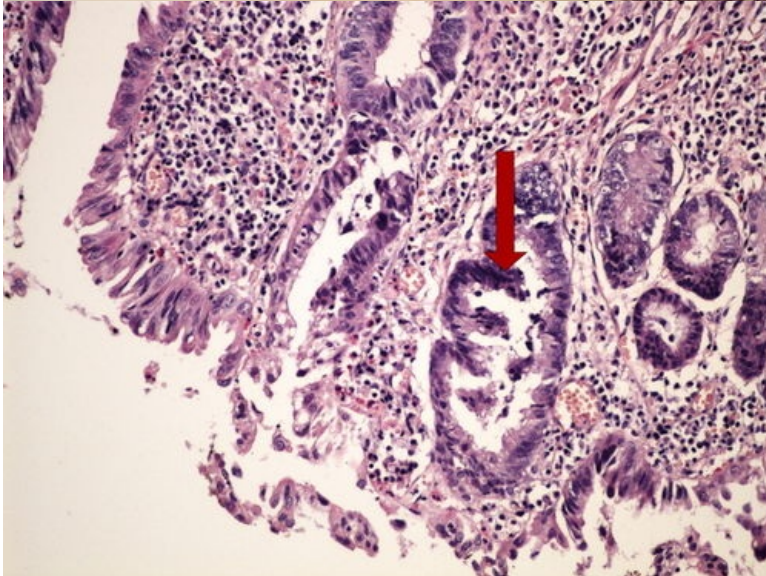
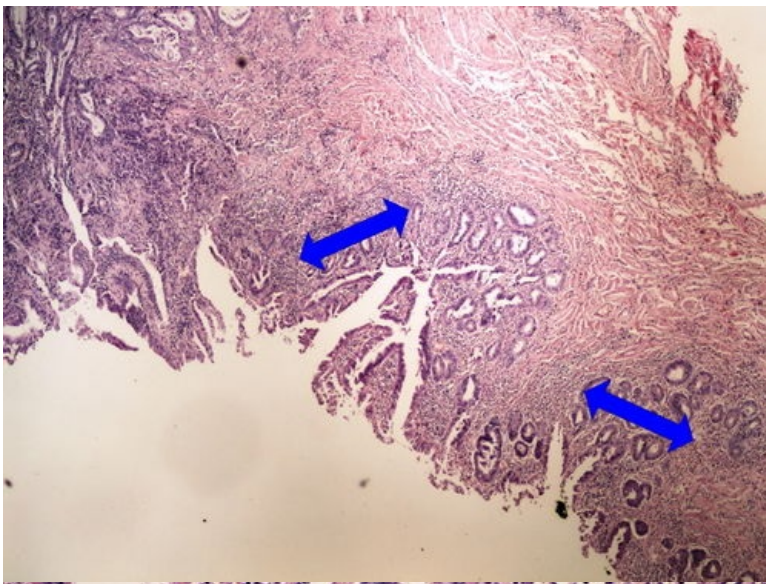
Preparát č.3 a č.4 - kancerisovaný adenom tlustého střeva



Struktury

[Expand]

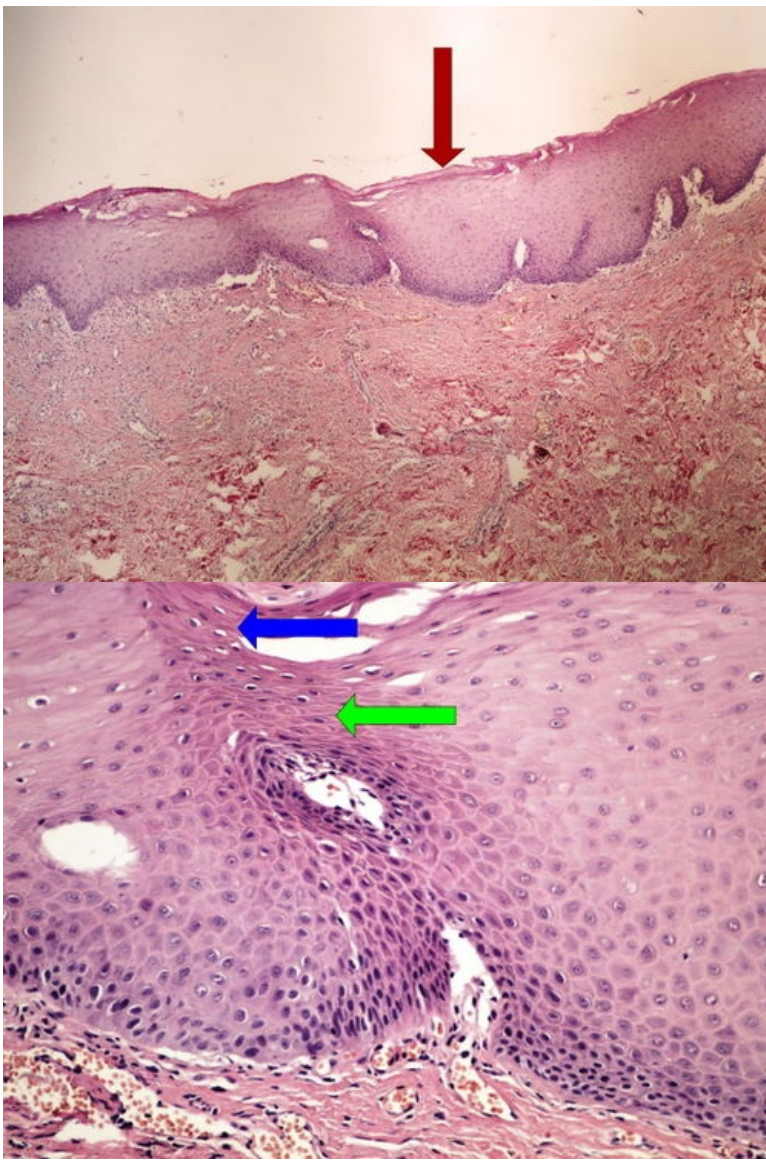
Preparát č.5 a č.6 - DALM



Struktury

[Expand]

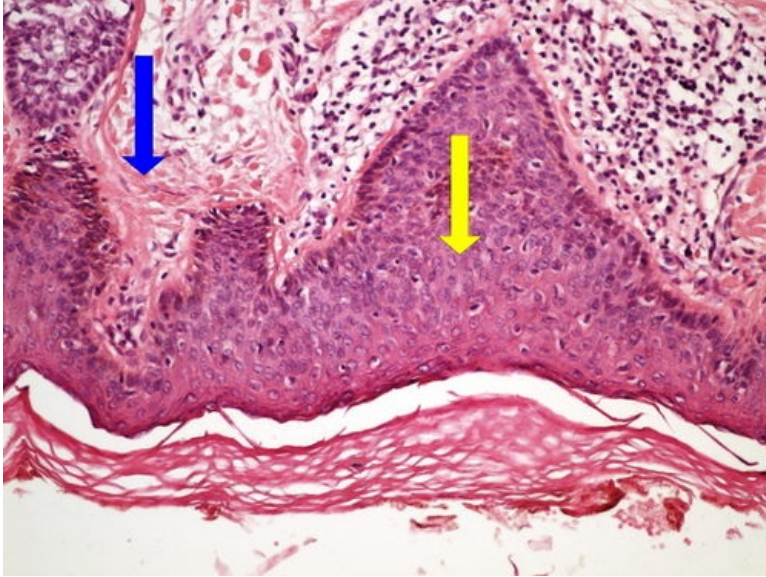
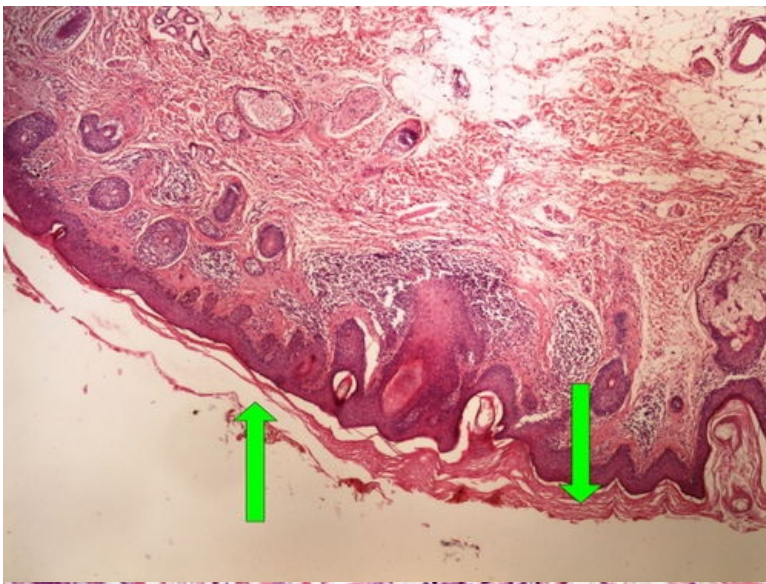
Preparát č.7 a č.8 - leukoplakie



Struktury

[Expand]

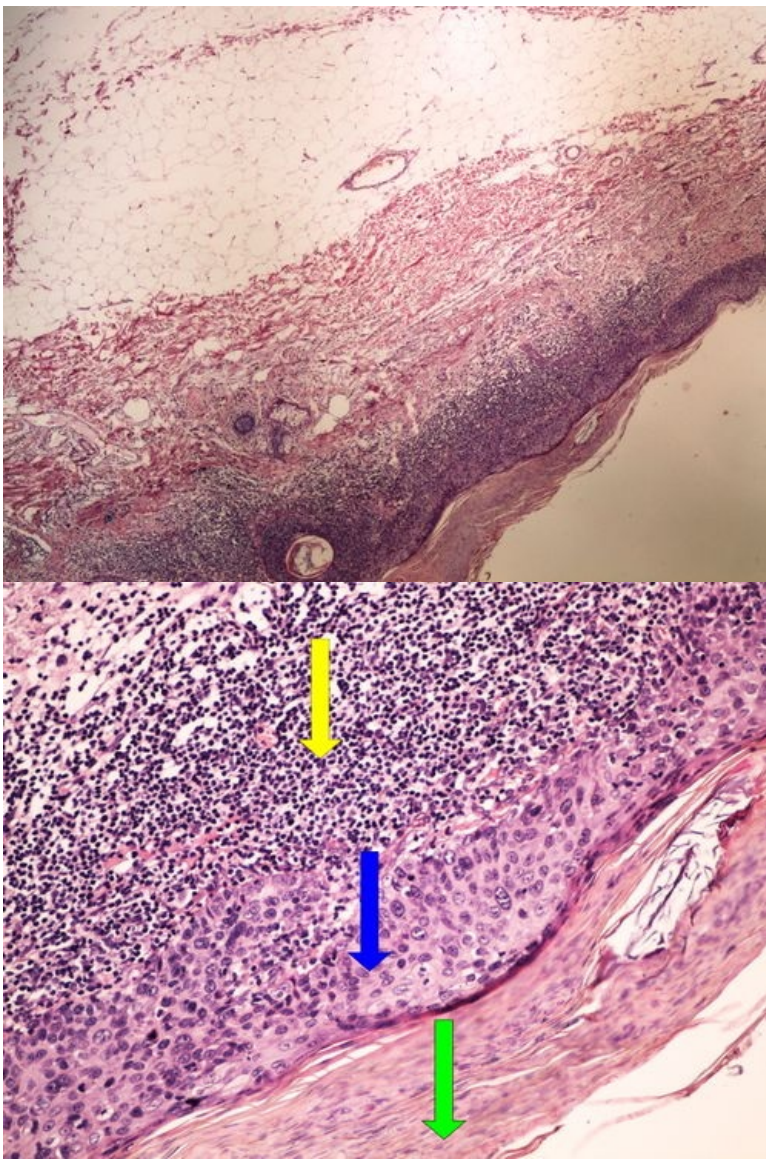
Preparát č.9 a č.10 - aktinická keratosa



Struktury

[Expand]

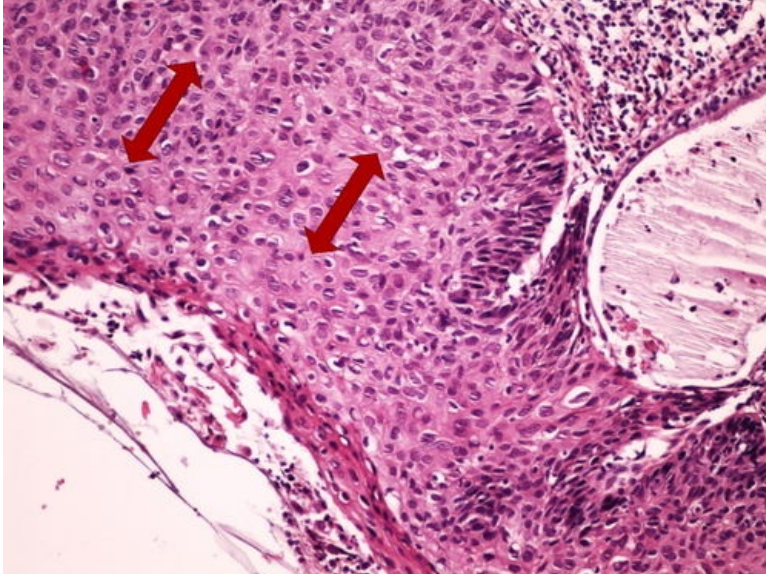
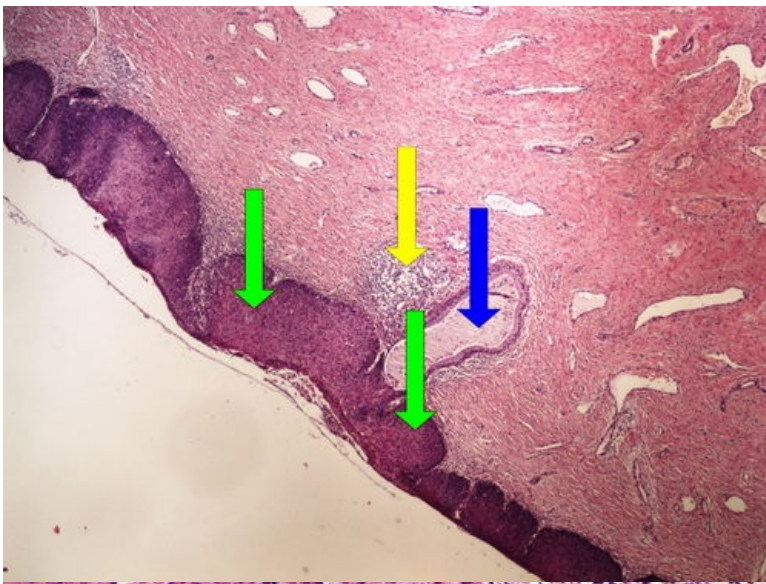
Preparát č.11 a č.12 - Bowenova dermatosa



Struktury

[Expand]

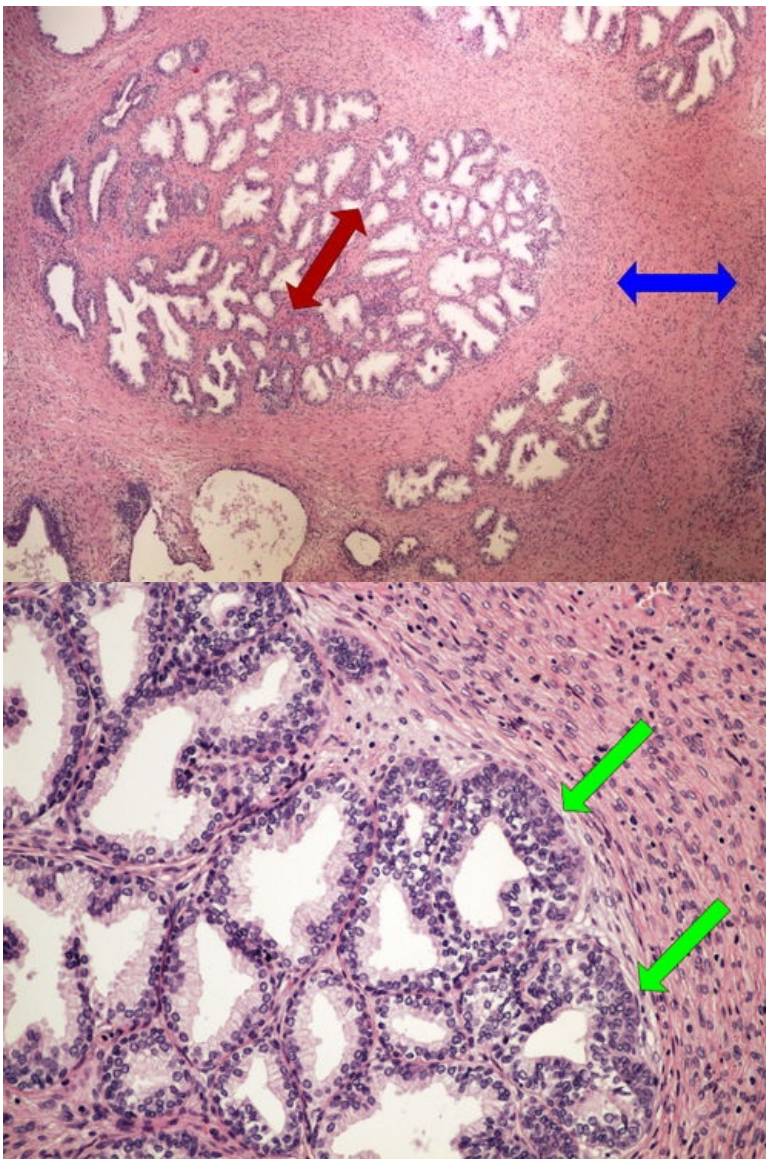
Preparát č.13 a č.14 - CIN



Struktury

[Expand]

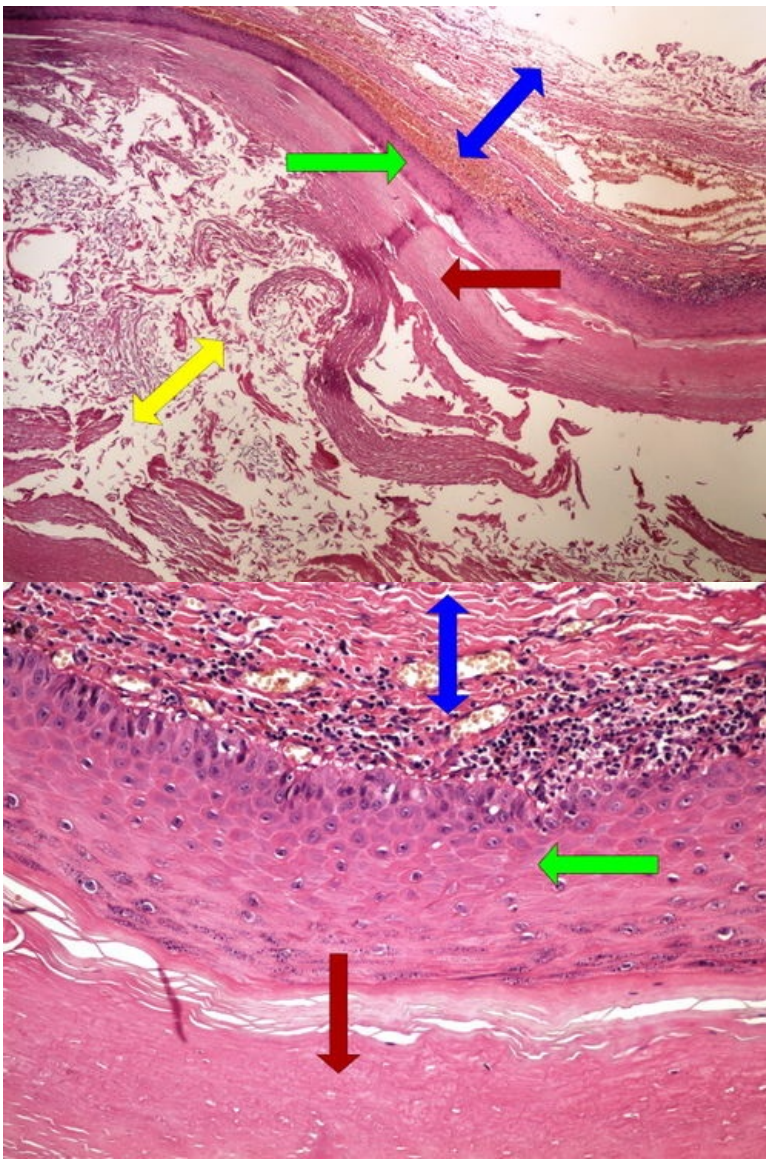
Preparát č.15 a č.16 - hyperplasie prostaty



Struktury

[Expand]

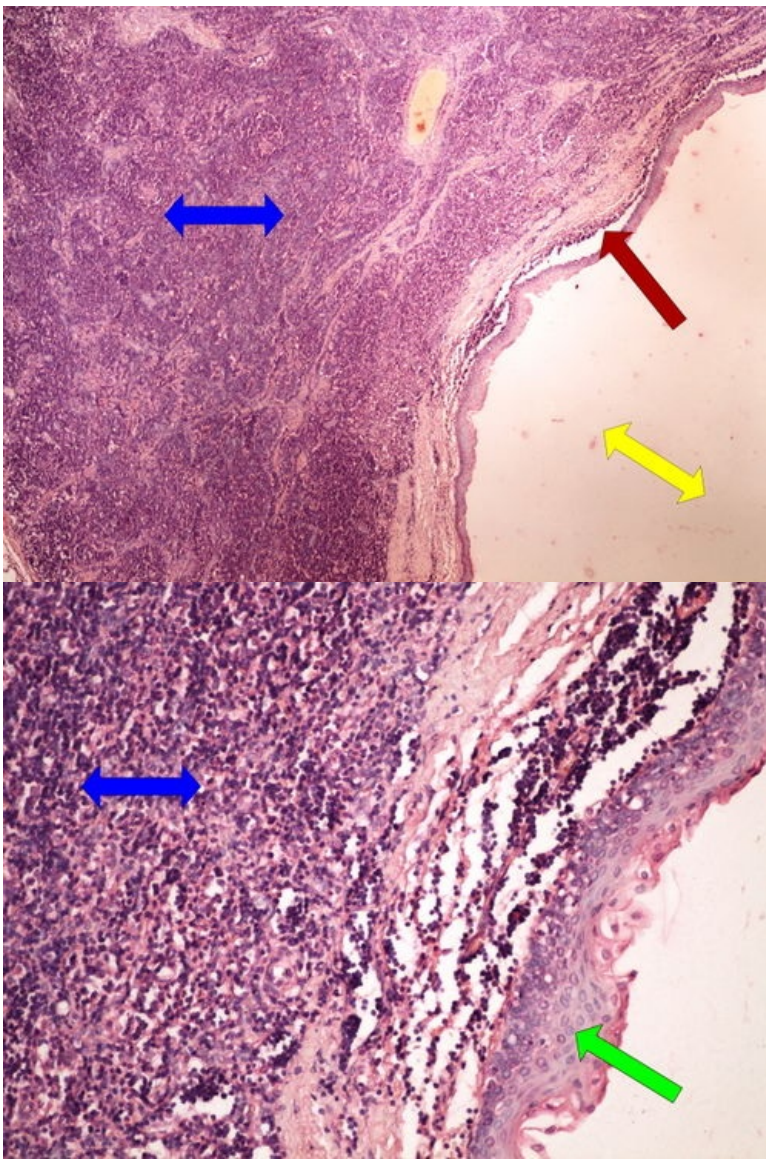
Preparát č.17 a č.18- epidermoidní cysta



Struktury

[Expand]

Preparát č.19 a č.20 - branchiogenní cysta



Struktury

[Expand]

Odkazy

Navigace

← Praktikum č. 8

Modul Obecné základy
patologie a patofyziologie (3.
LF UK)

Praktikum č. 10 →