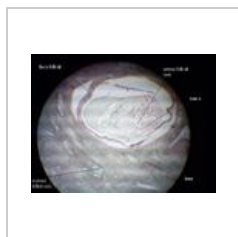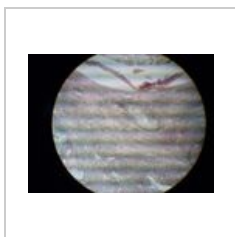


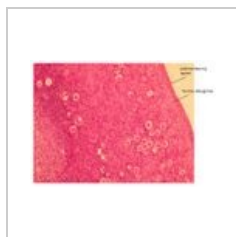
Portál:Ženský pohlavní systém



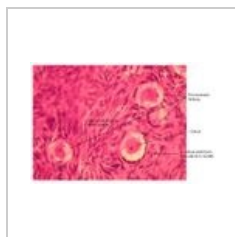Vaječník 1



Vaječník 2



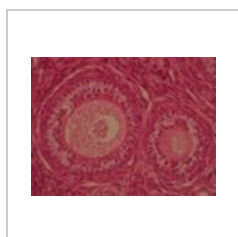
Vaječník 3



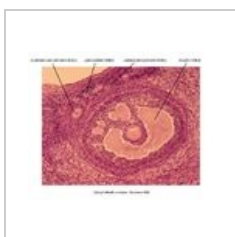
Vaječník 4



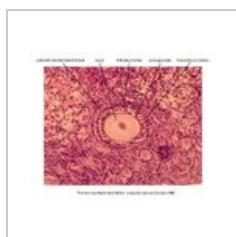
Vaječník 5



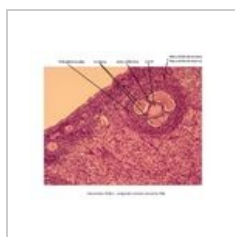
Vaječník 6



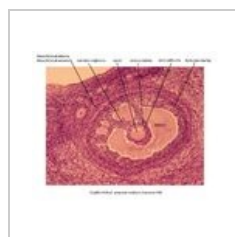
Přehled
jednotlivých
vývojových stádií
folikulů



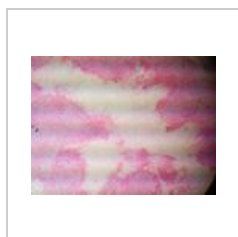Primární
multilaminární
folikul



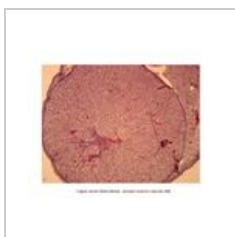Sekundární folikul




Graafův (zralý)
folikul



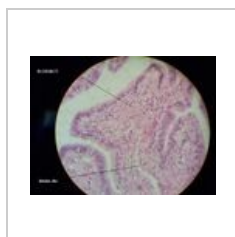
Žluté tělísko 1
(Corpus luteum)




Žluté tělísko 2
(Corpus luteum)



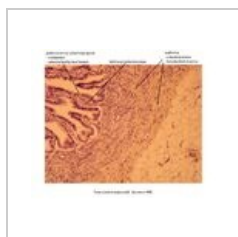Vejcovod 1



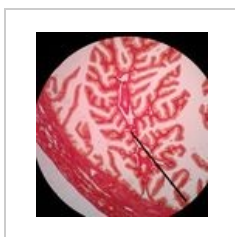
Vejcovod 2




Vejcovod 3



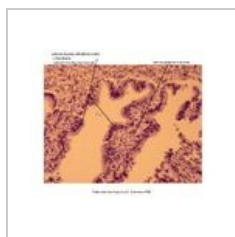Vejcovod 4



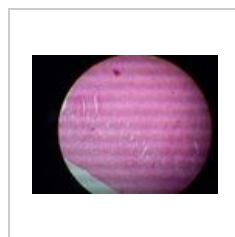
Vejcovod 5



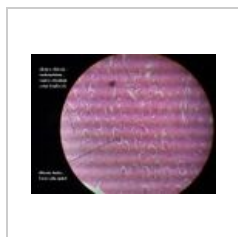Vejcovod 6



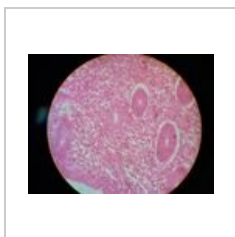Detail epitelu
vejcovodu



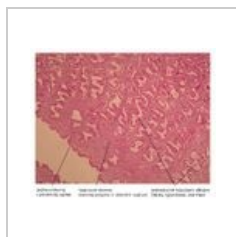
Tělo děložní 1



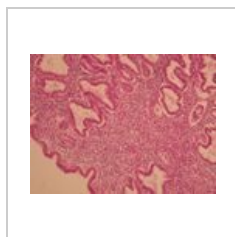Tělo děložní 2



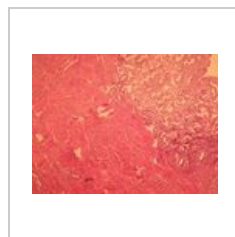Tělo děložní 3



Tělo děložní 4



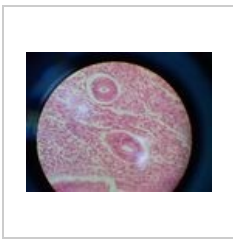Tělo děložní 5



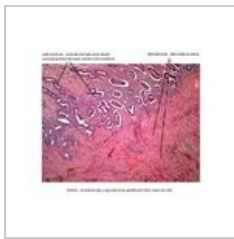Děloha



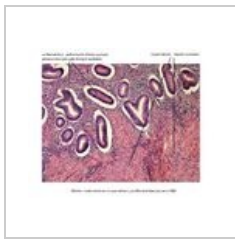
Endometrium 1



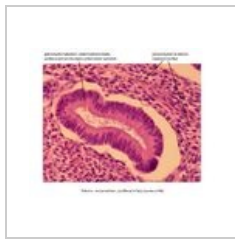Endometrium 2



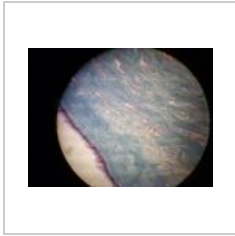Endometrium a myometrium (proliferací fáze)



Detail - endometrium a myometrium (proliferací fáze)



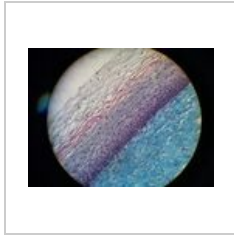
Detail - jednoduchá tubulózni žláza v endometriu



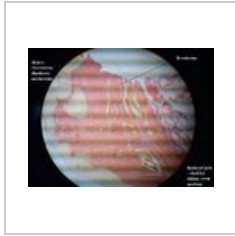
Hrdlo děložní 1



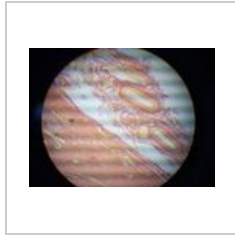
Hrdlo děložní 2



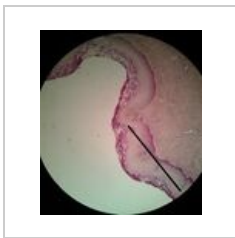
Hrdlo děložní 3



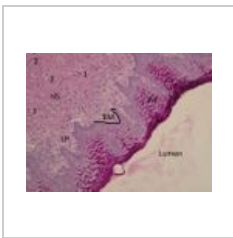Vagina 1



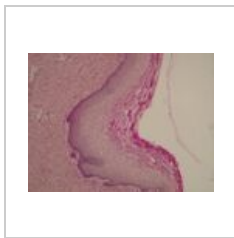
Vagina 2




Vagina 3



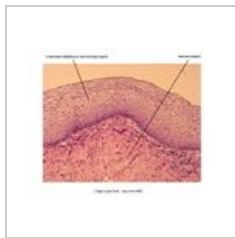
Vagina 4 (PAS)




Vagina 5 (PAS)




Vagina 6



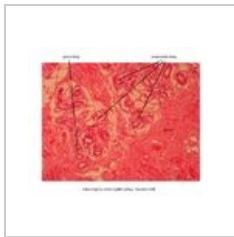Detail epitelu vaginy



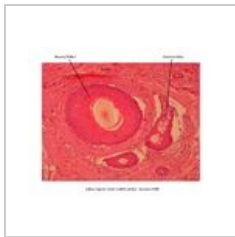Malé stydké pysky



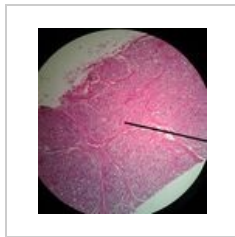Velké stydké pysky



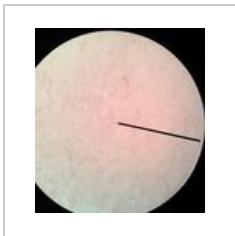
Detail - aromatická žláza (Velké stydké pysky)



Detail - mazová žláza a vlasový folikul (Velké stydké pysky)



Mléčná žláza 1 (Mamma lactans)



Mléčná žláza 2 (Mamma nonlactans)