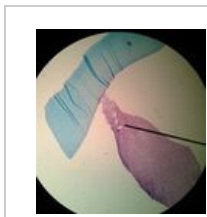
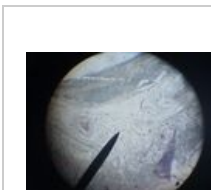



Portál:Obecná histologie



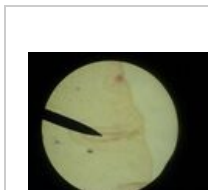
Mezenchym 1



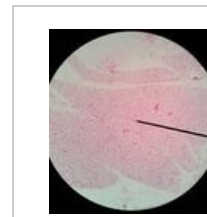Kolagenní vazivo 1



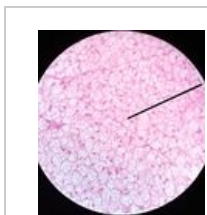
Retikulární vazivo 1



Tukové vazivo 1



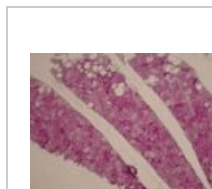
Hnědý tuk 1



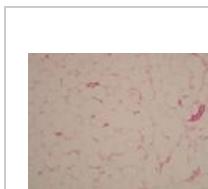Hnědý tuk 2




Hnědý tuk 3



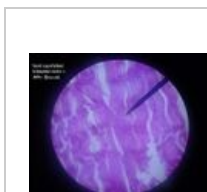
Hnědý tuk 4



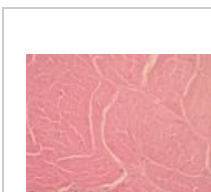
Bílý tuk 1



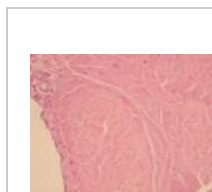
Bílý tuk 2




Šlacha 1



Šlacha 2



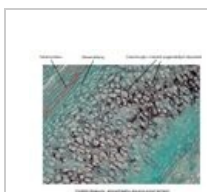Šlacha 3



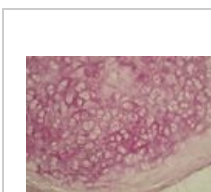Elastická chrupavka 1



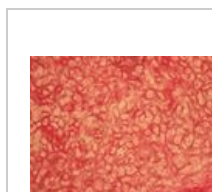Elastická chrupavka 2



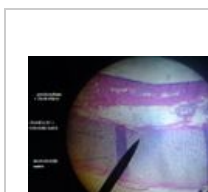Elastická chrupavka 3



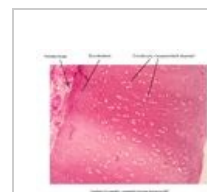
Elastická chrupavka 4




Elastická chrupavka 5



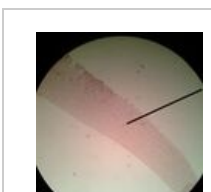Hyalinní chrupavka 1



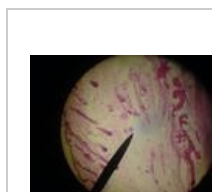
Hyalinní chrupavka 2



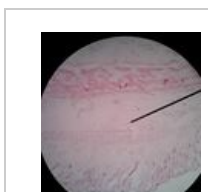
Vazivová chrupavka 1



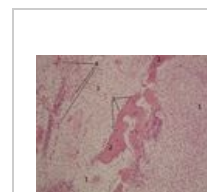
Kloubní chrupavka



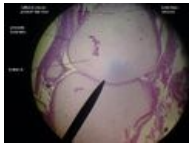
Desmogenní osifikace 1



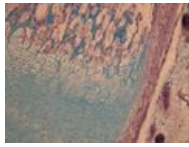
Desmogenní osifikace 2




Desmogenní osifikace 2



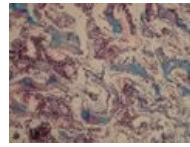
Chondrogenní osifikace 1



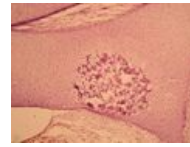
Chondrogenní osifikace 2



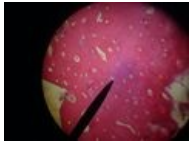
Chondrogenní osifikace 3



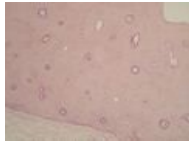
Chondrogenní osifikace 4



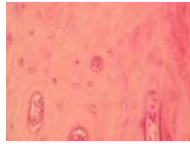
Chondrogenní osifikace 5



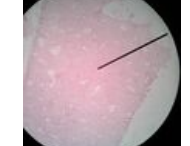
Lamelová kost kompaktní 1



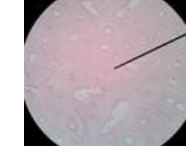Lamelová kost kompaktní 2



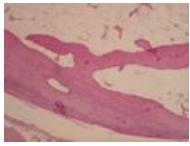
Lamelová kost kompaktní 3



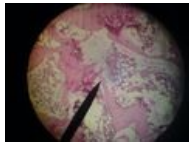Lamelová kost kompaktní 4



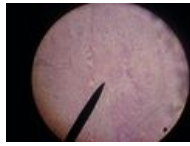
Lamelová kost kompaktní 5



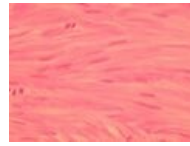Lamelová kost kompaktní 6



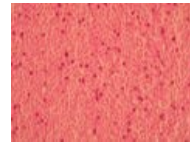
Lamelová kost spongiózní



Hladká svalovina 1




Hladká svalovina 2



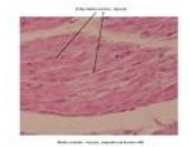Hladká svalovina 3



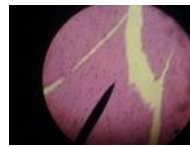
Hladká svalovina 4




Hladká svalovina 5



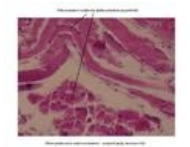
Hladká svalovina 6



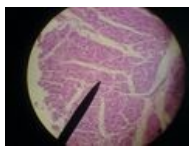Kosterní sval (HE) 1



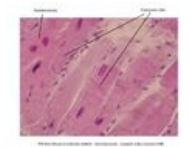
Kosterní sval (HH) 2



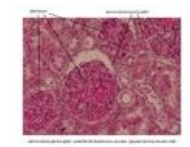
Kosterní sval 3



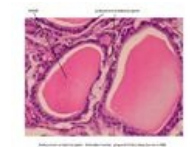Myokard 1



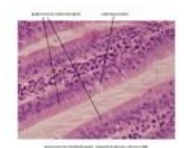
Myokard 2



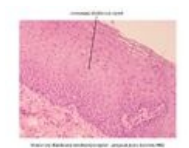Jednovrstevný plochý epitel 1



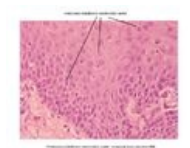Jednovrstevný kubický epitel 1



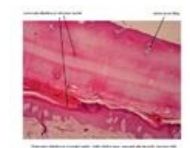
Jednovrstevný cylindrický epitel 1



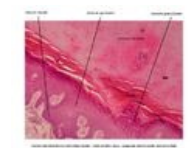Vrstevnatý dlaždicový nerohovějící epitel 1



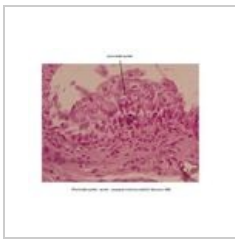
Vrstevnatý dlaždicový nerohovějící epitel 2



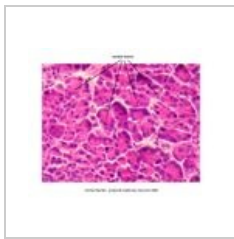
Vrstevnatý dlaždicový rohovějící epitel 1



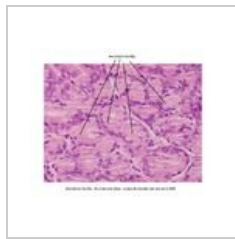
Vrstevnatý dlaždicový rohovějící epitel 2



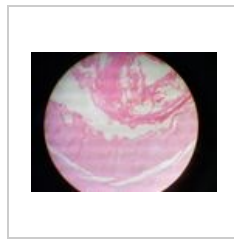Přechodný epitel 1




Serózní buňka 1



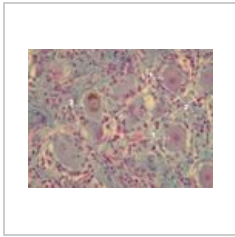
Mucinózní buňka 1



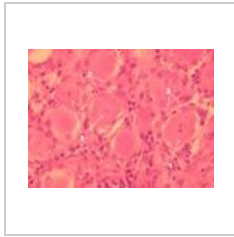
Spinální ganglion 1



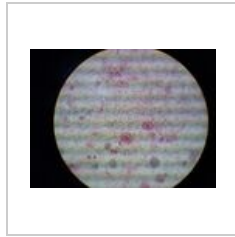
Spinální ganglion 2



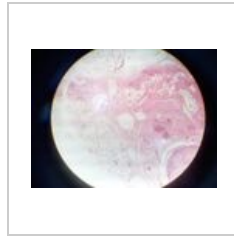
Spinální ganglion 3



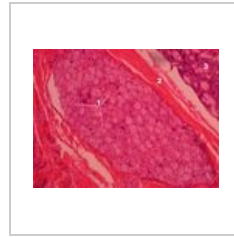Spinální ganglion 4



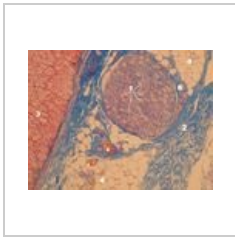
Vegetativní ganglion 1



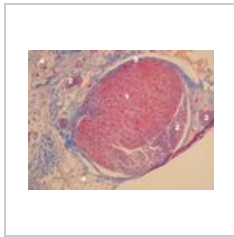
Vegetativní ganglion 2




Vegetativní ganglion 3



Vegetativní ganglion 4



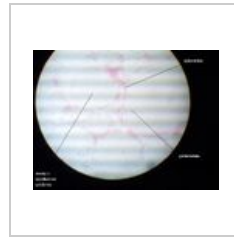
Vegetativní ganglion 5



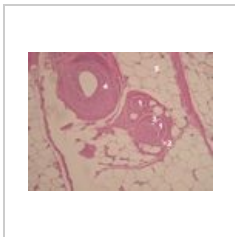
Periferní nerv 1



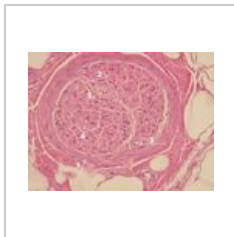
Periferní nerv 2



Periferní nerv 3



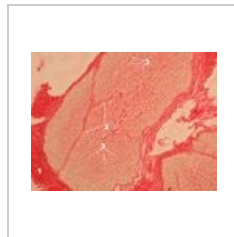
Periferní nerv 4



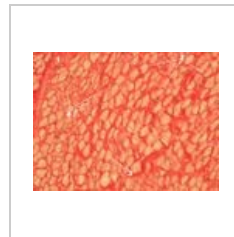
Periferní nerv 5



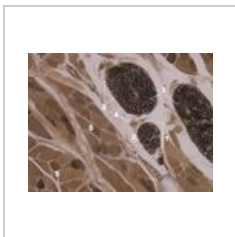
Periferní nerv 6



Periferní nerv 7



Periferní nerv 8



Periferní nerv 9