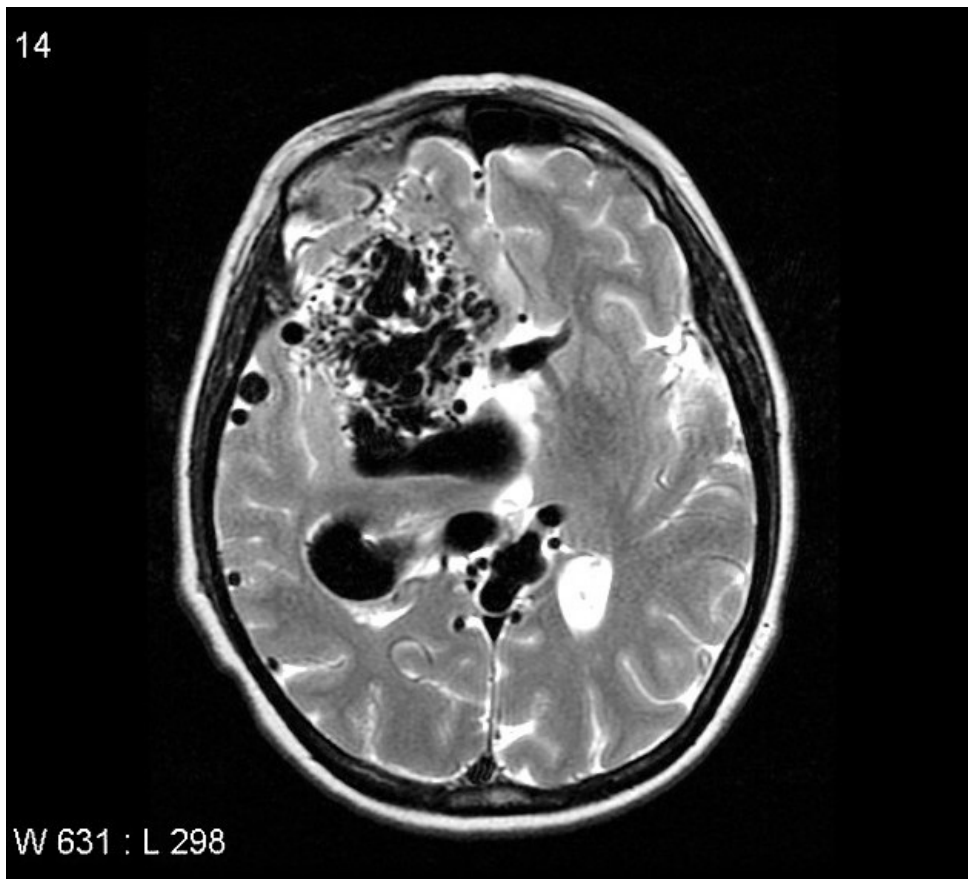


# Soubor:AVM cerebral.jpg

14



This image can contain annotations.  
Move the mouse over the image to display.  
No higher resolution available.

AVM\_cerebral.jpg (630 × 570 pixels, file size: 60 KB, MIME type: image/jpeg)



**Open in Media Viewer**



**Popis** MRI AVM

**Zdroj** <https://radiopaedia.org/articles/arteriovenous-malformation-2?lang=us>


**Datum** 2021-06-20

**Autor** kolektiv Radiopaedia

**Licence** Volné dílo nebo soubor, který nemá povahu autorského díla.

## File history

Click on a date/time to view the file as it appeared at that time.

	Date/Time	Thumbnail	Dimensions	User	Comment
current	08:52, 20 June 2021		630 × 570 (60 KB)	AdELA (talk   contribs)	

You cannot overwrite this file.

## File usage

The following page uses this file:

- Arteriovenózní malformace