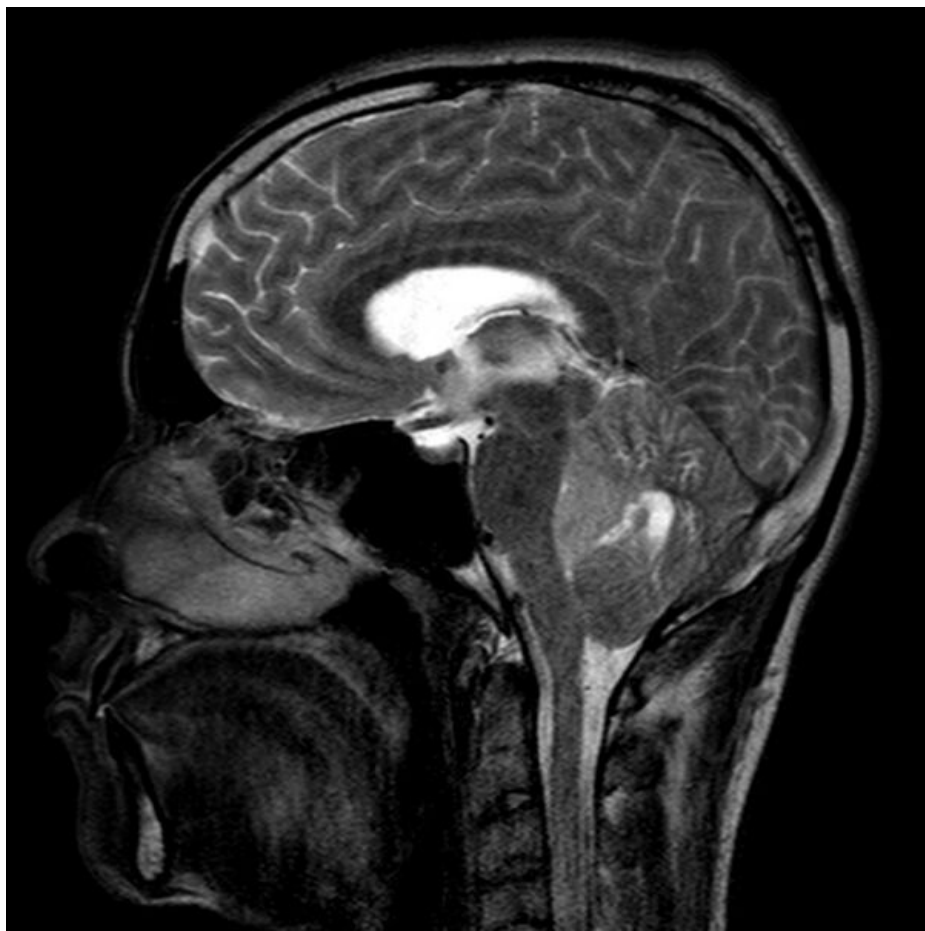


Soubor:Anaplas mri.jpg



Size of this preview: 600 × 600 pixels.

Original file (630 × 630 pixels, file size: 92 KB, MIME type: image/jpeg)

Popis MRI - anaplastický ependymom

Zdroj <https://radiopaedia.org/articles/ependymoma?lang=us>

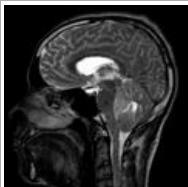
Datum 2021-04-08

Autor kolektiv Radiopaedia

Licence Volné dílo nebo soubor, který nemá povahu autorského díla.

File history

Click on a date/time to view the file as it appeared at that time.

	Date/Time	Thumbnail	Dimensions	User	Comment
current	08:00, 8 April 2021		630 × 630 (92 KB)	AdELA (talk contribs)	

You cannot overwrite this file.

File usage

The following 2 pages use this file:

- Ependymom
- Nádory mozečku a IV. komory u dospělých