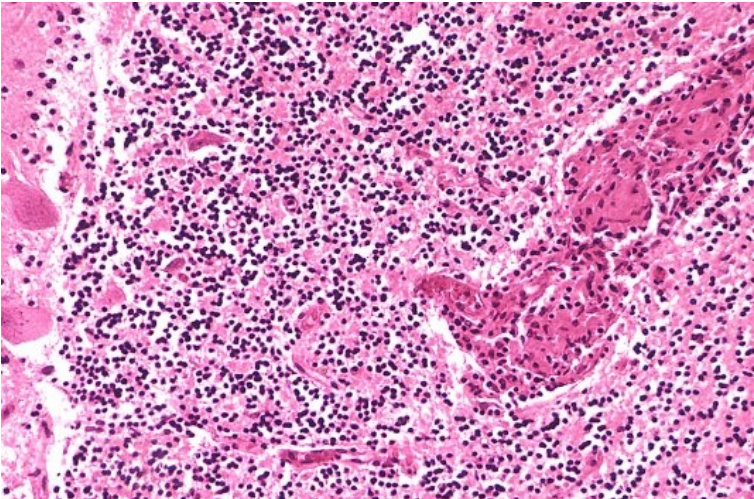


Soubor:Angiitis cns A72-276-12 resize.jpg



This image can contain annotations.
Move the mouse over the image to display.
No higher resolution available.

Angiitis_cns_A72-276-12_resize.jpg (533 × 352 pixels, file size: 110 KB, MIME type: image/jpeg)

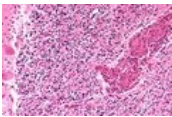
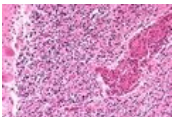
 **Open in Media Viewer**



Popis	sarkoidóza mozku
Zdroj	http://granuloma.homestead.com/sarcoidosis_extrapulmonary.html
Datum	nezadáno
Autor	Yale Rosen, M.D.
Licence	Creative Commons NonCommercial-NoDerivs 3.0 Unported (CC BY-NC-ND 3.0) (http://creativecommons.org/licenses/by-nc-nd/3.0/)

File history

Click on a date/time to view the file as it appeared at that time.

	Date/Time	Thumbnail	Dimensions	User	Comment
current	15:39, 8 November 2011		533 × 352 (110 KB)	JANKA (talk contribs)	rozlišení
	15:36, 8 November 2011		162 × 109 (11 KB)	JANKA (talk contribs)	{{Soubor popis = sarkoidóza mozku zdroj = http://granuloma.homestead.com/sarcoidosis_extrapulmonary.html datum = autor = Yale Rosen, M.D. licence = {{Zpracovat doplnit licenci}} }} Kategorie:patologie Kategorie:vnitřní lékařství [[Kate

You cannot overwrite this file.

File usage

The following page uses this file:

- Sarkoidóza nervového systému

Metadata

This file contains additional information, probably added from the digital camera or scanner used to create or digitize it.

If the file has been modified from its original state, some details may not fully reflect the modified file.