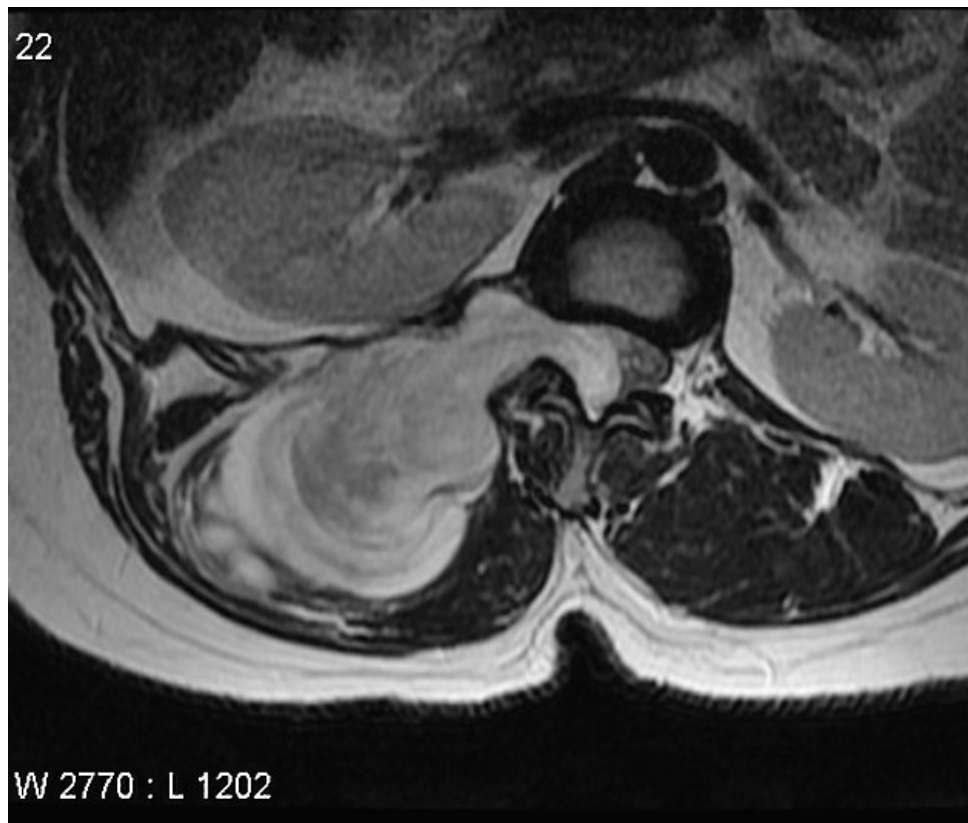


Soubor:Axial schwannoma.jpg



This image can contain annotations.
Move the mouse over the image to display.
No higher resolution available.

Axial_schwannoma.jpg (630 × 533 pixels, file size: 58 KB, MIME type: image/jpeg)

 **Open in Media Viewer** 

Popis MRI_axial_spinální schwannom

Zdroj <https://radiopaedia.org/articles/spinal-schwannoma>


Datum 2021-05-05

Autor kolektiv Radiopaedia

Licence Volné dílo nebo soubor, který nemá povahu autorského díla.

File history

Click on a date/time to view the file as it appeared at that time.

	Date/Time	Thumbnail	Dimensions	User	Comment
current	12:39, 5 May 2021		630 × 533 (58 KB)	AdELA (talk contribs)	

You cannot overwrite this file.

File usage

The following page uses this file:

- Spinální nádory