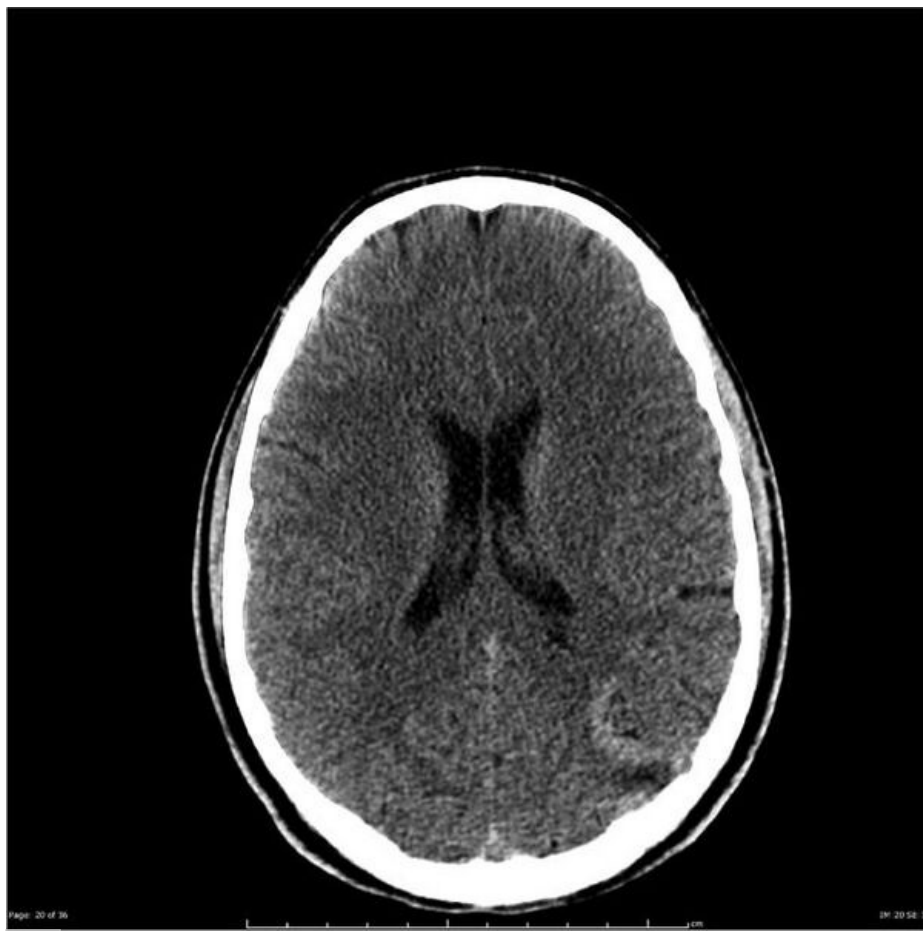

# Soubor:CT brainAVM non-contrast.jpg



This image can contain annotations.  
Move the mouse over the image to display.  
Size of this preview: 600 × 600 pixels.

Original file (630 × 630 pixels, file size: 42 KB, MIME type: image/jpeg)



**Popis** CT AVM

**Zdroj** <https://radiopaedia.org/cases/cerebral-arteriovenous-malformation-19?lang=us>


**Datum** 2021-06-26

**Autor** kolektiv Radiopaedia

**Licence** Volné dílo nebo soubor, který nemá povahu autorského díla.

## File history

Click on a date/time to view the file as it appeared at that time.

	Date/Time	Thumbnail	Dimensions	User	Comment
current	13:07, 26 June 2021		630 × 630 (42 KB)	AdELA (talk   contribs)	

You cannot overwrite this file.

## File usage

The following page uses this file:

- Arteriovenózní malformace