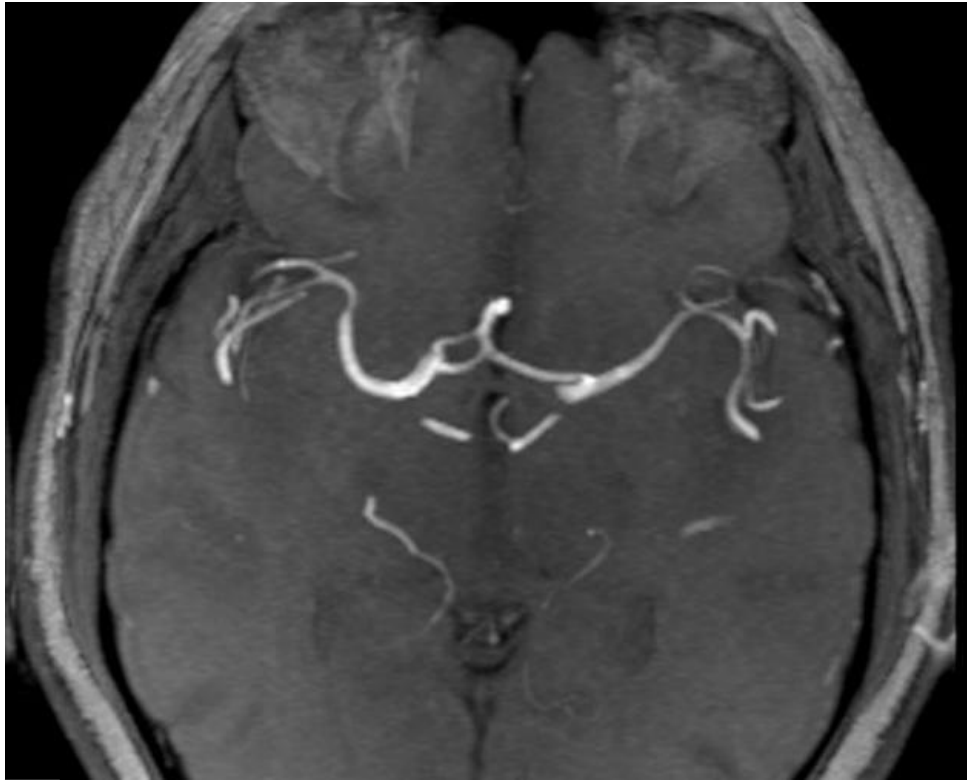


# Soubor:Fenestrated ACA.jpg



This image can contain annotations.  
Move the mouse over the image to display.  
No higher resolution available.

Fenestrated\_ACA.jpg (630 × 506 pixels, file size: 25 KB, MIME type: image/jpeg)

 **Open in Media Viewer** 

**Popis** Fenestrovaná a. cerebri anterior

**Zdroj** <https://radiopaedia.org/articles/anterior-cerebral-artery?lang=us>

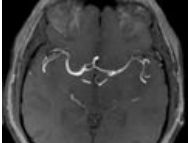
**Datum** 2021-05-27

**Autor** kolektiv Radiopaedia

**Licence** Volné dílo nebo soubor, který nemá povahu autorského díla.

## File history

Click on a date/time to view the file as it appeared at that time.

	Date/Time	Thumbnail	Dimensions	User	Comment
current	<b>21:36, 27 May 2021</b>		630 × 506 (25 KB)	AdELA (talk   contribs)	

You cannot overwrite this file.

# File usage

The following page uses this file:

- Willisův okruh