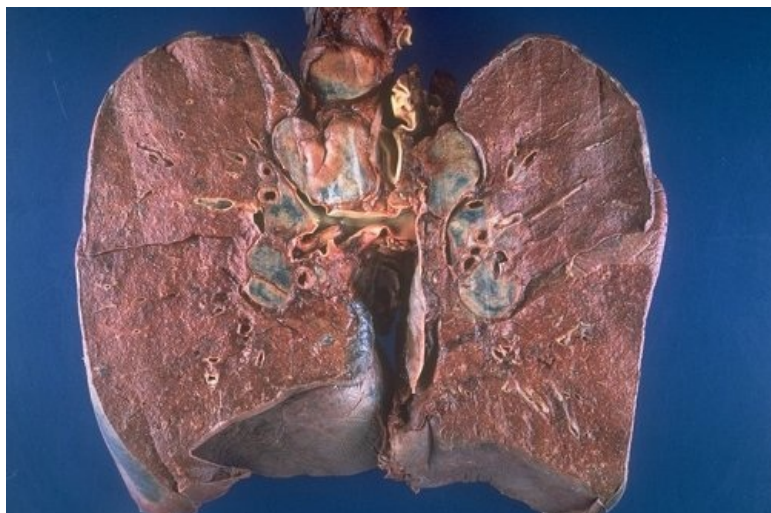

Soubor:Gross sarcoid bhl.jpg



No higher resolution available.

Gross_sarcoid_bhl.jpg (500 × 333 pixels, file size: 46 KB, MIME type: image/jpeg)

Popis Bilateral hilar lymphadenopathy

Zdroj http://granuloma.homestead.com/sarcoidosis_gross.html


Datum *nezadáno*

Autor Yale Rosen, M.D.

Licence Creative Commons NonCommercial-NoDerivs 3.0 Unported (CC BY-NC-ND 3.0) (<http://creativecommons.org/licenses/by-nc-nd/3.0/>)

File history

Click on a date/time to view the file as it appeared at that time.

	Date/Time	Thumbnail	Dimensions	User	Comment
current	12:53, 18 October 2011		500 × 333 (46 KB)	OK (talk contribs)	{{Soubor popis = Bilateral hilar lymphadenopathy zdroj = http://granuloma.homestead.com/sarcoidosis_gross.html datum = autor = Yale Rosen, M.D. licence = {{Zpracovat doplňit licenci}} }} Kategorie:patologie Kategorie:Obrázky

You cannot overwrite this file.

File usage

The following 2 pages use this file:

- Sarkoidóza (interna)
- Sarkoidóza (patologie)

Metadata

This file contains additional information, probably added from the digital camera or scanner used to create or digitize it.

If the file has been modified from its original state, some details may not fully reflect the modified file.

