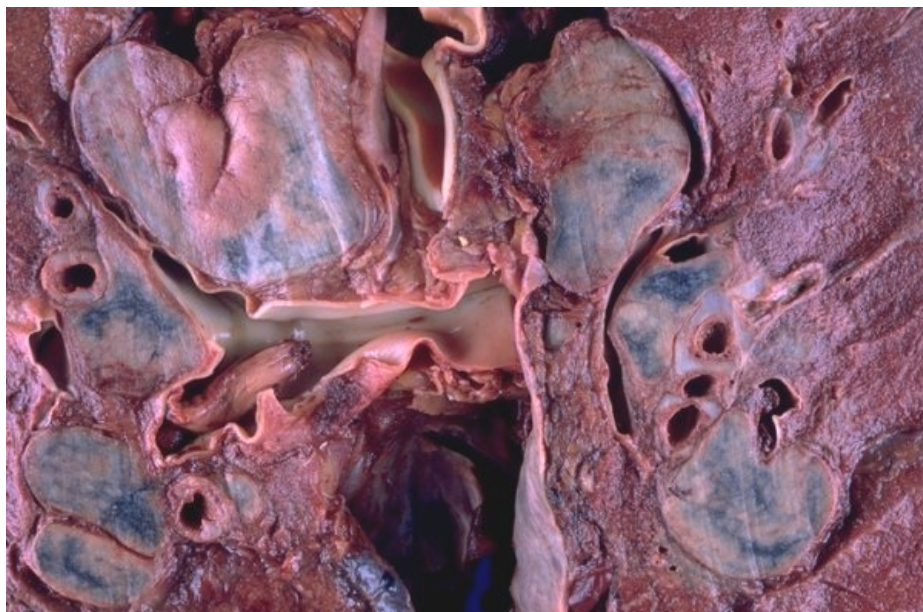


Soubor:Gross sarcoid bhl78.jpg



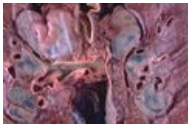
No higher resolution available.

Gross_sarcoid_bhl78.jpg (600 × 397 pixels, file size: 74 KB, MIME type: image/jpeg)

Popis	Bilateral hilar lymphadenopathy
Zdroj	http://granuloma.homestead.com/sarcoidosis_gross.html
Datum	<i>nezadáno</i>
Autor	Yale Rosen, M.D.
Licence	Creative Commons NonCommercial-NoDerivs 3.0 Unported (CC BY-NC-ND 3.0) (http://creativecommons.org/licenses/by-nc-nd/3.0/)

File history

Click on a date/time to view the file as it appeared at that time.

	Date/Time	Thumbnail	Dimensions	User	Comment
current	13:00, 18 October 2011		600 × 397 (74 KB)	OK (talk contribs)	{{Soubor popis = Bilateral hilar lymphadenopathy zdroj = http://granuloma.homestead.com/sarcoidosis_gross.html datum = autor = Yale Rosen, M.D. licence = {{Zpracovat doplňit licenci}} }} Kategorie:patologie Kategorie:Obrázky

You cannot overwrite this file.

File usage

The following file is a duplicate of this file (more details):

- Soubor:Sarcoidosis - Bilateral hilar lymphadenopathy (6076995153).jpg from Wikimedia Commons

The following 2 pages use this file:

- Sarkoidóza (patologie)
- Sarkoidóza lymfatického systému

Metadata

This file contains additional information, probably added from the digital camera or scanner used to create or digitize it.

If the file has been modified from its original state, some details may not fully reflect the modified file.