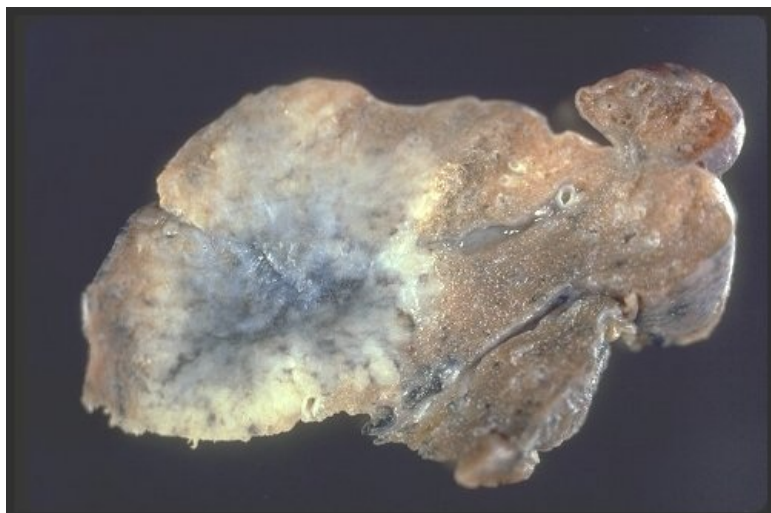


Soubor:Gross sarcoid nodular.jpg



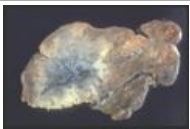
No higher resolution available.

Gross_sarcoid_nodular.jpg (500 × 333 pixels, file size: 29 KB, MIME type: image/jpeg)

Popis	Nodular sarcoidosis
Zdroj	http://granuloma.homestead.com/sarcoidosis_gross.html
Datum	<i>nezadáno</i>
Autor	Yale Rosen, M.D.
Licence	Creative Commons NonCommercial-NoDerivs 3.0 Unported (CC BY-NC-ND 3.0) (http://creativecommons.org/licenses/by-nc-nd/3.0/)

File history

Click on a date/time to view the file as it appeared at that time.

	Date/Time	Thumbnail	Dimensions	User	Comment
current	13:27, 18 October 2011		500 × 333 (29 KB)	OK (talk contribs)	{{Soubor popis = Nodular sarcoidosis zdroj = http://granuloma.homestead.com/sarcoidosis_gross.html datum = autor = Yale Rosen, M.D. licence = {{Zpracovat doplňit licenci}} }} Kategorie:patologie Kategorie:Obrázky

You cannot overwrite this file.

File usage

The following page uses this file:

- Sarkoidóza (patologie)

Metadata

This file contains additional information, probably added from the digital camera or scanner used to create or digitize it.

If the file has been modified from its original state, some details may not fully reflect the modified file.

