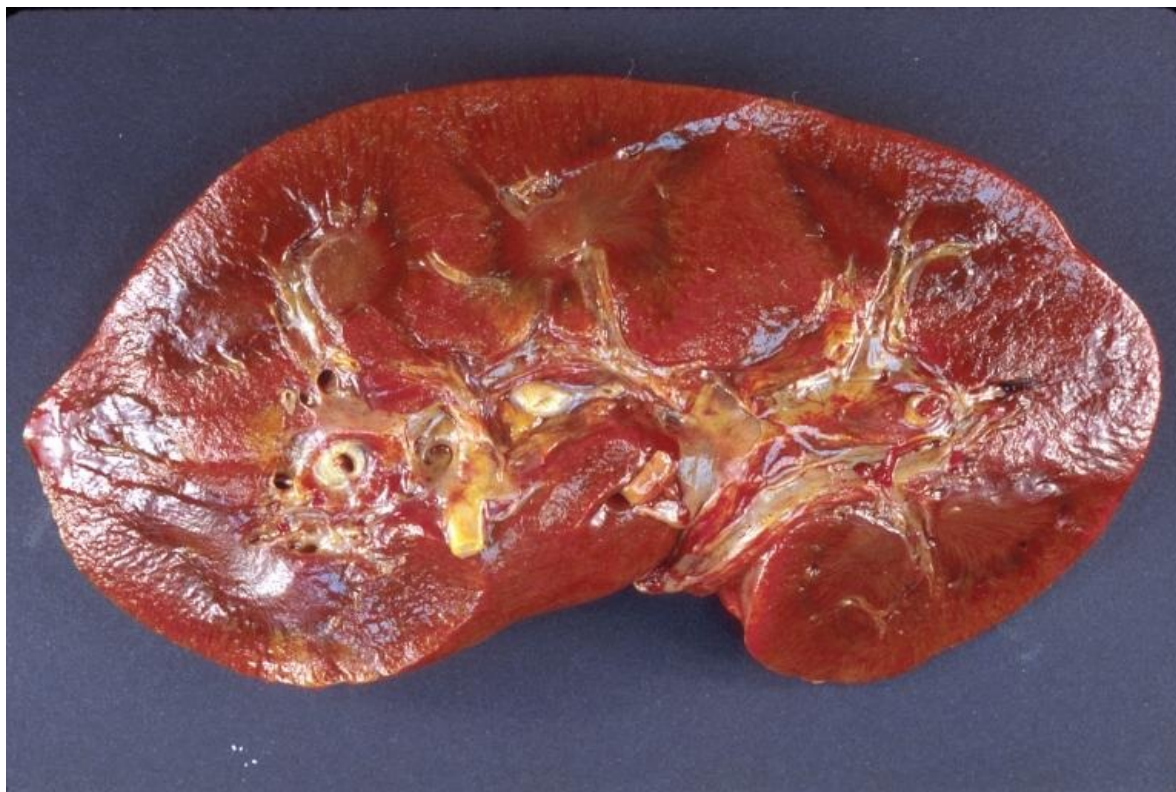

# Soubor:Kidneyamy.jpg



This image can contain annotations.  
Move the mouse over the image to display.  
No higher resolution available.

Kidneyamy.jpg (768 × 512 pixels, file size: 73 KB, MIME type: image/jpeg)

**Open in Media Viewer**

**Popis** Amyloidosis - ledvina

**Zdroj** <http://wikidoc.org/index.php/File:Kidneyamy.jpg>


**Datum** 2008-03-10

**Autor** Zorkun [1] (<http://wikidoc.org/index.php/User:Zorkun>)

**Licence** Creative Commons Attribution/Share-Alike License

## File history

Click on a date/time to view the file as it appeared at that time.

	Date/Time	Thumbnail	Dimensions	User	Comment
current	<b>16:04, 14 February 2012</b>		768 × 512 (73 KB)	OK (talk   contribs)	{{Soubor  popis = Amyloidosis - ledvina  zdroj = <a href="http://wikidoc.org/index.php/File:Kidneyamy.jpg">http://wikidoc.org/index.php/File:Kidneyamy.jpg</a>  datum = 2008-03-10  autor = Zorkun [http://wikidoc.org/index.php/User:Zorkun]  licence = {{Zpracovat doplňit licenci}} }} Kategorie:patologie [[Kategorie

You cannot overwrite this file.

## File usage

The following 2 pages use this file:

- Amyloidóza ledvin
- Glomerulopatie projevující se nefrotickým syndromem

## Metadata

This file contains additional information, probably added from the digital camera or scanner used to create or digitize it.

If the file has been modified from its original state, some details may not fully reflect the modified file.