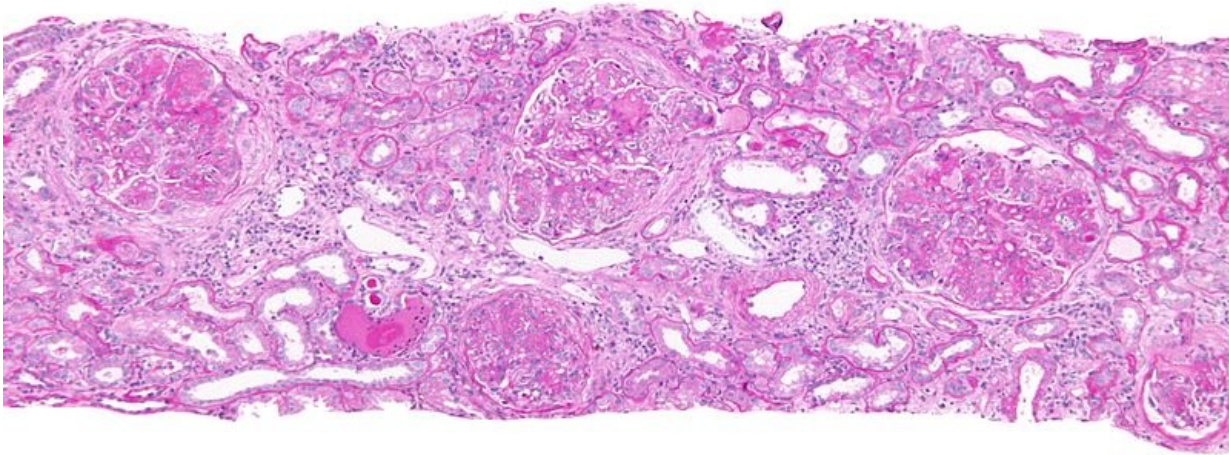


# Soubor:Membranoproliferative glomerulonephritis - intermed mag.jpg



This image can contain annotations.  
Move the mouse over the image to display.  
Size of this preview: 800 × 533 pixels.

Original file (4,272 × 2,848 pixels, file size: 2.92 MB, MIME type: image/jpeg)

 [Open in Media Viewer](#) 

This file is from Wikimedia Commons and may be used by other projects. The description on its file description page there is shown below.

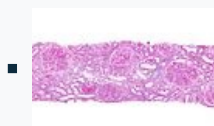
Kategorie:Obrázky s anotacemi

## Summary

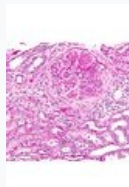
**Description** **English:** Intermediate magnification micrograph of **membranoproliferative glomerulonephritis**, abbreviated **MPGN**. PAS stain. Kidney biopsy.

The most common cause of MPGN is hepatitis C.

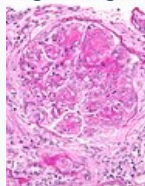
### Related images



Intermed. mag.



High mag.



Very high mag.

**Source** Own work

**Author** Nephron

## Licensing

**I, the copyright holder of this work, hereby publish it under the following licenses:**

This file is licensed under the Creative Commons Attribution-Share Alike 3.0 Unported license.

You are free:

- **to share** – to copy, distribute and transmit the work
- **to remix** – to adapt the work



Under the following conditions:

- **attribution** – You must give appropriate credit, provide a link to the license, and indicate if changes were made. You may do so in any reasonable manner, but not in any way that suggests the licensor endorses you or your use.
- **share alike** – If you remix, transform, or build upon the material, you must distribute your contributions under the same or compatible license (<https://creativecommons.org/licenses/by-sa/3.0/>) as the original.




Permission is granted to copy, distribute and/or modify this document under the terms of the **GNU Free Documentation License**, Version 1.2 or any later version published by the Free Software Foundation; with no Invariant Sections, no Front-Cover Texts, and no Back-Cover Texts. A copy of the license is included in the section entitled *GNU Free Documentation License*.

You may select the license of your choice.

## File history

Click on a date/time to view the file as it appeared at that time.

	Date/Time	Thumbnail	Dimensions	User	Comment
current	<b>06:29, 25 November 2011</b>		4,272 × 2,848 (2.92 MB)	wikimediacommons>Nephron	{{Information  Description = {{en 1=Intermediate magnification micrograph of ""membranoproliferative glomerulonephritis"", abbreviated ""MPGN"". PAS stain. The most com

## File usage

The following page uses this file:

- Glomerulonephritidy

## Metadata

This file contains additional information, probably added from the digital camera or scanner used to create or digitize it.

If the file has been modified from its original state, some details may not fully reflect the modified file.

Camera manufacturer	Canon
Camera model	Canon EOS DIGITAL REBEL XSi
Exposure time	1/250 sec (0.004)
F Number	f/0
ISO speed rating	200
Date and time of data generation	17:02, 24 November 2011
Lens focal length	0 mm