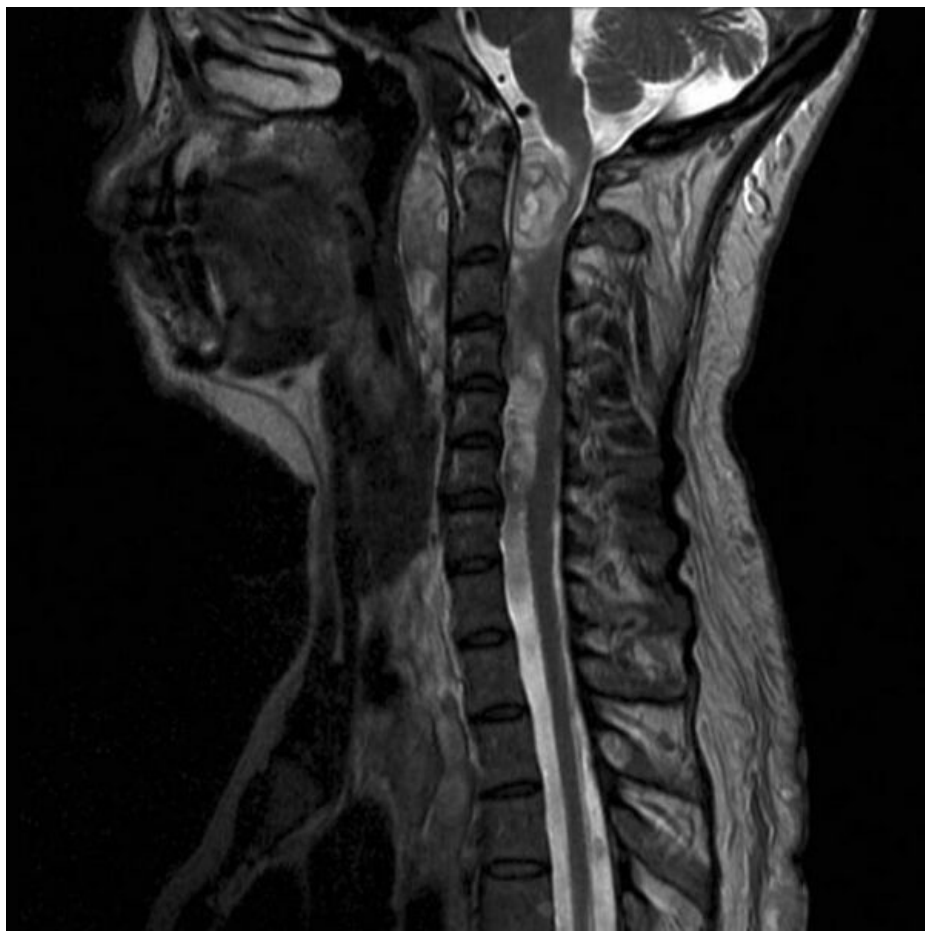

# Soubor:Nf-1 multiple neurofibromas.jpg




Size of this preview: 600 × 600 pixels.

Original file (630 × 630 pixels, file size: 43 KB, MIME type: image/jpeg)

<b>Popis</b>	NF-1 spinální multiplicitní neurofibromy
<b>Zdroj</b>	<a href="https://radiopaedia.org/cases/neurofibromatosis-type-1-2?lang=us">https://radiopaedia.org/cases/neurofibromatosis-type-1-2?lang=us</a>
<b>Datum</b>	2021-05-05
<b>Autor</b>	kolektiv Radiopaedia
<b>Licence</b>	Volné dílo nebo soubor, který nemá povahu autorského díla.

## File history

Click on a date/time to view the file as it appeared at that time.

	Date/Time	Thumbnail	Dimensions	User	Comment
current	<b>17:29, 5 May 2021</b>		630 × 630 (43 KB)	AdELA (talk   contribs)	

You cannot overwrite this file.

## File usage

The following page uses this file:

- Spinální nádory

## Metadata

This file contains additional information, probably added from the digital camera or scanner used to create or digitize it.

If the file has been modified from its original state, some details may not fully reflect the modified file.