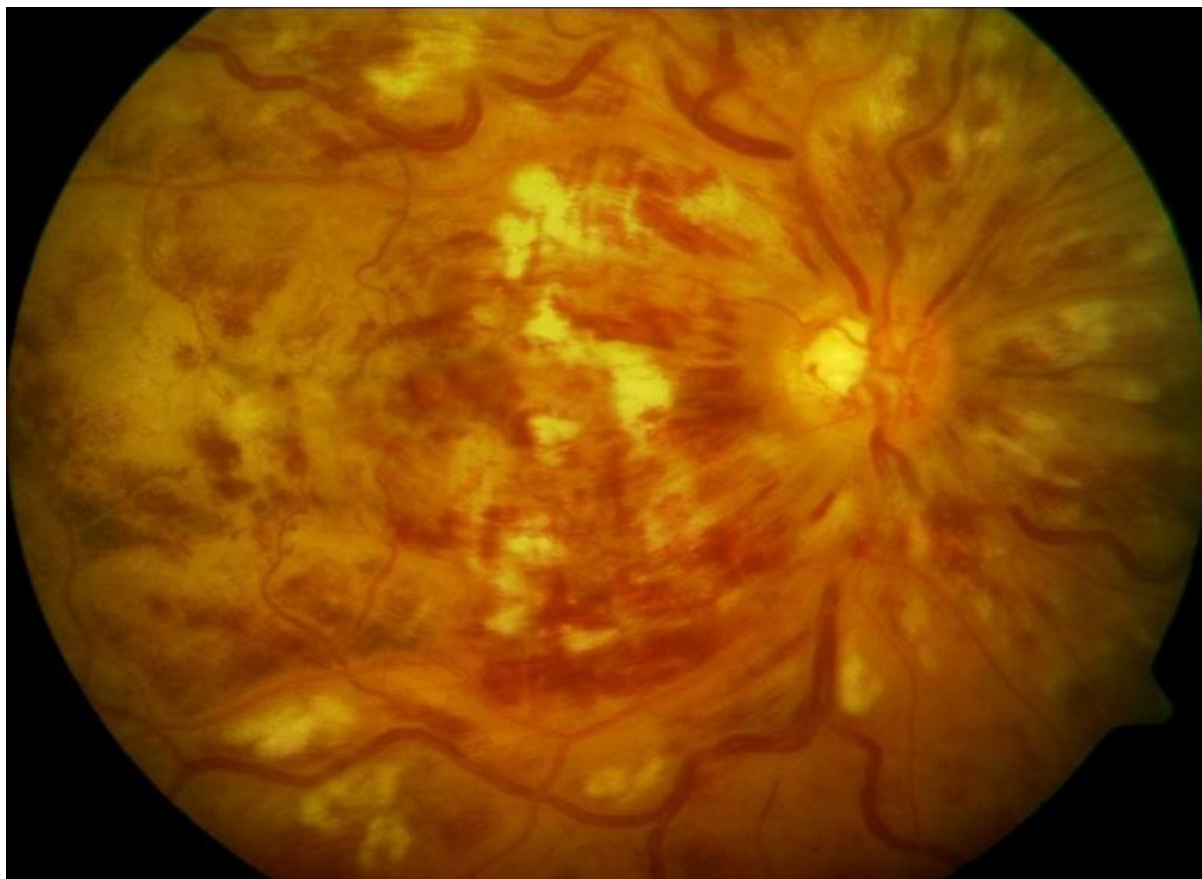


Soubor:Okluze vena centralis retinae.jpg



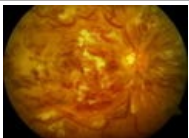
No higher resolution available.

Okluze_vena_centralis_retinae.jpg (784 × 569 pixels, file size: 60 KB, MIME type: image/jpeg)

Popis	kmenová okluze vena centralis retinae
Zdroj	Oční klinika FN Hradec Králové
Datum	2012-12-29
Autor	Oční klinika FN Hradec Králové
Licence	Vyhrazeno jen pro přímé užití na stránkách WikiSkripta.eu

File history

Click on a date/time to view the file as it appeared at that time.

	Date/Time	Thumbnail	Dimensions	User	Comment
current	00:25, 29 December 2012		784 × 569 (60 KB)	Adnav (talk contribs)	{{Soubor popis = kmenová okluze vena centralis retinae zdroj = Oční klinika FN Hradec Králové datum = 2012-12-29 autor = Oční klinika FN Hradec Králové licence = {{WS_licence}} }} Kategorie:Oční lékařství Kategorie:Obrázky

You cannot overwrite this file.

File usage

The following page uses this file:

- Uživatelka:Adnav/Pískoviště

Metadata

This file contains additional information, probably added from the digital camera or scanner used to create or digitize it.

If the file has been modified from its original state, some details may not fully reflect the modified file.