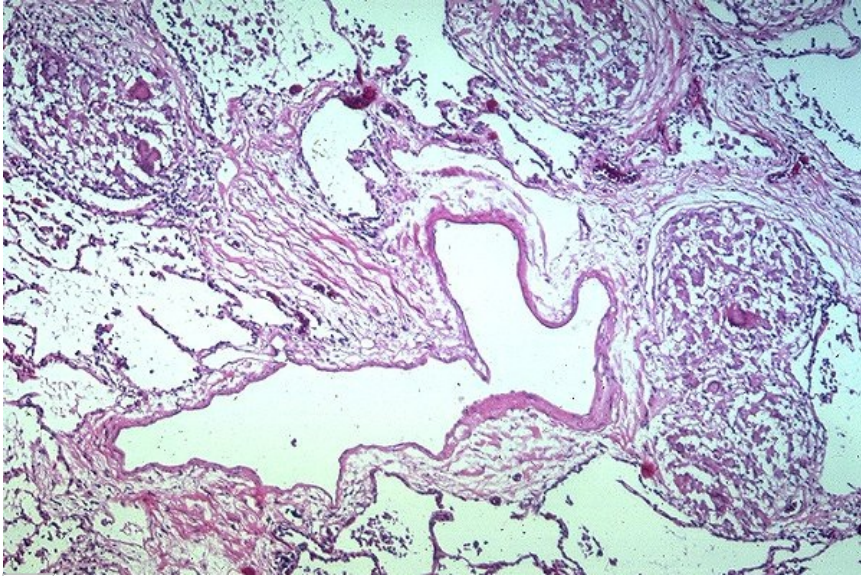


Soubor:Sarcoid lunginv79.jpg



This image can contain annotations.
Move the mouse over the image to display.
No higher resolution available.

Sarcoid_lunginv79.jpg (600 × 399 pixels, file size: 126 KB, MIME type: image/jpeg)

Open in Media Viewer

Popis	Granulomas adjacent to fibrous septum. Note presence of pulmonary vein and lymphatic
Zdroj	http://granuloma.homestead.com/sarcoid_lung_microscopic.html
Datum	<i>nezadáno</i>
Autor	Yale Rosen, M.D.
Licence	Creative Commons NonCommercial-NoDerivs 3.0 Unported (CC BY-NC-ND 3.0) (http://creativecommons.org/licenses/by-nc-nd/3.0/)

File history

Click on a date/time to view the file as it appeared at that time.

	Date/Time	Thumbnail	Dimensions	User	Comment
current	11:46, 10 October 2011		600 × 399 (126 KB)	Lampa (talk contribs)	{ {Soubor popis = Granulomy přilehlé k fibróznímu septu zdroj = http://granuloma.homestead.com/sarcoid_lung_microscopic.html datum = 2011-10-10 autor = Yale Rosen, M.D. licence = { {cc by-nd 3.0}} } } Kategorie:Patologie [[Kategorie:Pneumologie]

You cannot overwrite this file.

File usage

The following page uses this file:

- Sarkoidóza (patologie)

Metadata

This file contains additional information, probably added from the digital camera or scanner used to create or digitize it.
If the file has been modified from its original state, some details may not fully reflect the modified file.