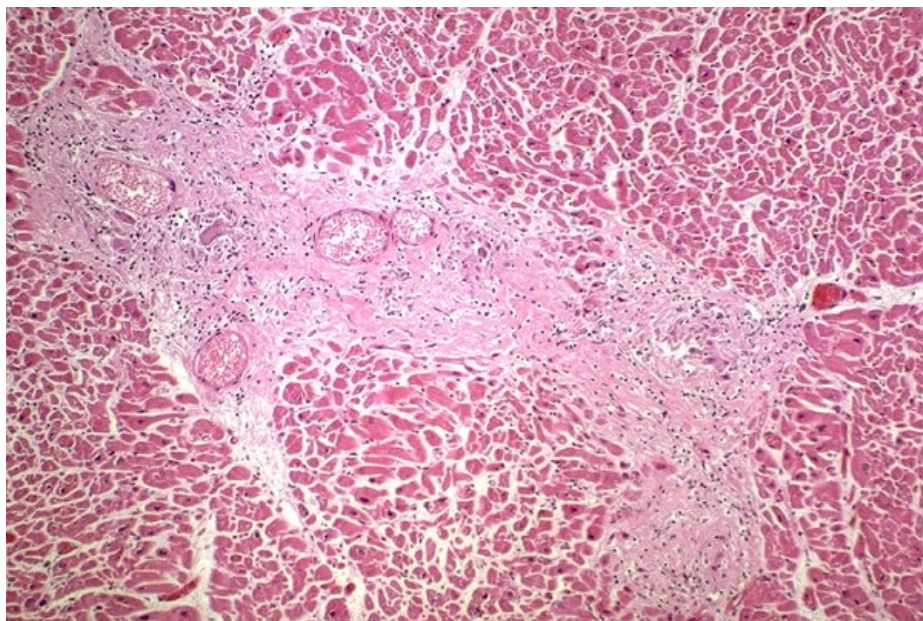


Soubor:Sarcoidosis extrapulmonary55.jpg



This image can contain annotations.
Move the mouse over the image to display.
No higher resolution available.

Sarcoidosis_extrapulmonary55.jpg (600 × 401 pixels, file size: 114 KB, MIME type: image/jpeg)

 **Open in Media Viewer** 

Popis Jaterní sarkoidóza

Zdroj http://granuloma.homestead.com/sarcoidosis_extrapulmonary.html

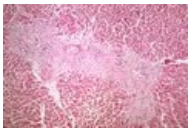
Datum *nezadáno*

Autor Yale Rosen, M.D.

Licence Creative Commons NonCommercial-NoDerivs 3.0 Unported (CC BY-NC-ND 3.0) (<http://creativecommons.org/licenses/by-nc-nd/3.0/>)

File history

Click on a date/time to view the file as it appeared at that time.

	Date/Time	Thumbnail	Dimensions	User	Comment
current	11:30, 1 November 2011		600 × 401 (114 KB)	JANKA (talk contribs)	{{Soubor popis = Jaterní sarkoidóza zdroj = http://granuloma.homestead.com/ datum = 2011-11-01 autor = Yale Rosen, M.D. licence = {{Zpracovat doplňit licenci}} }} Kategorie:Patologie Kategorie:Vnitřní lékařství Kategorie:Obrázky

You cannot overwrite this file.

File usage

The following page uses this file:

- Sarkoidóza jater

Metadata

This file contains additional information, probably added from the digital camera or scanner used to create or digitize it.

If the file has been modified from its original state, some details may not fully reflect the modified file.