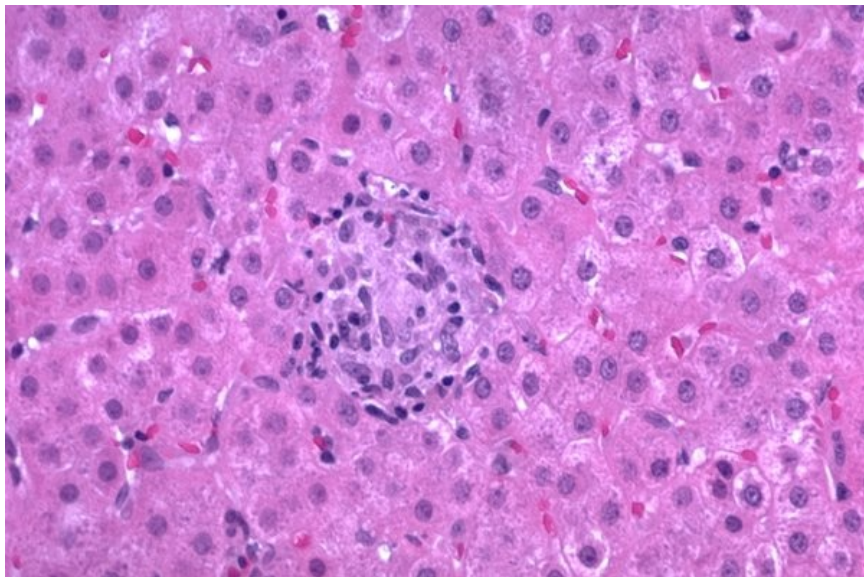


# Soubor:Sarcoidosis extrapulmonary62.jpg



This image can contain annotations.  
Move the mouse over the image to display.  
No higher resolution available.

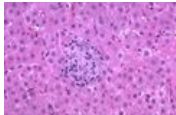
Sarcoidosis\_extrapulmonary62.jpg (600 × 398 pixels, file size: 65 KB, MIME type: image/jpeg)

 **Open in Media Viewer** 

<b>Popis</b>	Sarkoidóza jater - mikroobrázek
<b>Zdroj</b>	<a href="http://granuloma.homestead.com/sarcoidosis_extrapulmonary.html">http://granuloma.homestead.com/sarcoidosis_extrapulmonary.html</a>
<b>Datum</b>	<i>nezadáno</i>
<b>Autor</b>	Yale Rosen, M.D.
<b>Licence</b>	Creative Commons NonCommercial-NoDerivs 3.0 Unported (CC BY-NC-ND 3.0) ( <a href="http://creativecommons.org/licenses/by-nc-nd/3.0/">http://creativecommons.org/licenses/by-nc-nd/3.0/</a> )

## File history

Click on a date/time to view the file as it appeared at that time.

	Date/Time	Thumbnail	Dimensions	User	Comment
current	<b>13:19, 1 November 2011</b>		600 × 398 (65 KB)	OK (talk   contribs)	{{Soubor  popis = Sarkoidóza jater - mikroobrázek  zdroj = <a href="http://granuloma.homestead.com/sarcoidosis_extrapulmonary.html">http://granuloma.homestead.com/sarcoidosis_extrapulmonary.html</a>  datum =  autor = Yale Rosen, M.D.  licence = {{Zpracovat doplňit licenci}} }} Kategorie:patologie Kategorie:hepatologie [

You cannot overwrite this file.

## File usage

The following page uses this file:

- Sarkoidóza jater

## Metadata

This file contains additional information, probably added from the digital camera or scanner used to create or digitize it.

If the file has been modified from its original state, some details may not fully reflect the modified file.