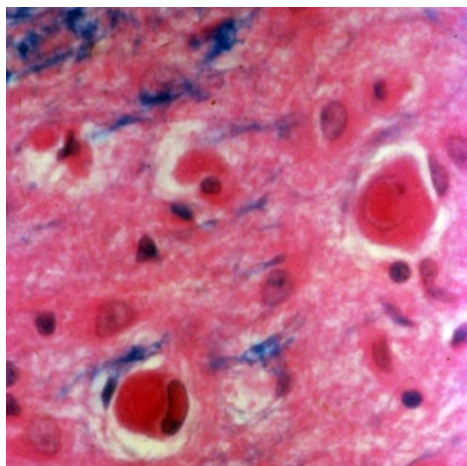


# Soubor:Subakutní sklerózující panencefalitida.jpg



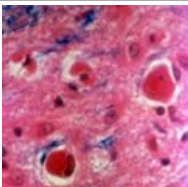
No higher resolution available.

Subakutní\_sklerózující\_panencefalitida.jpg (300 × 300 pixels, file size: 36 KB, MIME type: image/jpeg)

<b>Popis</b>	Subakutní sklerózující panencefalitida - histologie
<b>Zdroj</b>	<a href="http://www.flickr.com/photos/ajc1/2422651229/">http://www.flickr.com/photos/ajc1/2422651229/</a>
<b>Datum</b>	2008-04-18
<b>Autor</b>	AJC1
<b>Licence</b>	CC-BY-NC 2.0 en ( <a href="http://creativecommons.org/licenses/by-nc/2.0/deed.en">http://creativecommons.org/licenses/by-nc/2.0/deed.en</a> )

## File history

Click on a date/time to view the file as it appeared at that time.

	Date/Time	Thumbnail	Dimensions	User	Comment
current	<b>19:15, 22 March 2010</b>		300 × 300 (36 KB)	Mvejr (talk   contribs)	{ {Soubor  popis = Subakutní sklerózující panencefalitida - histologie  zdroj = <a href="http://www.flickr.com/photos/ajc1/2422651229/">http://www.flickr.com/photos/ajc1/2422651229/</a>  datum = 2008-04-18  autor = AJC1  licence = { {bez licence}} } } Kategorie:Neurologie Kategorie:mikrobiologie [[Kategor

You cannot overwrite this file.

## File usage

The following 2 pages use this file:

- Subakutní sklerózující panencefalitida
- Virové infekce nervového systému

## Metadata

This file contains additional information, probably added from the digital camera or scanner used to create or digitize it.

If the file has been modified from its original state, some details may not fully reflect the modified file.

