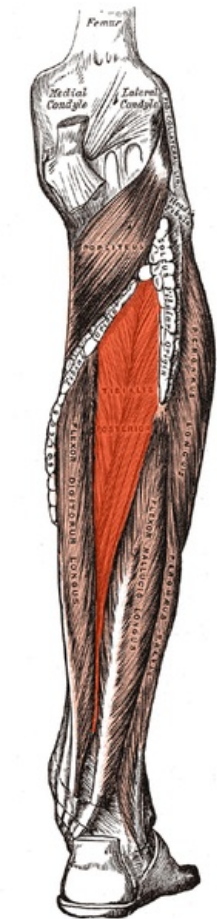


Soubor:Tibialis posterior.png



Size of this preview: 148 × 600 pixels.

Original file (222 × 900 pixels, file size: 139 KB, MIME type: image/png)

 **Open in Media Viewer** 

This file is from Wikimedia Commons and may be used by other projects. The description on its file description page there is shown below.

Popis
kartičky Tibialis posterior

Summary

Description	Tibialis posterior muscle
Source	Gray439.png
Author	modified by Uwe Gille
Other versions	Gray439.png

Licensing



Public
domain

*This media file is in the **public domain** in the United States. This applies to U.S. works where the copyright has expired, often because its first publication occurred prior to January 1, 1928, and if not then due to lack of notice or renewal. See this page for further explanation.*

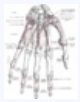

United
States



This image might not be in the public domain outside of the United States; this especially applies in the countries and areas that do not apply the rule of the shorter term for US works, such as Canada, Mainland China (not Hong Kong or Macao), Germany, Mexico, and Switzerland. The creator and year of publication are essential information and must be provided. See Wikipedia:Public domain and Wikipedia:Copyrights for more details.

Unless stated otherwise, this image is from the 20th U.S. edition of *Gray's Anatomy of the Human Body*, originally published in 1918 and therefore lapsed into the public domain. A copy of Gray's Anatomy can be found on Bartleby (<http://www.bartleby.com/107/>) and also on Yahoo! (<http://education.yahoo.com/reference/gray/>).



This image is in the **public domain** because it is a mere mechanical scan or photocopy of a public domain original, or – from the available evidence – is so similar to such a scan or photocopy that no copyright protection can be expected to arise. The original itself is in the public domain for the following reason:



This work is in the **public domain** in its country of origin and other countries and areas where the copyright term is the author's **life plus 100 years or fewer**.

This work is in the **public domain** in the United States because it was published (or registered with the U.S. Copyright Office) before January 1, 1928.

This file has been identified as being free of known restrictions under copyright law, including all related and neighboring rights. (<https://creativecommons.org/publicdomain/mar/1.0/deed.en>)

This tag is designed for use where there may be a need to assert that any enhancements (eg brightness, contrast, colour-matching, sharpening) are in themselves insufficiently creative to generate a new copyright. It can be used where it is unknown whether any enhancements have been made, as well as when the enhancements are clear but insufficient. For known raw unenhanced scans you can use an appropriate `{{PD-old}}` tag instead. For usage, see Commons:When to use the PD-scan tag.



Note: This tag applies to scans and photocopies only. For photographs of public domain originals taken from afar, `{{PD-Art}}` may be applicable. See Commons:When to use the PD-Art tag.

}}

File history

Click on a date/time to view the file as it appeared at that time.

	Date/Time	Thumbnail	Dimensions	User	Comment
current	00:50, 22 August 2007		222 × 900 (139 KB)	wikimediacommons>Uwe Gille	{{Information Description=Tibialis posterior muscle Source=Gray439.png Date= Author=modified by Uwe Gille Permission= other_versions=Gray439.png }} {{Gray's Anatomy plate}} Category:Gray's Anatomy plates with help Category:Muscles }} == Licen

File usage

The following 2 pages use this file:

- Musculus tibialis posterior
- Svaly dolní končetiny (tabulka)