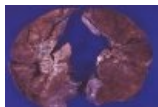

Soubor:Tn sarcoid gross lung YR1224-2.jpg



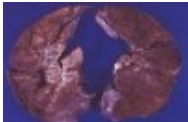
No higher resolution available.

Tn_sarcoid_gross_lung_YR1224-2.jpg (100 × 66 pixels, file size: 2 KB, MIME type: image/jpeg)

| | |
|----------------|--|
| Popis | Bilateral hilar lymphadenopathy |
| Zdroj | http://granuloma.homestead.com/sarcoidosis_gross.html |
| Datum | <i>nezadáno</i> |
| Autor | Yale Rosen, M.D. |
| Licence | Creative Commons NonCommercial-NoDerivs 3.0 Unported (CC BY-NC-ND 3.0) (http://creativecommons.org/licenses/by-nc-nd/3.0/) |

File history

Click on a date/time to view the file as it appeared at that time.

| | Date/Time | Thumbnail | Dimensions | User | Comment |
|---------|-------------------------------|---|-----------------|----------------------|---|
| current | 13:03, 18 October 2011 |  | 100 × 66 (2 KB) | OK (talk contribs) | {{Soubor popis = Bilateral hilar lymphadenopathy zdroj = http://granuloma.homestead.com/sarcoidosis_gross.html datum = autor = Yale Rosen, M.D. licence = {{Zpracovat doplnit licenci}} }} Kategorie:patologie Kategorie:Obrázky |

You cannot overwrite this file.

File usage

The following 2 pages use this file:

- Sarkoidóza (patologie)
- Sarkoidóza lymfatického systému

Metadata

This file contains additional information, probably added from the digital camera or scanner used to create or digitize it.

If the file has been modified from its original state, some details may not fully reflect the modified file.