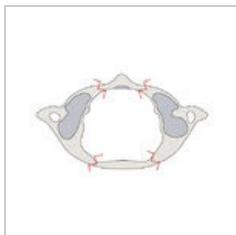


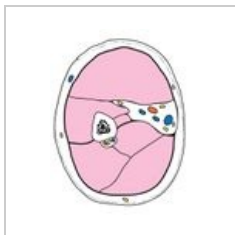
# Uživatel: L. Hoznauerová / Pískoviště / Obrázky

Přehled mých obrázků

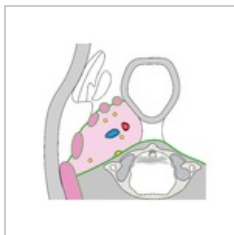## Anatomie



Jeffersonova zlomenina (překresleno)

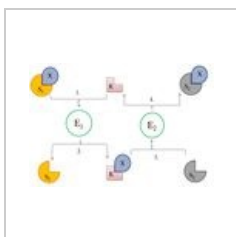


Regio brachialis

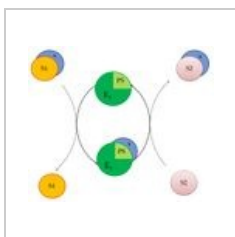


Spatium parapharyngeum

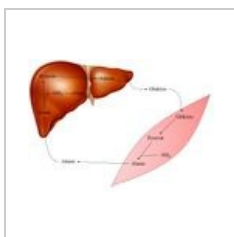
## Biochemie



Funkce koenzymů (překresleno)



Funkce prostetických skupin (překresleno)



Glukózo-alaninový cyklus

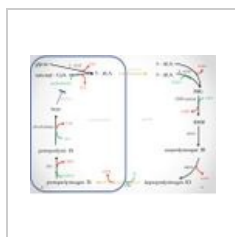


Schéma biosyntézy hemu


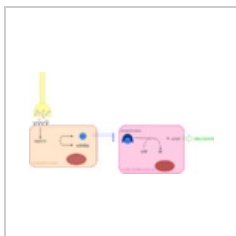



Schéma metabolismu fructosy



Signalizace NO

## Fyziologie



Disociační křivka CO<sub>2</sub>

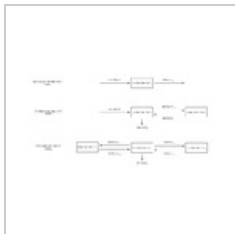
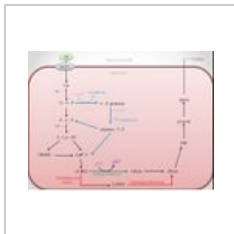
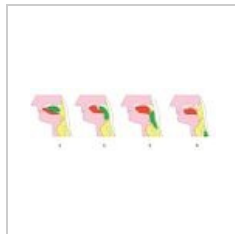


Schéma kompartmentového modelu




Metabolismus erytrocytu



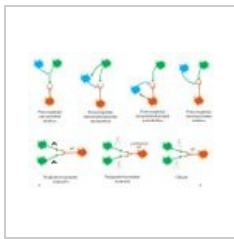
Polykání



Postsynaptické potenciály



Price-Jonesova křivka



Regulace okruhů

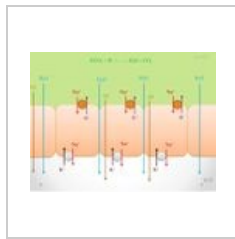
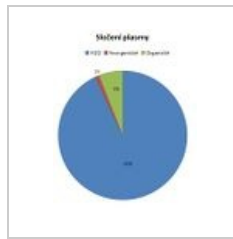



Schéma zahušťování žluči

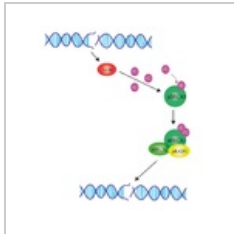


Složení plasmy

## Genetika



Evoluce lidského druhu



Funkce BRCA



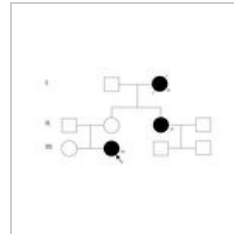


Schéma genové vazby



Rb mutace



Rodokmen BRCA




Schéma translokace u Burkittova lymfomu

## Mikrobiologie

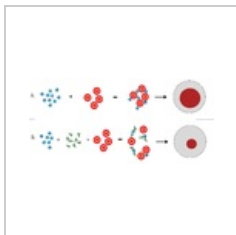
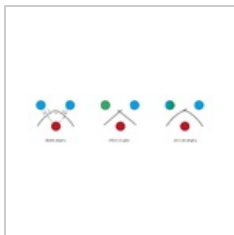


Schéma HIT



Výsledky precipitace v gelu

## Ortopedie

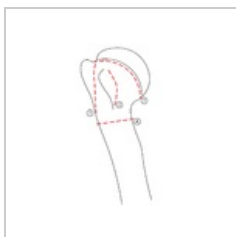

Schéma lomných linií humer (překresleno)

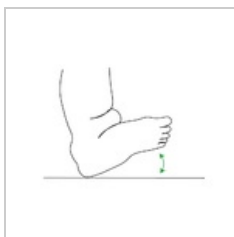
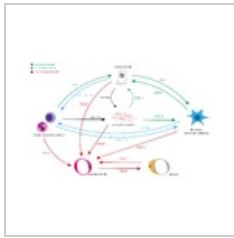
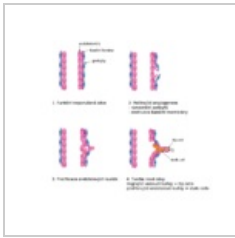
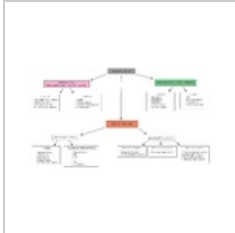


Schéma pes calcaneovalgus

## Patobiochemie



## Patofyziologie



## Různé

