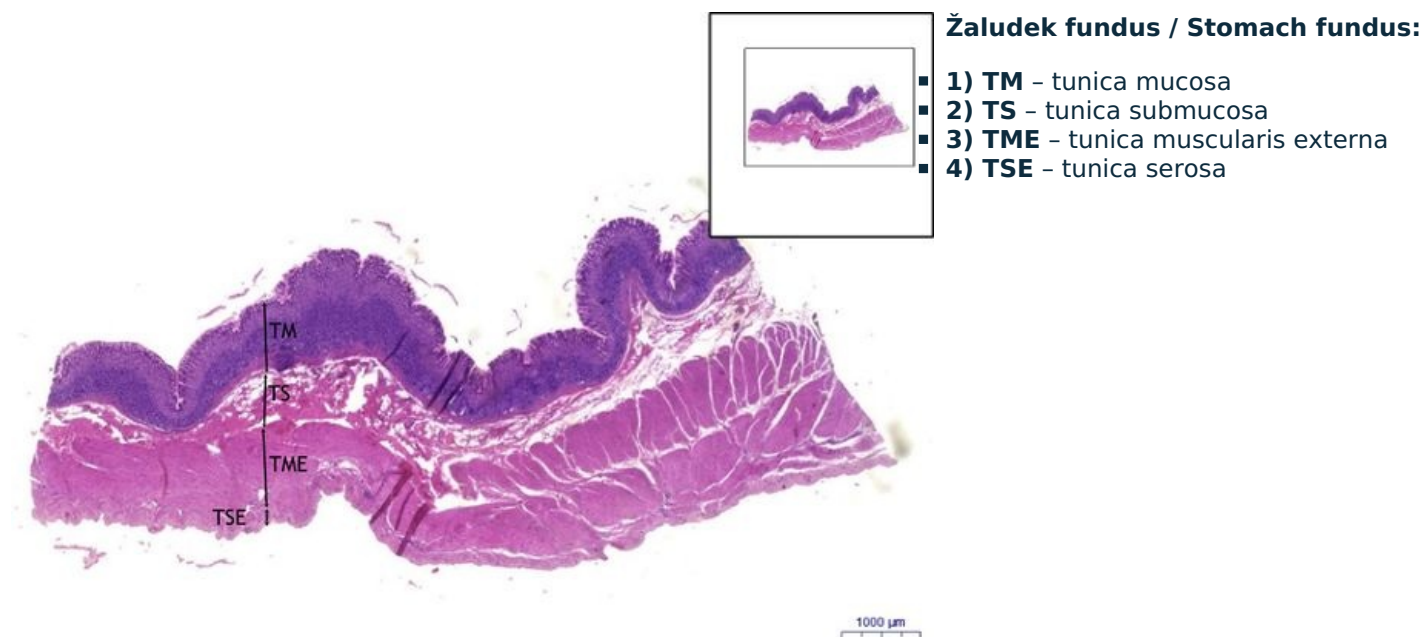
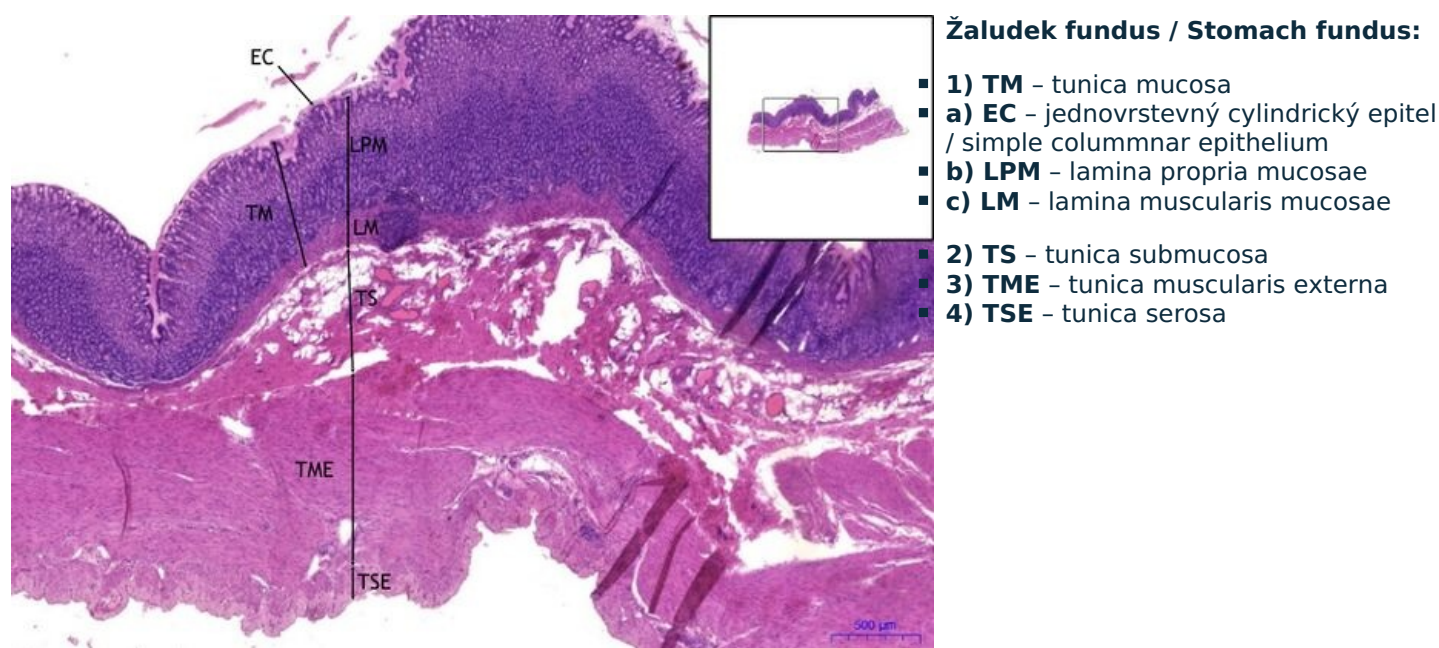


Žaludek fundus / Stomach fundus - HE

Žaludek fundus / Stomach fundus, HE 0,9x



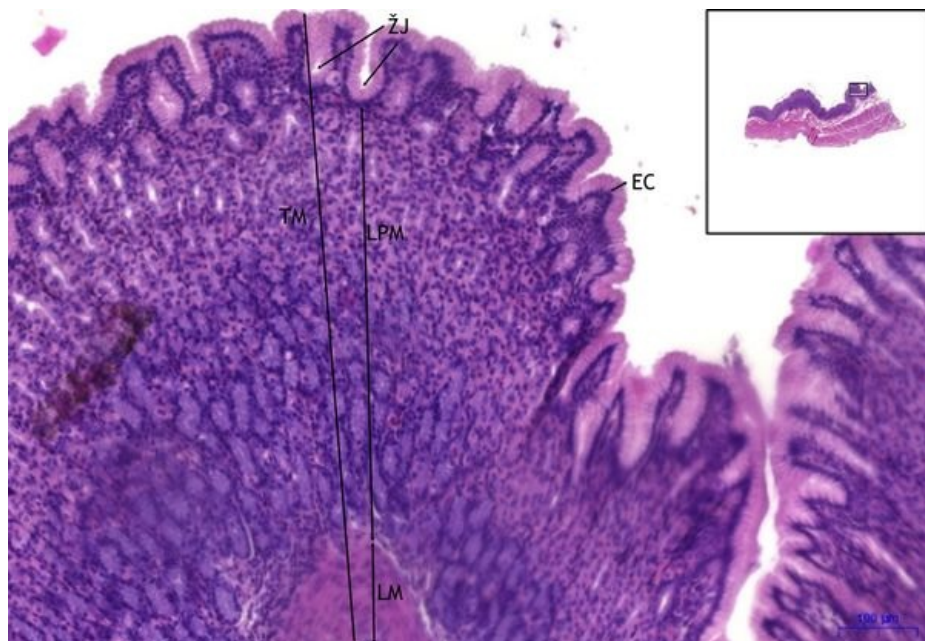
Žaludek fundus / Stomach fundus, HE 2x



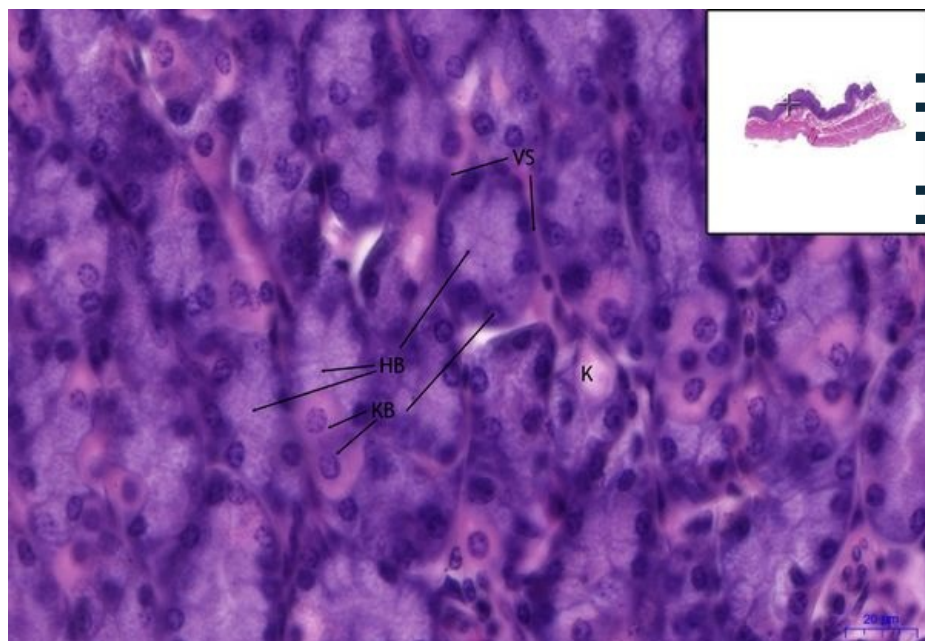
Žaludek fundus / Stomach fundus, HE 8,8x

Žaludek fundus / Stomach fundus:

- 1) **TM** - tunica mucosa
- a) **EC** - jednovrstevný cylindrický epitel / simple columnar epithelium
- b) **LPM** - lamina propria mucosae
- c) **ŽJ** - žaludeční jamky / gastric pits (foveolae gastricae)
- d) **LM** - lamina muscularis mucosae



Žaludek fundus / Stomach fundus, HE 40x



Žaludek fundus / Stomach fundus:

- 1) **TM** - tunica mucosa
- a) **HB** - hlavní buňky / chief cells
- b) **KB** - krycí buňky / parietal cells
- 2) **VS** - vazivová septa / fibrous septa
- 3) **K** - kapilára/capillary

Navigace

Navigace: Epitely / Epithelial tissue

← Preparát č. 16 | Seznam preparátů | Preparát č. 18 →

Navigace: Zažívací systém / Digestive tract

← Preparát Z10 | Seznam preparátů | Preparát Z11* →