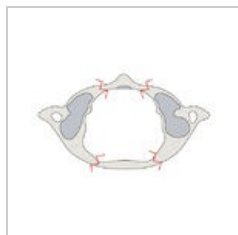



Kategorie:Chirurgická schémata

Media in category "Chirurgická schémata"

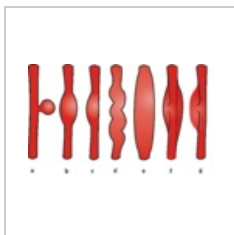
The following 55 files are in this category, out of 55 total.



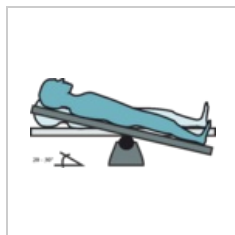
1 image.jpeg
4,000 × 2,457; 809 KB



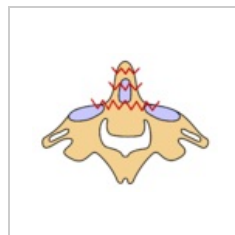
Amplatzer.png
6,945 × 1,244; 677 KB



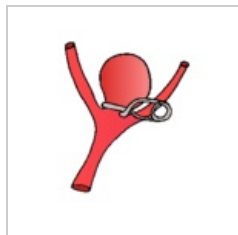Aneurysmata.png
3,116 × 1,954; 1.05 MB




Anti-Trendelenbu...
2,985 × 1,449; 245 KB



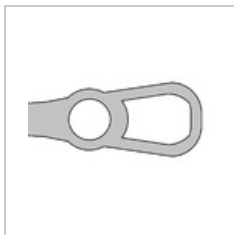
C2 zlomenina.svg
1,440 × 1,080; 7 KB



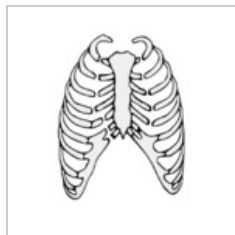Clipping aneurys...
279 × 286; 14 KB



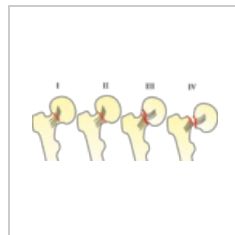
Coiling aneurysm...
418 × 396; 50 KB



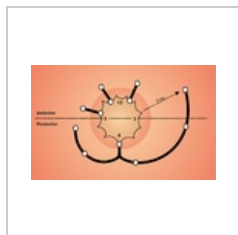Drzadlo-haku.png
1,072 × 656; 14 KB



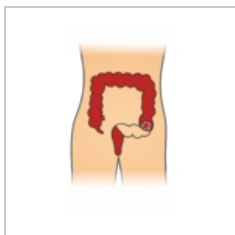
Dvířková zlomeni...
379 × 426; 63 KB



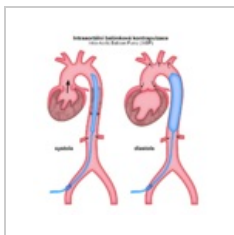
Garden.png
3,549 × 1,501; 394 KB



Goodsall.png
800 × 493; 339 KB



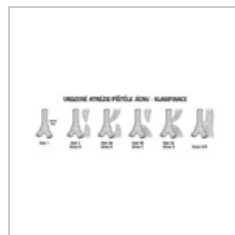Hartmann.png
1,496 × 2,479; 245 KB



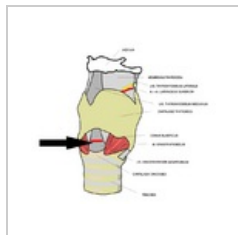
IABP.png
800 × 840; 67 KB



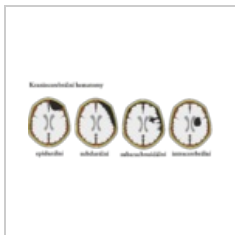
Image.jpeg
1,440 × 1,080; 259 KB



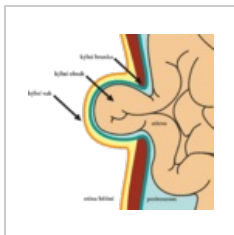
Jicen klasifikace...
1,200 × 400; 51 KB



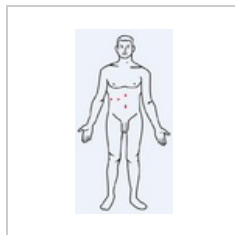
Koniotomie.png
678 × 600; 152 KB



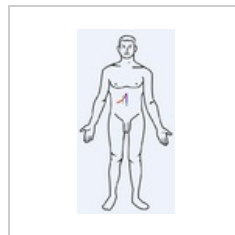
Kraniocerebrální ...
4,346 × 1,848; 997 KB



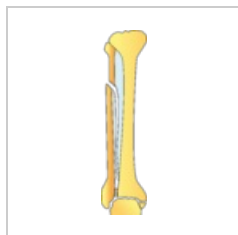
Kýla.png
1,735 × 1,644; 262 KB



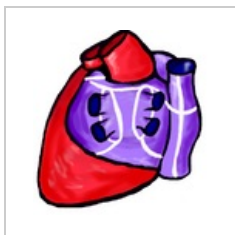Laparoskopie.PNG
331 × 630; 35 KB




LaparotomieCHC...
331 × 630; 35 KB



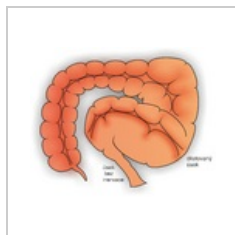
Maisonneuve.png
1,152 × 4,782; 283 KB



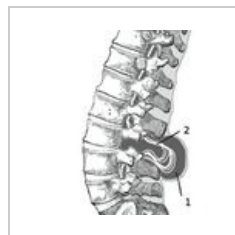
Maze.png
451 × 474; 258 KB



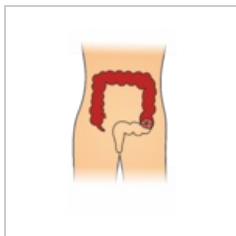
Medziobratlovýi...
410 × 336; 32 KB



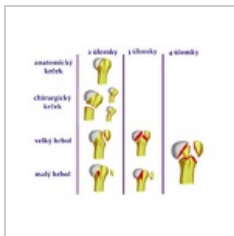
Megacolon.png
3,351 × 2,708; 2.35 MB



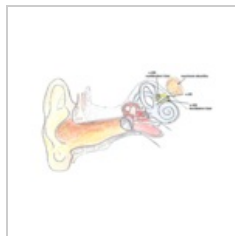
Meningomyelocel...
300 × 335; 22 KB



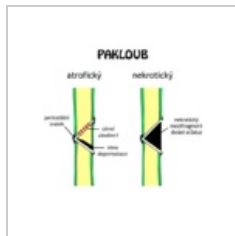
Miles.png
1,497 × 2,527; 243 KB



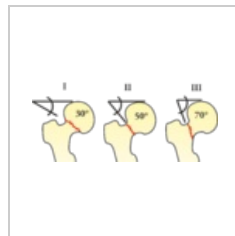
Neer2.png
651 × 546; 123 KB



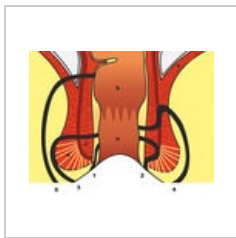
Neurinom akusti...
605 × 388; 205 KB



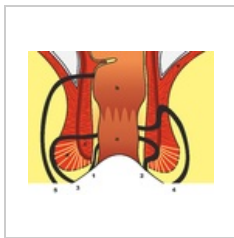
Pakloub.png
640 × 542; 27 KB



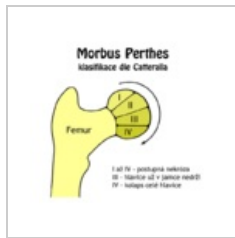
Pauwels I-III.png
2,977 × 1,296; 232 KB



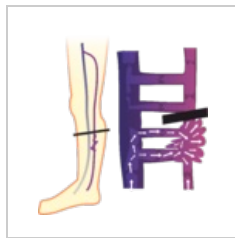Periprokt.jpg
900 × 698; 150 KB



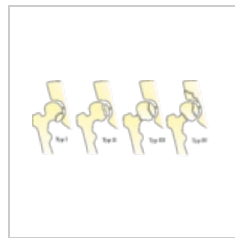
Periprokt.png
2,251 × 1,747; 1.32 MB



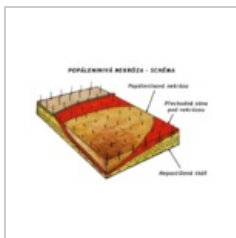
Perthes Catterall...
640 × 640; 29 KB



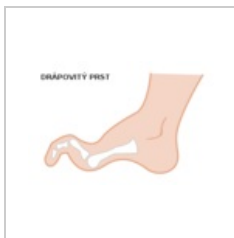Perthes.png
2,055 × 2,236; 261 KB



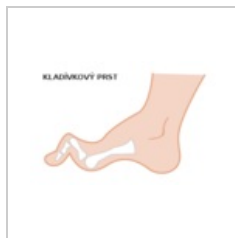Pipkin.png
5,045 × 2,257; 625 KB



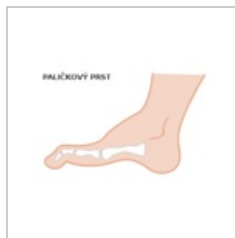Popalenina sche...
1,166 × 797; 215 KB



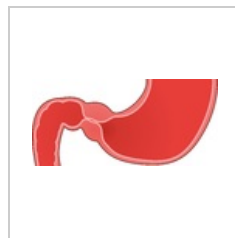
Prst drapovity.svg
360 × 240; 6 KB



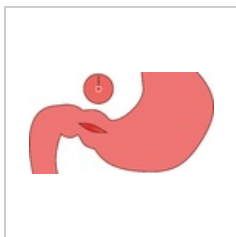
Prst kladivkovy.svg
360 × 240; 6 KB



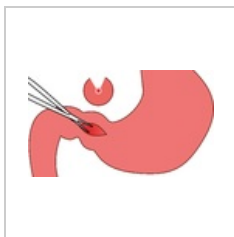
Prst palickovy.svg
360 × 240; 6 KB



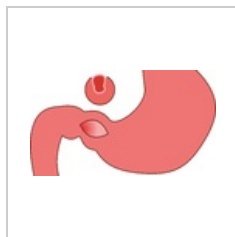
Pylorostenóza.png
2,706 × 1,255; 213 KB



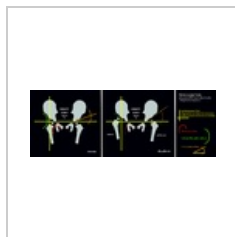
Pylorostenóza2.p...
2,700 × 1,479; 130 KB




Pylorostenóza3.p...
2,711 × 1,551; 182 KB



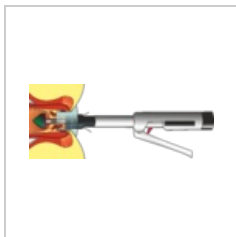
Pylorostenóza4.p...
2,700 × 1,521; 143 KB



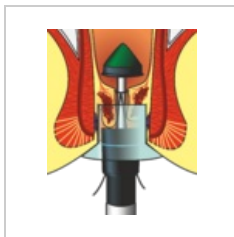
Rtgdysplazie.png
3,000 × 1,082; 599 KB




SalterHarris.jpg
800 × 600; 39 KB



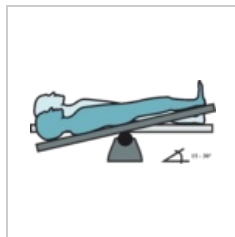
Stapler-celek.png
5,484 × 2,213; 1.19 MB



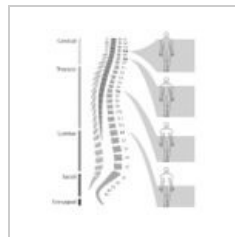Stapler-detail.png
1,725 × 2,122; 675 KB



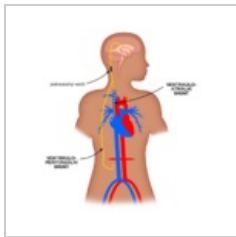
Tangencialni nek...
900 × 1,200; 248 KB



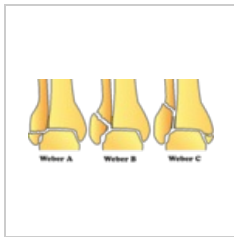Trendelenburg.png
3,028 × 1,373; 192 KB



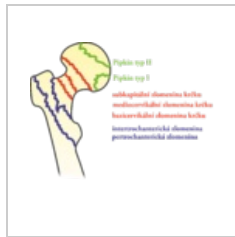Vertikalni topogr...
496 × 576; 76 KB



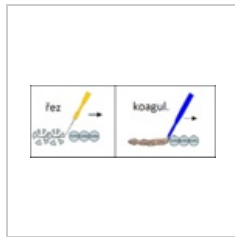
VP-VA Shunt cs.p...
1,024 × 1,024; 69 KB



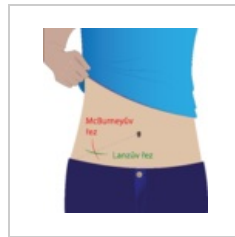WeberABC.png
3,602 × 1,664; 376 KB



Zlomeniny proxi...
1,925 × 1,639; 257 KB



Řez, koagul.png
1,194 × 466; 52 KB



Řezy.png
2,758 × 3,084; 515 KB