

Kategorie:Histopatologické preparáty

Subcategories

This category has only the following subcategory.

Y

► Yale Rosen (137 F)

Pages in category "Histopatologické preparáty"

This category contains only the following page.


M

- Portál:Modul Obecné základy patologie a patofyziologie (3. LF UK)

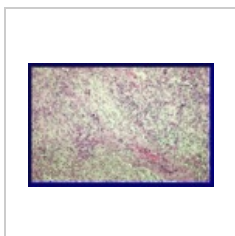
Media in category "Histopatologické preparáty"

The following 200 files are in this category, out of 548 total.

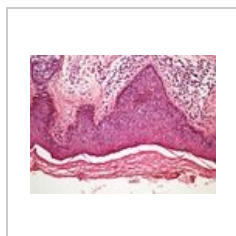
(previous page) (next page)



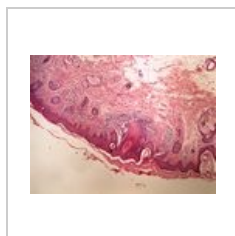
002 Transmuráln...
355 × 235; 70 KB



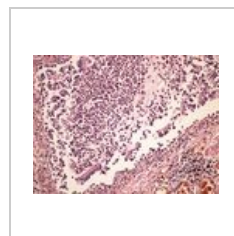
003 Granulomató...
357 × 239; 82 KB



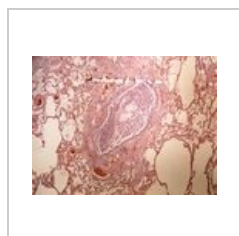
Actinic keratosis ...
2,560 × 1,920;
2.75 MB



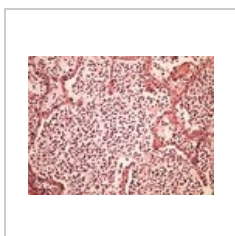
Actinic keratosis ...
2,560 × 1,920; 3.1
MB



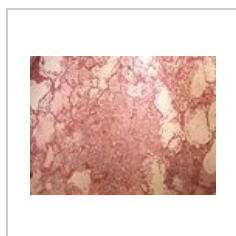
Acute bronchitis ...
2,560 × 1,920;
3.08 MB



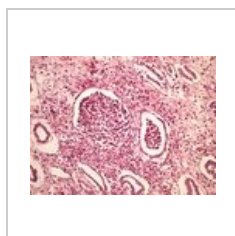Acute bronchitis ...
2,560 × 1,920;
3.39 MB



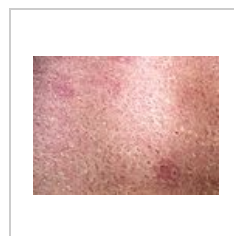
Acute bronchopn...
2,560 × 1,920;
3.07 MB



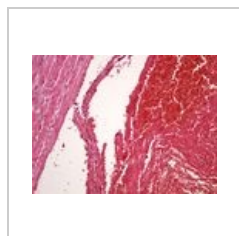
Acute bronchopn...
2,560 × 1,920;
3.61 MB



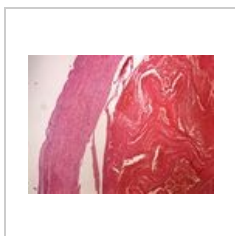
Acute pyelonefrit...
2,560 × 1,920;
3.27 MB




Acute pyelonefrit...
2,560 × 1,920;
3.61 MB



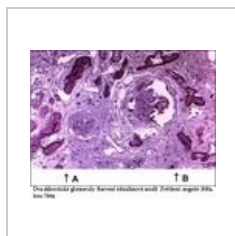
Acute thrombosis...
2,560 × 1,920;
2.59 MB



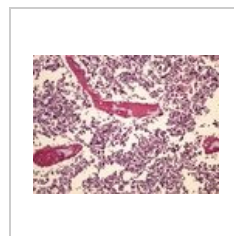
Acute thrombosis...
2,560 × 1,920;
3.04 MB



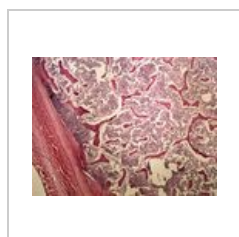
Alportův syndro...
352 × 353; 78 KB



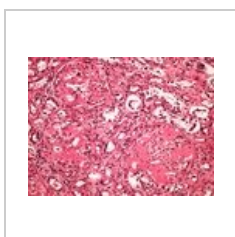
Alportův syndro...
352 × 282; 76 KB



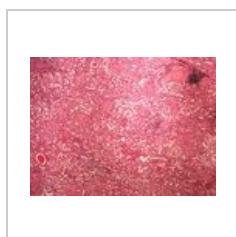AML 20x.jpg
2,560 × 1,920;
2.86 MB



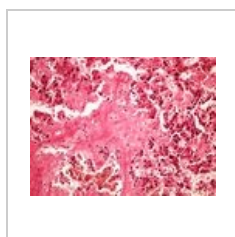AML 4x.jpg
2,560 × 1,920;
3.68 MB



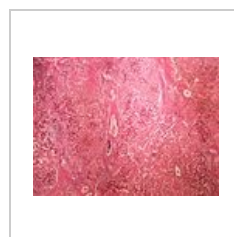Amyloidosis kidn...
2,560 × 1,920;
2.98 MB



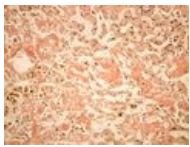
Amyloidosis kidn...
2,560 × 1,920;
3.69 MB



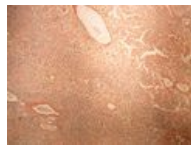Amyloidosis liver ...
2,560 × 1,920;
2.85 MB



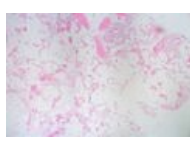
Amyloidosis liver ...
2,560 × 1,920;
3.62 MB



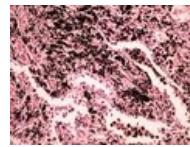
Amyloidosis liver ...
2,560 × 1,920; 2.9 MB



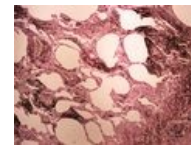
Amyloidosis liver ...
2,560 × 1,920; 2.97 MB



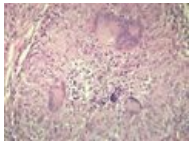
Angiolipoma.jpg
1,726 × 1,149; 737 KB



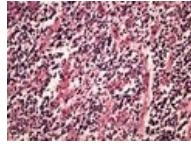
Anthracosis antr...
2,560 × 1,920; 2.81 MB



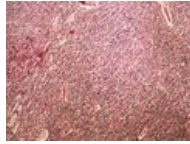
Anthracosis antr...
2,560 × 1,920; 3.17 MB



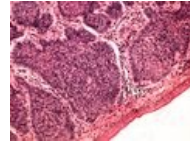
Apoptóza u sarko...
600 × 443; 107 KB



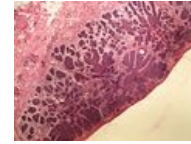
Astrocytoma 20x...
2,560 × 1,920; 2.84 MB



Astrocytoma 4x.jpg
2,560 × 1,920; 4.26 MB



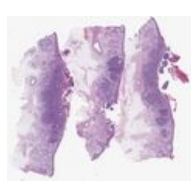
Basalioma 20x.jpg
2,560 × 1,920; 2.45 MB



Basalioma 4x.jpg
2,560 × 1,920; 3.08 MB



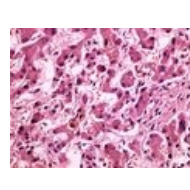
Basalzellkarzino...
390 × 1,084; 134 KB



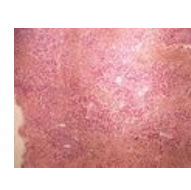Basalzellkarzino...
1,799 × 1,600; 1.08 MB



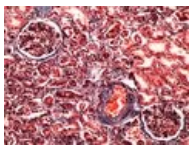
BCC superfiziell 3...
240 × 669; 28 KB



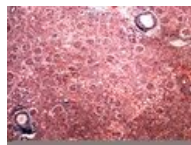
Bilirubin 40x.jpg
2,560 × 1,920; 2.75 MB



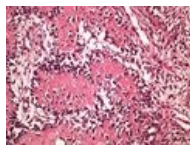
Bilirubin 4x.jpg
2,560 × 1,920; 3.72 MB



Blue trichrome (k...
2,560 × 1,920; 2.85 MB



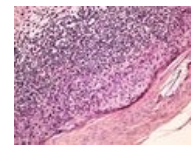
Blue trichrome (k...
2,560 × 1,920; 4 MB



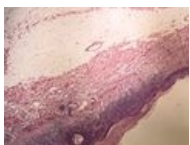Bone fracture he...
2,560 × 1,920; 3.02 MB



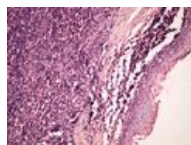
Bone fracture he...
2,560 × 1,920; 3.59 MB



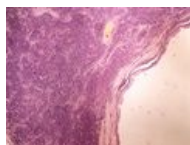
Bowen disease B...
2,560 × 1,920; 3.06 MB



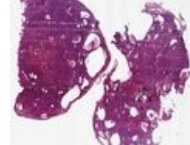
Bowen disease B...
2,560 × 1,920; 3.04 MB



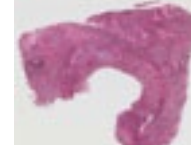Branchial cleft cy...
2,560 × 1,920; 2.89 MB



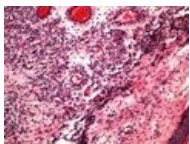
Branchial cleft cy...
2,560 × 1,920; 3.25 MB



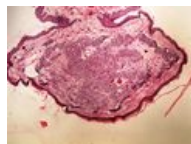
Brenner Tumor O...
1,560 × 1,470; 891 KB



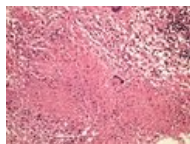
Bronchogenni tu...
69 × 60; 11 KB



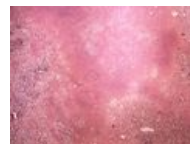Capillary haeman...
2,560 × 1,920; 2.8 MB



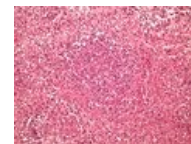
Capillary haeman...
2,560 × 1,920; 3.06 MB



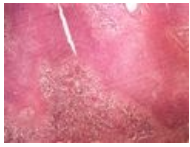Caseous necrosis...
2,560 × 1,920; 3.26 MB



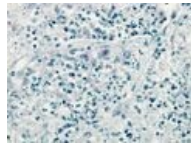
Caseous necrosis...
2,560 × 1,920; 3.71 MB



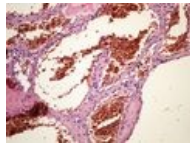
Caseous pneumo...
2,560 × 1,920; 3.37 MB



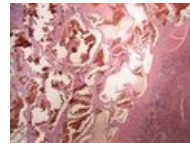
Caseous pneumo...
2,560 × 1,920;
3.86 MB



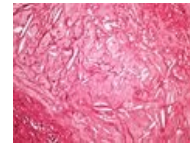
Caseous pneumo...
2,560 × 1,920;
2.35 MB



Cavernous haem...
2,560 × 1,920;
2.66 MB



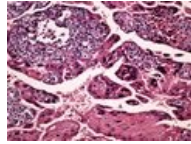
Cavernous haem...
2,560 × 1,920;
3.25 MB



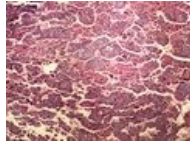
Cholesterol clefts...
2,560 × 1,920;
3.02 MB



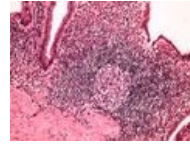
Cholesterol clefts...
2,560 × 1,920;
3.35 MB



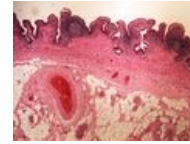
Choriocarcinoma ...
2,560 × 1,920;
2.61 MB



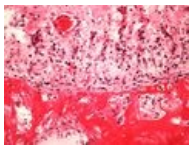
Choriocarcinoma ...
2,560 × 1,920;
3.75 MB



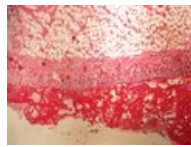
Chronic cholecys...
2,560 × 1,920;
2.84 MB



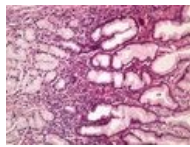
Chronic cholecys...
2,560 × 1,920;
3.06 MB



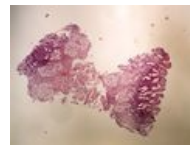
Chronic fibrinous ...
2,560 × 1,920;
2.76 MB



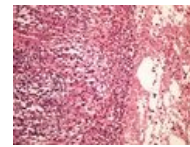
Chronic fibrinous ...
2,560 × 1,920;
2.95 MB



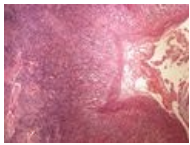
Chronic gastritis ...
2,560 × 1,920;
2.94 MB



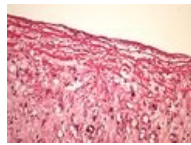
Chronic gastritis ...
2,560 × 1,920;
2.61 MB



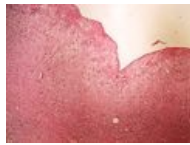Chronic lung abs...
2,560 × 1,920;
3.17 MB



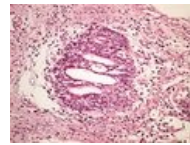
Chronic lung abs...
2,560 × 1,920;
3.81 MB



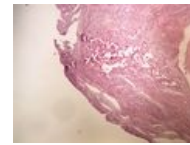
Chronic skin ulce...
2,560 × 1,920;
2.76 MB



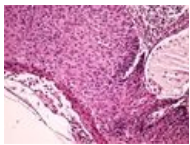
Chronic skin ulce...
2,560 × 1,920;
3.18 MB



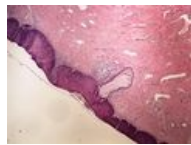
Chronic urocystiti...
2,560 × 1,920; 3.1
MB



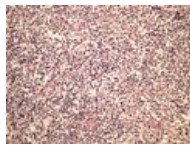
Chronic urocystiti...
2,560 × 1,920;
3.08 MB



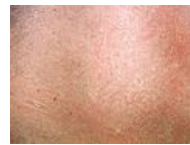CIN 20x.jpg
2,560 × 1,920;
2.78 MB



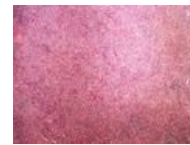CIN 4x.jpg
2,560 × 1,920;
3.22 MB



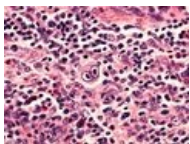
Classic Hodgkin l...
2,560 × 1,920;
3.23 MB



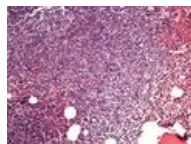Classic Hodgkin l...
2,560 × 1,920;
3.62 MB



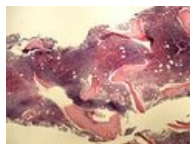Classic Hodgkin l...
2,560 × 1,920; 4.5
MB



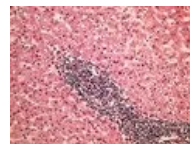
Classic Hodgkin l...
2,560 × 1,920;
2.48 MB



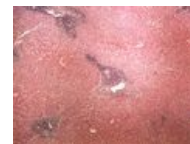CLL bone marrow...
2,560 × 1,920; 3.3
MB



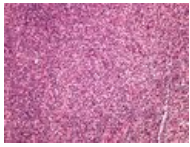
CLL bone marrow...
2,560 × 1,920;
3.18 MB



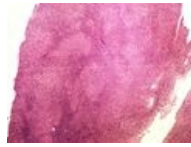
CLL liver infiltrac...
2,560 × 1,920;
3.58 MB



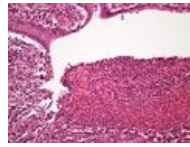
CLL liver infiltrac...
2,560 × 1,920;
3.86 MB



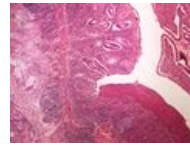
CLL SCL 20x.jpg
2,560 × 1,920;
3.53 MB



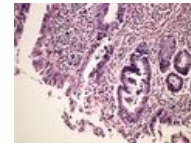
CLL SCL 4x.jpg
2,560 × 1,920;
4.12 MB



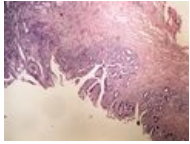
Crohn's disease C...
2,560 × 1,920;
2.68 MB



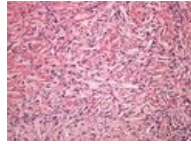
Crohn's disease C...
2,560 × 1,920;
3.49 MB



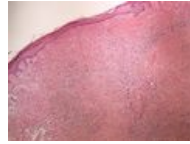DALM 20x.jpg
2,560 × 1,920; 2.9
MB



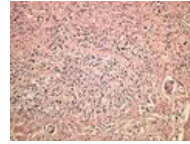
DALM 4x.jpg
2,560 × 1,920;
3.35 MB



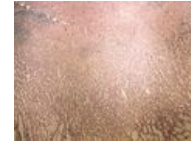Dermatofibroma ...
2,560 × 1,920;
3.18 MB



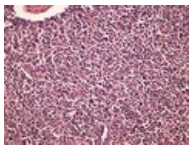
Dermatofibroma ...
2,560 × 1,920;
3.32 MB



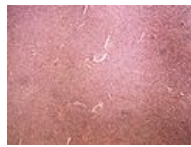
Diffuse carcinom...
2,560 × 1,920;
3.18 MB



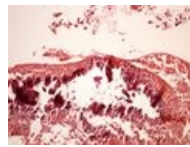
Diffuse carcinom...
2,560 × 1,920;
3.76 MB



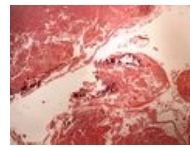DLBCL 20x.jpg
2,560 × 1,920;
3.14 MB



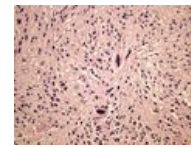
DLBCL 4x.jpg
2,560 × 1,920;
4.59 MB



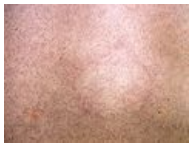Dystrophic calcifi...
2,560 × 1,920;
2.49 MB



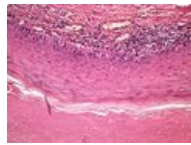
Dystrophic calcifi...
2,560 × 1,920;
3.03 MB



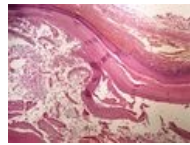
Ependymoma 20...
2,560 × 1,920;
3.02 MB



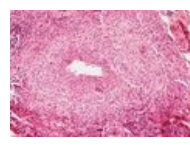
Ependymoma 4x....
2,560 × 1,920;
3.38 MB



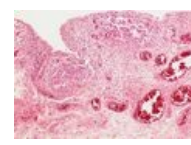
Epidermoid cyst ...
2,560 × 1,920;
2.93 MB



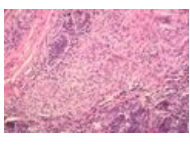
Epidermoid cyst ...
2,560 × 1,920;
3.26 MB



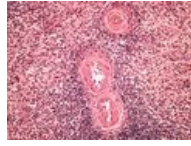
Extrapulmonální ...
533 × 364; 98 KB



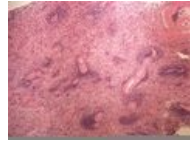Extrapulmonální ...
533 × 370; 92 KB



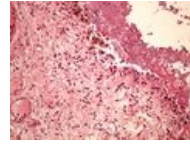
Extrapulmonální ...
600 × 398; 88 KB



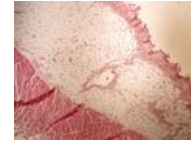Fibrinoid dystrop...
2,560 × 1,920;
3.44 MB



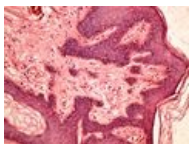
Fibrinoid dystrop...
2,560 × 1,920; 4
MB



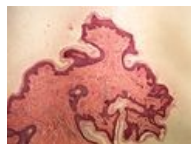Fibrinous pericar...
2,560 × 1,920;
3.04 MB



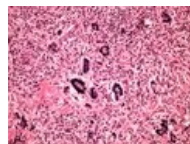
Fibrinous pericar...
2,560 × 1,920;
2.85 MB



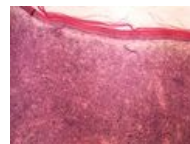Fibroepithelial po...
2,560 × 1,920;
2.81 MB



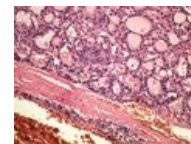
Fibroepithelial po...
2,560 × 1,920;
2.77 MB



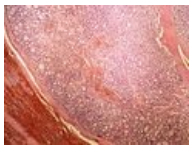
Fibroxanthoma 2...
2,560 × 1,920;
3.04 MB



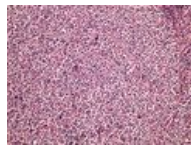
Fibroxanthoma 4...
2,560 × 1,920;
3.16 MB



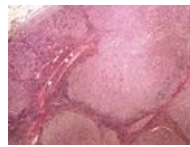
Follicular adenom...
2,560 × 1,920;
2.95 MB



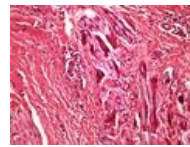
Follicular adenom...
2,560 × 1,920;
3.72 MB



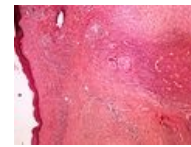
Follicular lympho...
2,560 × 1,920;
3.43 MB



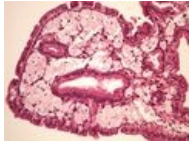Follicular lympho...
2,560 × 1,920;
4.71 MB



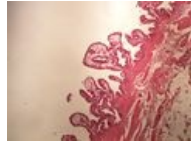
Foreign body gra...
2,560 × 1,920;
2.92 MB



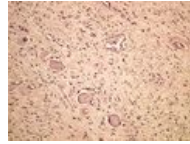
Foreign body gra...
2,560 × 1,920;
3.83 MB



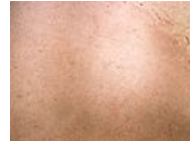Gallbladder chole...
2,560 × 1,920;
2.78 MB



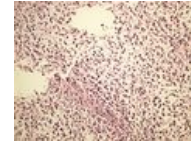
Gallbladder chole...
2,560 × 1,920;
2.69 MB



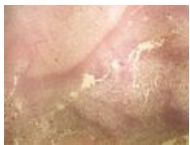Ganglioneuroma ...
2,560 × 1,920;
3.11 MB



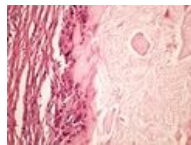
Ganglioneuroma ...
2,560 × 1,920;
3.15 MB



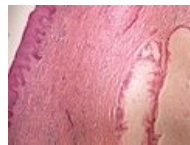Glioblastoma 20x...
2,560 × 1,920;
2.98 MB



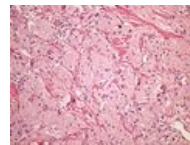
Glioblastoma 4x.j...
2,560 × 1,920;
3.65 MB



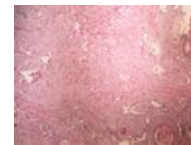Gout dnave tofy ...
2,560 × 1,920;
2.69 MB



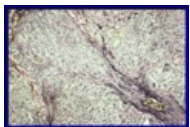Gout dnave tofy ...
2,560 × 1,920;
3.47 MB



Granular cell tum...
2,560 × 1,920;
3.16 MB



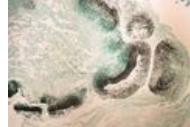Granular cell tum...
2,560 × 1,920;
3.42 MB



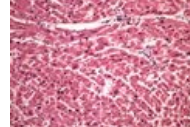
Granulomatózní ...
358 × 238; 82 KB



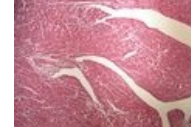Grocott (mycosis...
2,560 × 1,920;
3.04 MB



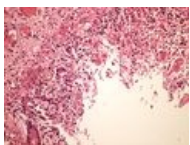
Grocott (mycosis...
2,560 × 1,920;
2.87 MB



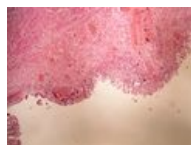HE (myocardium)...
2,560 × 1,920;
2.89 MB



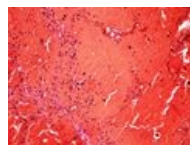
HE (myocardium)...
2,560 × 1,920;
3.26 MB



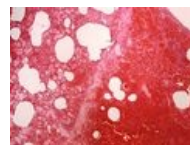
Hemorrhagic nec...
2,560 × 1,920;
2.94 MB



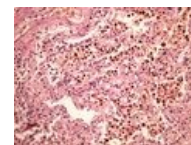
Hemorrhagic nec...
2,560 × 1,920;
3.11 MB



Hemorrhagic nec...
2,560 × 1,920; 2.4
MB



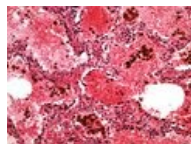
Hemorrhagic nec...
2,560 × 1,920;
3.04 MB



Hemosiderin 20x...
2,560 × 1,920;
3.27 MB



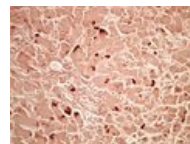
Hemosiderin 4x.jpg
2,560 × 1,920;
3.52 MB



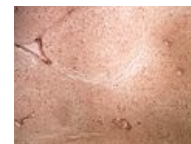
Hemosiderin lun...
2,560 × 1,920;
2.76 MB



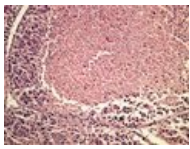
Hemosiderin lun...
2,560 × 1,920; 3.7
MB



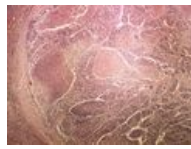
Hepatitis Orcein ...
2,560 × 1,920;
2.92 MB



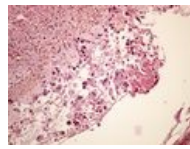
Hepatitis Orcein ...
2,560 × 1,920;
3.17 MB



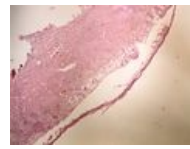
Hepatocellular ca...
2,560 × 1,920;
3.15 MB



Hepatocellular ca...
2,560 × 1,920;
3.86 MB



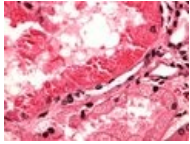
Herpes simplex h...
2,560 × 1,920;
2.83 MB



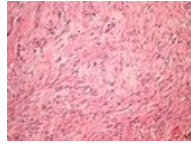
Herpes simplex h...
2,560 × 1,920;
2.85 MB



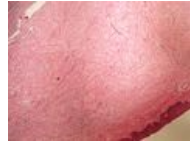
Hyaline droplet...
2,560 × 1,920;
3.44 MB



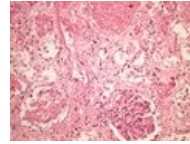
Hyaline droplet...
2,560 × 1,920;
2.54 MB



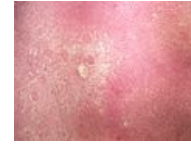Hypertrophic sca...
2,560 × 1,920;
3.28 MB



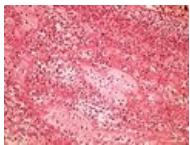
Hypertrophic sca...
2,560 × 1,920; 3.4
MB



Infarction of kidn...
2,560 × 1,920;
3.13 MB



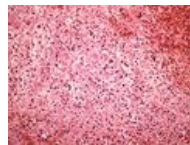
Infarction of kidn...
2,560 × 1,920;
3.37 MB



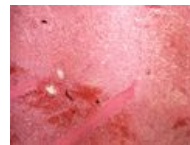Infarction of myo...
2,560 × 1,920;
3.32 MB



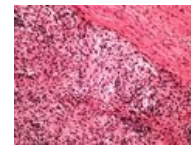
Infarction of myo...
2,560 × 1,920;
3.55 MB



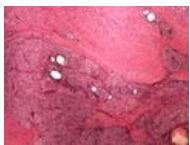Infarction of sple...
2,560 × 1,920;
3.37 MB



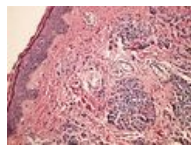
Infarction of sple...
2,560 × 1,920;
3.87 MB



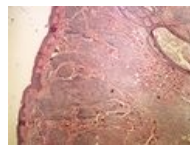
Inflammatory ps...
2,560 × 1,920;
2.97 MB



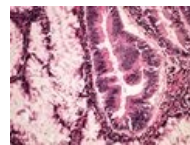
Inflammatory ps...
2,560 × 1,920;
3.42 MB



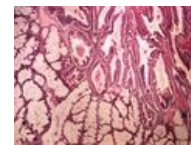
Intradermal mole...
2,560 × 1,920;
3.14 MB



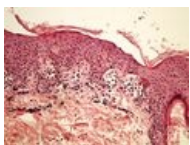
Intradermal mole...
2,560 × 1,920;
3.69 MB



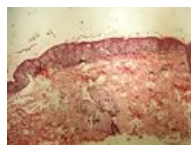Invasive cancer a...
2,560 × 1,920;
2.77 MB



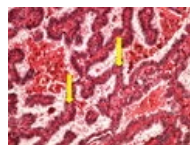
Invasive cancer a...
2,560 × 1,920;
3.35 MB



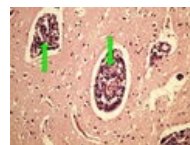
Junction mole jun...
2,560 × 1,920;
2.71 MB



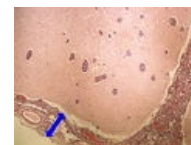
Junction mole jun...
2,560 × 1,920;
3.04 MB



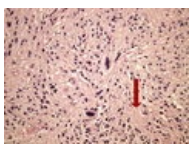
L 11-10 papillary ...
2,560 × 1,920;
3.79 MB



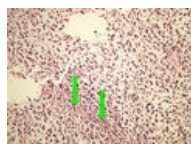
L 12-16 meninge...
2,560 × 1,920;
3.78 MB



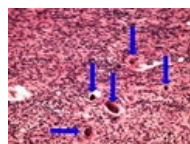
L 12-16 meninge...
2,560 × 1,920; 4
MB



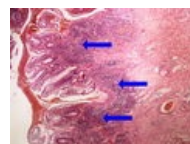
L 12-18 ependym...
2,560 × 1,920; 4
MB



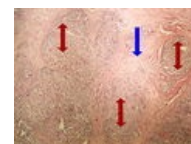
L 12-20 glioblast...
2,560 × 1,920;
5.05 MB



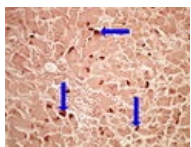
L 12-8 meningio...
2,560 × 1,920;
3.79 MB



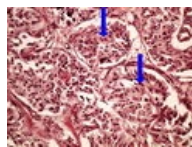
L 6-7 ulcerous co...
2,560 × 1,920; 4
MB



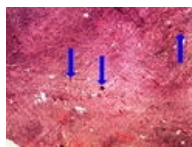
L 7-14 neuroend...
2,560 × 1,920; 4
MB



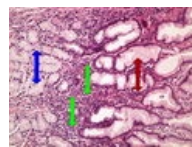
L 7-5 hepatitis Or...
2,560 × 1,920;
3.87 MB



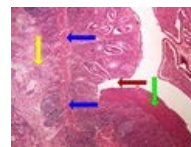
L11-4 pheochro...
2,560 × 1,920;
3.67 MB



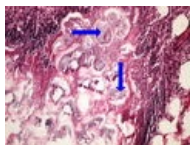
L12-8 meningiom...
2,560 × 1,920; 4
MB



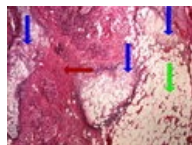
L5-7 chronic gast...
2,560 × 1,920;
3.77 MB



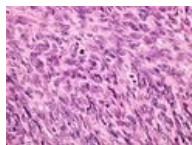
L6-6 Crohns dise...
2,560 × 1,920;
4.46 MB



L7-13 pancreatiti...
2,560 × 1,920;
3.62 MB



L7-13 pancreatiti...
2,560 × 1,920; 4
MB



Leiomyocellular s...
2,560 × 1,920;
3.19 MB



Leiomyocellular s...
2,560 × 1,920; 3.6
MB



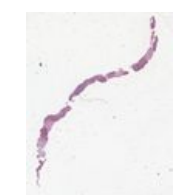Leiomyom 10 28...
1,440 × 1,418; 710
KB



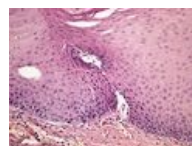
Leiomyosarkom ...
1,709 × 825; 139
KB



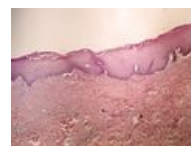Leiomyosarkom ...
1,769 × 793; 151
KB



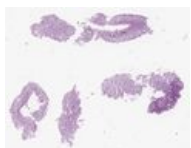
Leiomyosarkom ...
1,170 × 1,482; 218
KB



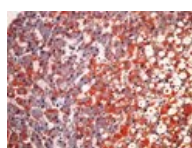
Leukoplakia 20x.j...
2,560 × 1,920;
2.75 MB



Leukoplakia 4x.jpg
2,560 × 1,920;
2.94 MB



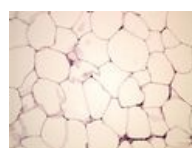LG tubulární ade...
747 × 599; 63 KB



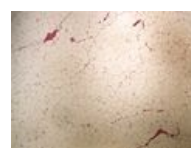Lipid staining (liv...
2,560 × 1,920;
2.97 MB



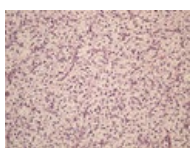
Lipid staining (liv...
2,560 × 1,920;
3.49 MB



Lipoma lipom 20...
2,560 × 1,920;
2.61 MB



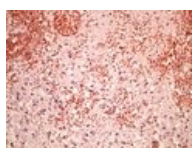
Lipoma lipom 4x...
2,560 × 1,920;
2.44 MB



Liposarcoma lipo...
2,560 × 1,920;
3.22 MB



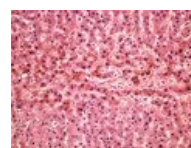
Liposarcoma lipo...
2,560 × 1,920;
3.65 MB



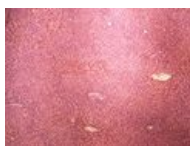Liquifactive necr...
2,560 × 1,920;
3.21 MB



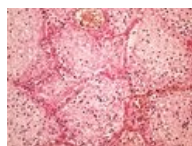
Liquifactive necr...
2,560 × 1,920;
3.72 MB



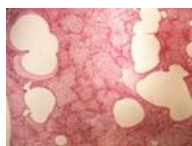
Liver atrophy hn...
2,560 × 1,920;
3.21 MB



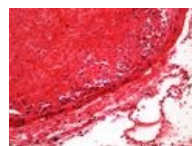
Liver atrophy hn...
2,560 × 1,920;
3.55 MB



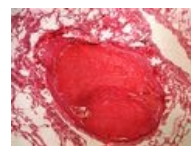
Lobar pneumonia...
2,560 × 1,920;
3.34 MB



Lobar pneumonia...
2,560 × 1,920;
3.24 MB



Lung thrombotic e...
2,560 × 1,920;
2.23 MB



Lung thrombotic e...
2,560 × 1,920; 3
MB