


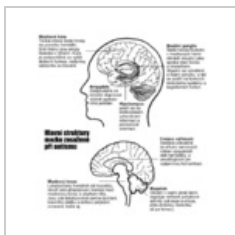
Kategorie:Neurologická schémata

Media in category "Neurologická schémata"

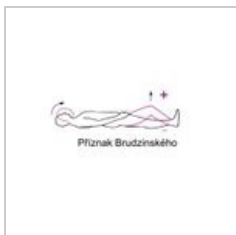
The following 35 files are in this category, out of 35 total.



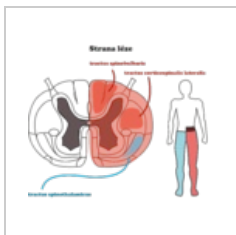
Akutni neurologic...
543 × 887; 145 KB



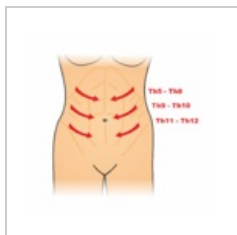
Autismbrain cs.png
500 × 540; 171 KB



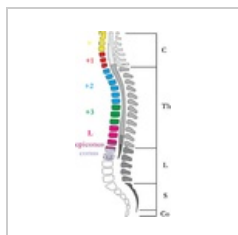Brudzinského pří...
314 × 178; 9 KB



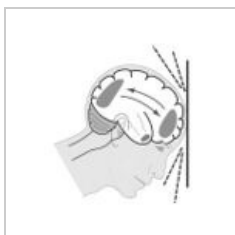Bs syndrom.png
3,657 × 3,079; 808 KB



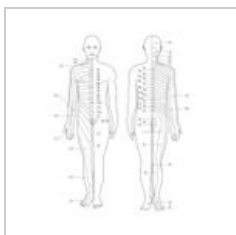
Břišní reflexy.png
2,350 × 2,311; 319 KB



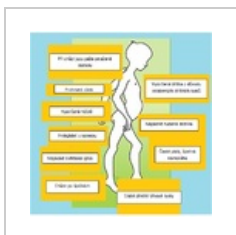Chipault.png
600 × 1,166; 205 KB



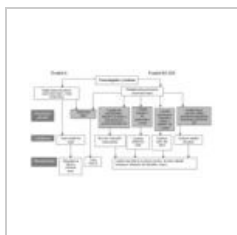
DAP.jpg
250 × 258; 43 KB



Dermatomy.jpg
420 × 520; 78 KB



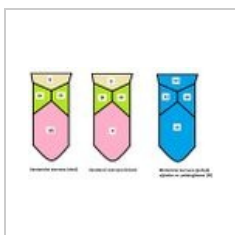
Duschenn.png
467 × 476; 117 KB



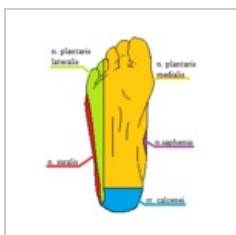
Frankel lokalizac...
793 × 462; 111 KB



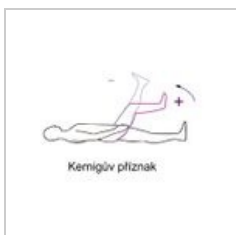Herniace disku.jpg
300 × 514; 59 KB




Inervace jazyka.J...
491 × 298; 30 KB



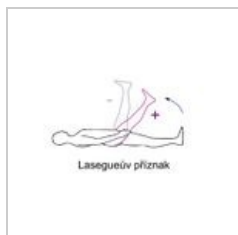
Inervace planty.p...
205 × 246; 6 KB



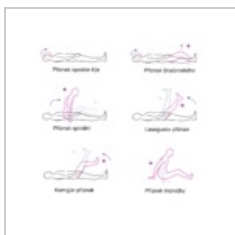
Kernigův příznak...
271 × 229; 9 KB



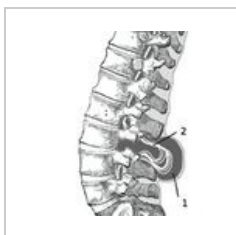Labutí šíje.png
1,030 × 616; 362 KB



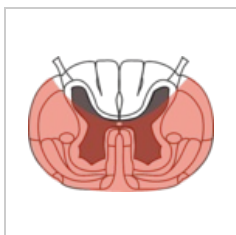
Lasegue.jpg
294 × 196; 9 KB



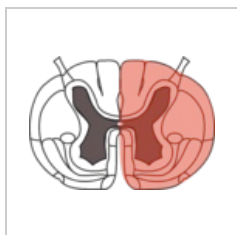
Meningeální jevy...
1,826 × 1,789; 310 KB



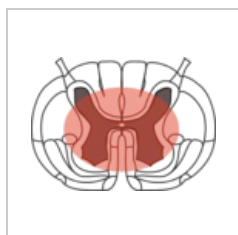
Meningomyelocel...
300 × 335; 22 KB



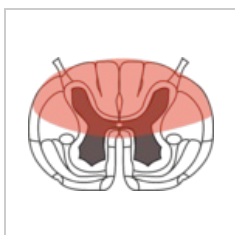
Mícha anterior sy...
1,815 × 1,332; 361 KB



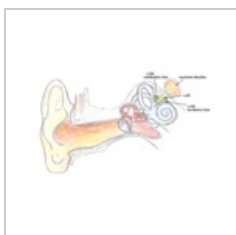
Mícha bs sy.png
1,815 × 1,312; 341 KB



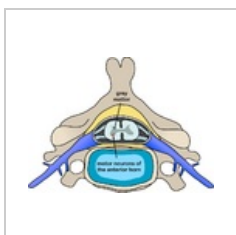
Mícha central sy...
1,815 × 1,312; 323 KB



Mícha posterior s...
1,815 × 1,312; 334 KB




Neurinom akusti...
605 × 388; 205 KB



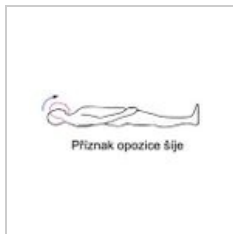Polio spinal diagr...
800 × 588; 197 KB



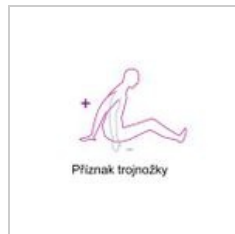
Postih centrální.p...
480 × 640; 78 KB



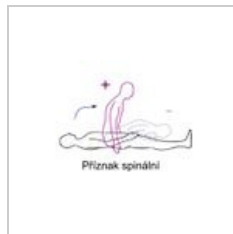
Postih periferní.png
480 × 640; 53 KB



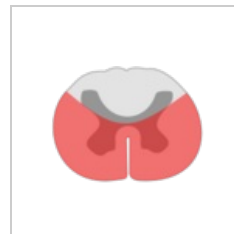
Příznak opozice š...
255 × 160; 8 KB



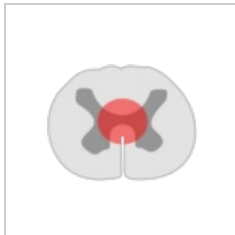
Příznak trojnožky...
255 × 240; 8 KB



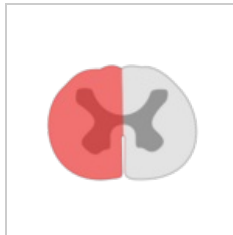
Spine sign.jpg
294 x 196; 9 KB



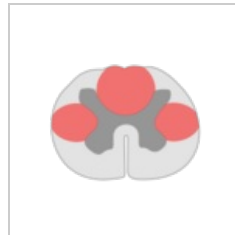Syndrom anterol...



Syndrom centro...
240 × 200; 4 KB



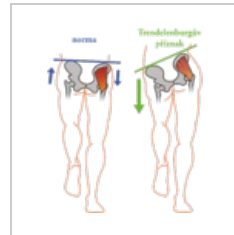
Syndrom unilater...
240 × 200; 4 KB



Syndrom zadních...
240 × 200; 5 KB

[illegible]

Tabulka otázka 2...
844 × 540; 104 KB



Trendelenburg-př...
2,659 × 3,070; 541
KB