

Kategorie:Skiagramy

Subcategories

This category has the following 2 subcategories, out of 2 total.

M

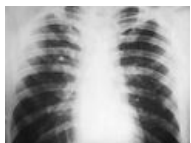- Mamogramy (8 F)

T

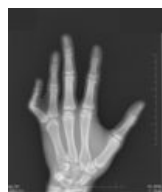- TIPS (6 F)

Media in category "Skiagramy"

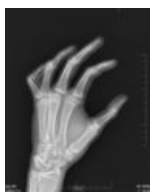The following 76 files are in this category, out of 76 total.



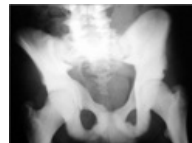
10187 lores.jpg
700 × 520; 29 KB



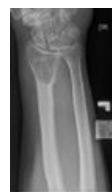4metakarpy A.jpg
1,400 × 1,672; 989 KB



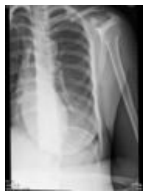4metakarpy B.jpg
1,320 × 1,664; 836 KB



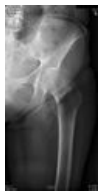790px-Osteopetr...
790 × 599; 214 KB



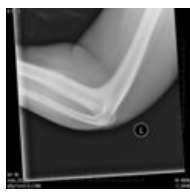832c03aebd2a2e...
357 × 630; 18 KB



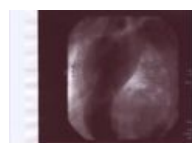
Abrupce proc. co...
2,126 × 2,852; 2 MB



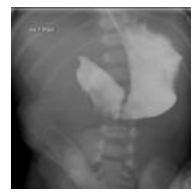Abrupce velkeho ...
1,256 × 2,488; 1.25 MB



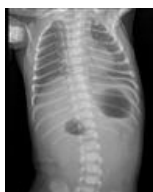
Ankyloza lokte.jpg
1,756 × 1,709; 646 KB



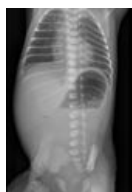Aortografie disek...
700 × 522; 56 KB



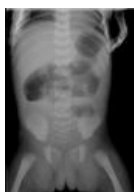Atrezie duodena ...
372 × 367; 31 KB



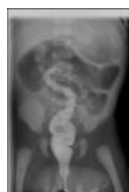Atrezie duodena ...
360 × 455; 18 KB



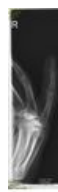Atrezie duodena ...
482 × 706; 36 KB



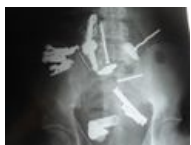Atrezie jejuna IV...
361 × 516; 16 KB



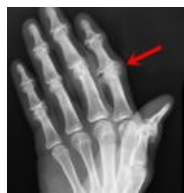Atrezie jejuna IV...
338 × 491; 15 KB



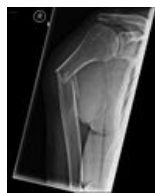Avulze baze stre...
376 × 1,260; 122 KB



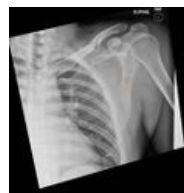Bodné rány RTG.j...
640 × 477; 32 KB



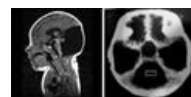
Bouchard-nodes.j...
982 × 1,024; 208 KB



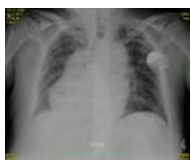Breast met, blast...
516 × 630; 27 KB



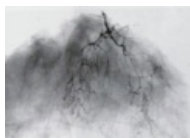Clavicla-fracture...
991 × 1,024; 149 KB



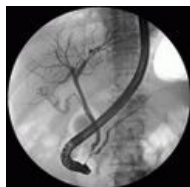Dandy-Walker m...
624 × 308; 37 KB



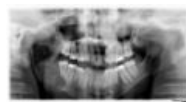Dextrokardie.jpg
2,688 × 2,208;
1.74 MB



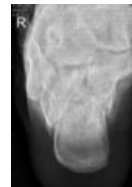Duktografie.png
536 × 382; 500 KB



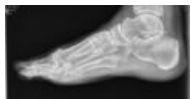ERCP.jpg
519 × 515; 80 KB



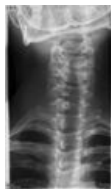Folikulární cysta ...
2,815 × 1,540; 151
KB



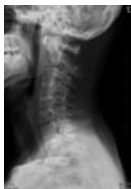Fr.calcanea.axial....
584 × 845; 291 KB



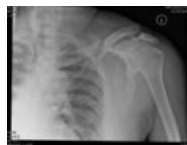Fr.calcanea.bocn...
2,024 × 1,065; 944
KB



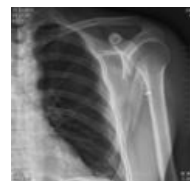Fr.dentu ap.jpg
800 × 1,384; 595
KB



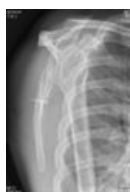Fr.dentu bocna.jpg
1,112 × 1,600; 811
KB



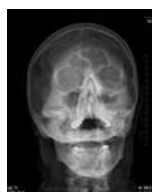Fr.lopatky.jpg
2,465 × 1,870;
1.58 MB



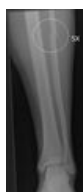Fr.lopatky2AP.jpg
1,768 × 1,659;
1.34 MB



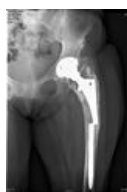Fr.lopatky2TT.jpg
1,104 × 1,651; 920
KB



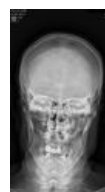Fr.orbit.jpg
1,432 × 1,824; 650
KB



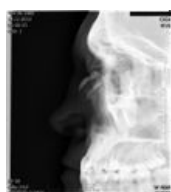Fracturafibulae.JPG
304 × 712; 12 KB



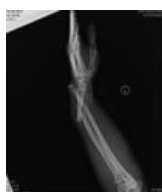Fraktura femorál...
1,824 × 2,688;
1.91 MB



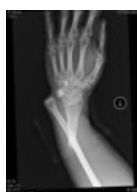Fraktura mandib...
1,192 × 2,160;
1.05 MB



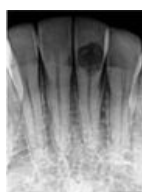
Fraktura nosnich ...
944 × 1,056; 426
KB



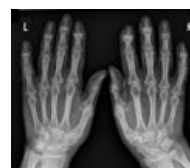Galeazziho zlome...
2,514 × 2,955;
1.35 MB



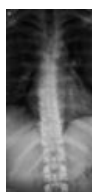Galeazziho zlome...
1,468 × 2,032; 863
KB



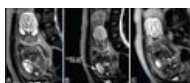
Granuloma inter...
300 × 398; 35 KB



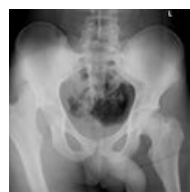Heberden-nodes...
1,024 × 885; 81
KB



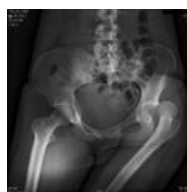Hemivertebra.jpg
1,136 × 2,418;
1.46 MB



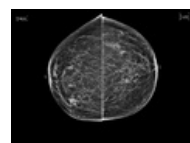
IJRI-26-52-g013.jpg
539 × 218; 35 KB



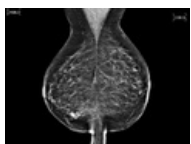
Luxace pravé kyč...
836 × 861; 309 KB



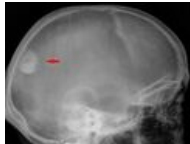
Luxace v kyčelni...
2,688 × 2,688;
2.73 MB



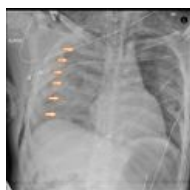Mamo-kraniokau...
1,580 × 1,165; 907
KB



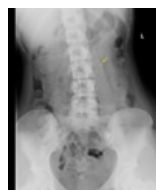Mamo-mediolate...
1,515 × 1,130;
1.01 MB



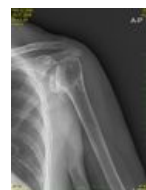Meningeom im R...
1,084 × 895; 214
KB



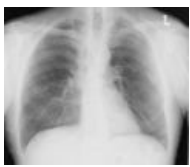Multiple-rib-fract...
1,024 × 1,024; 210
KB



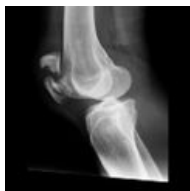Nefrolithiaza.png
815 × 991; 1,010
KB



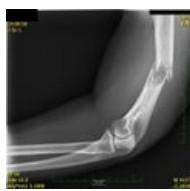Nekrosa hlavice ...
1,296 × 1,680; 479
KB



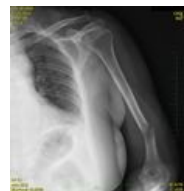Neurofibromatóz...
1,139 × 965; 507
KB



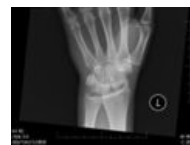Patella-fracture-9...
1,024 × 1,024; 349
KB



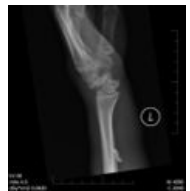Patologicka zlom...
1,448 × 1,400; 623
KB



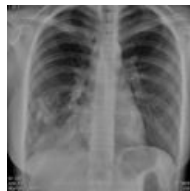Patologicka zlom...
2,104 × 2,248;
1.11 MB



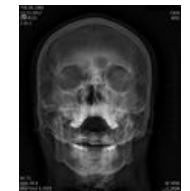Perilunate AP.jpg
1,496 × 1,110; 478
KB



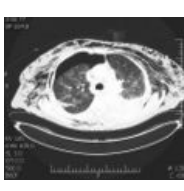
Perilunate bocna...
1,250 × 1,304; 249
KB



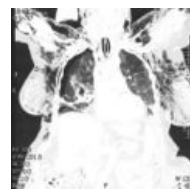
Pneumonie.jpg
2,048 × 2,063;
2.42 MB



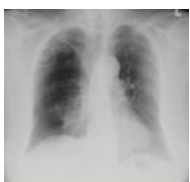Pneumoorbita.jpg
1,480 × 1,696; 972
KB



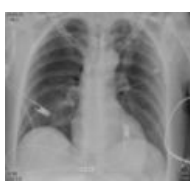
PNO axial.jpg
512 × 446; 174 KB



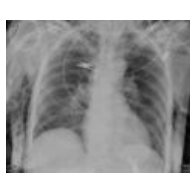PNO cor.jpg
512 × 500; 154 KB



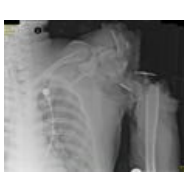PNO vpravo.jpg
1,047 × 983; 413
KB



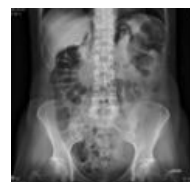PNO.jpg
2,176 × 1,981;
1.96 MB



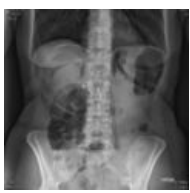Podkozni emfyze...
2,408 × 1,984;
1.57 MB



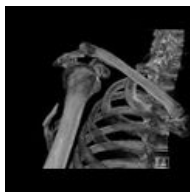Polytrauma rame...
4,400 × 3,610; 4
MB



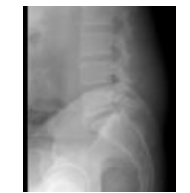Retropneumoperi...
2,666 × 2,545;
3.65 MB



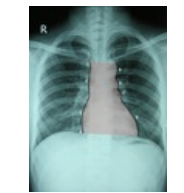Retropneumoperi...
2,400 × 2,346;
2.87 MB



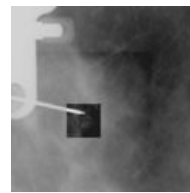
Scapular-fracture...
1,024 × 1,024; 68
KB



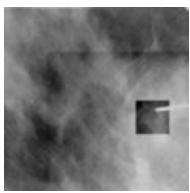
Spondylolýza L5.j...
1,760 × 2,140; 287
KB



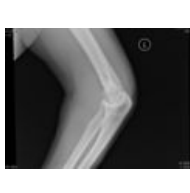Srdecni stin.png
2,026 × 2,743;
5.25 MB



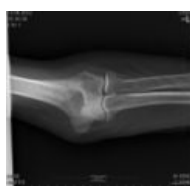Stereotaktická bi...
459 × 459; 18 KB



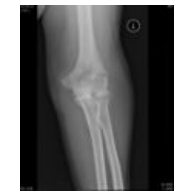Stereotaktická bi...
452 × 449; 23 KB



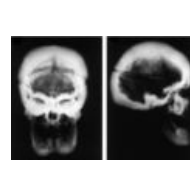
Transepikondylic...
3,014 × 2,295;
1.67 MB



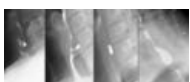Transepikondylic...
1,357 × 1,274; 677
KB



Transepikondylic...
2,394 × 2,882;
1.58 MB



Vam buchtem cal...
333 × 222; 22 KB



Zenker Divertikel...
1,428 × 580; 106
KB