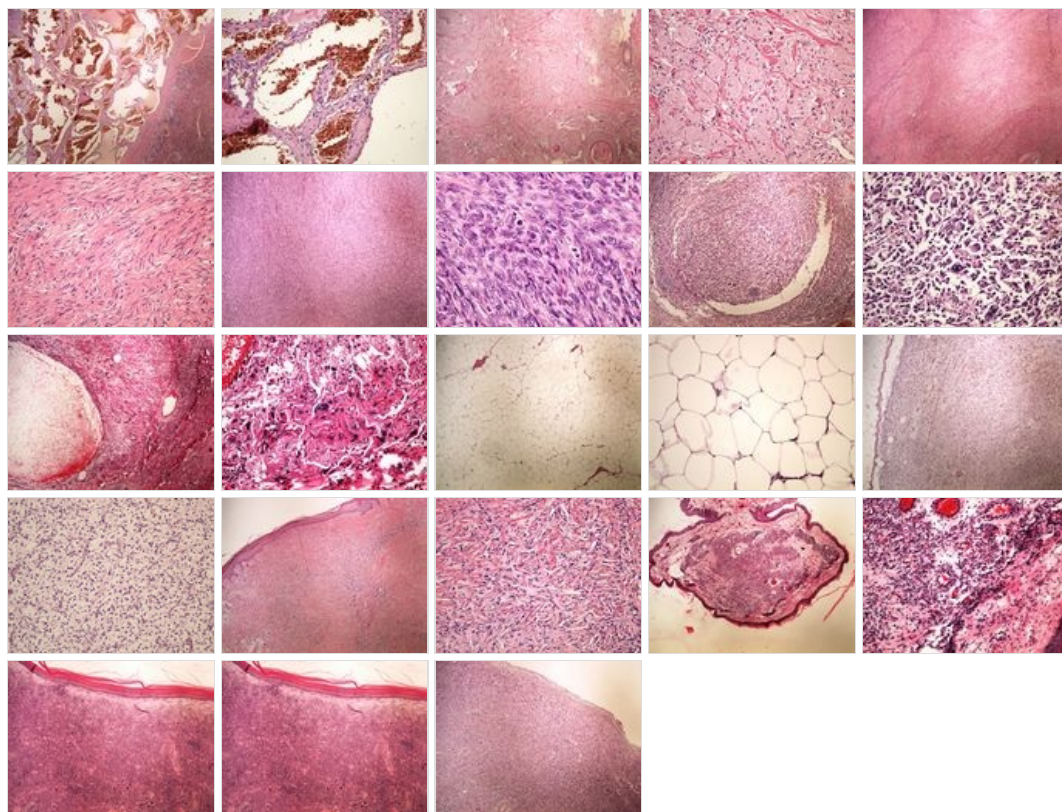
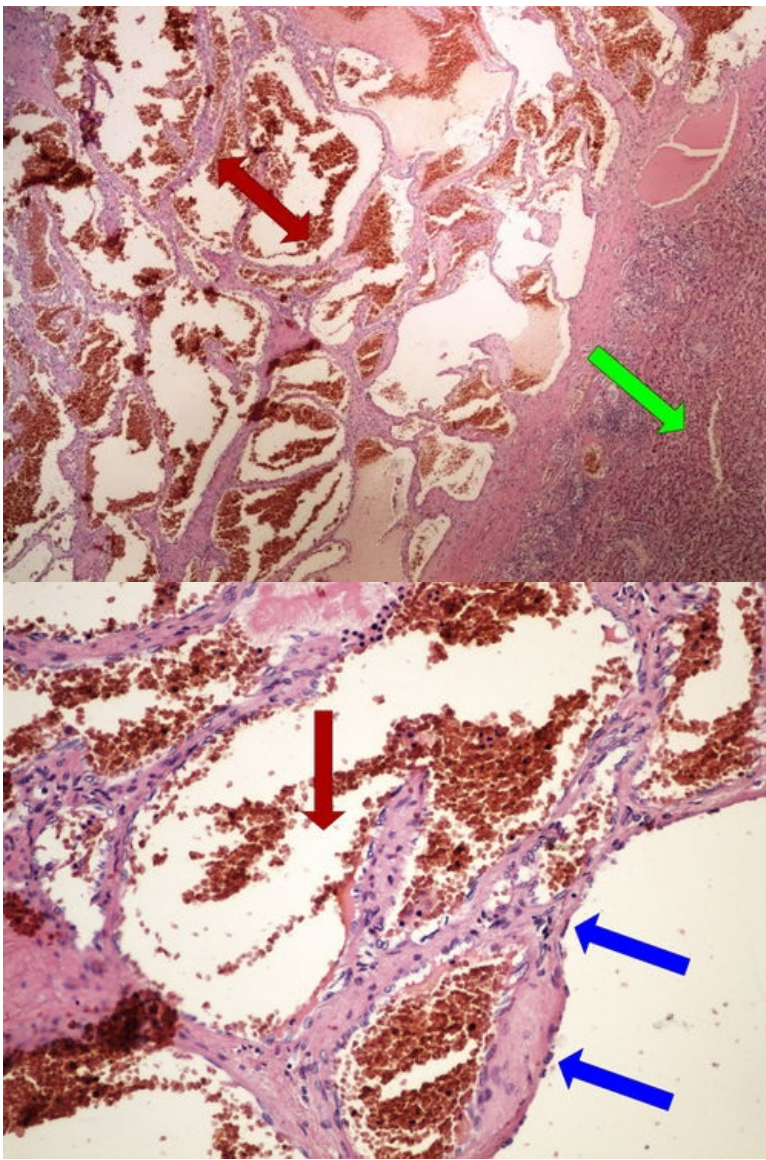


Modul OZPP - Praktikum č. 10 (zoom)

Přehled



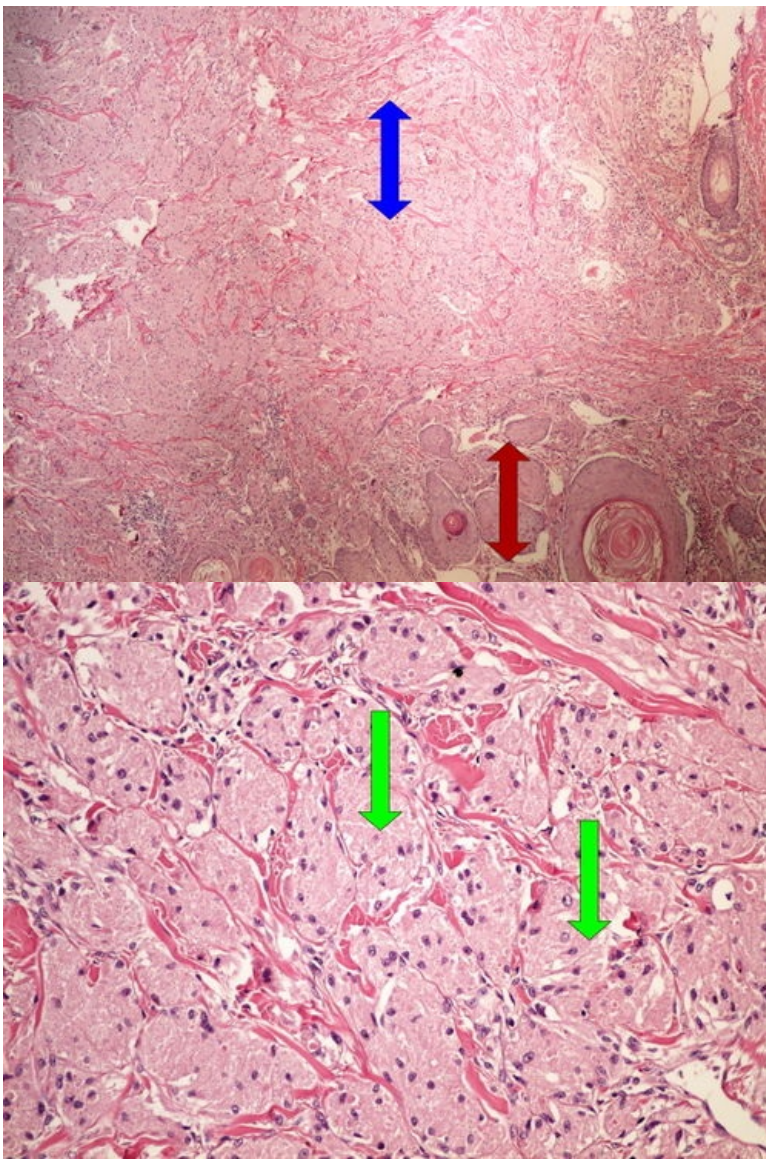
Preparát č.1 a č.2 - kavernózní hemangiom jater



Struktury

[Expand]

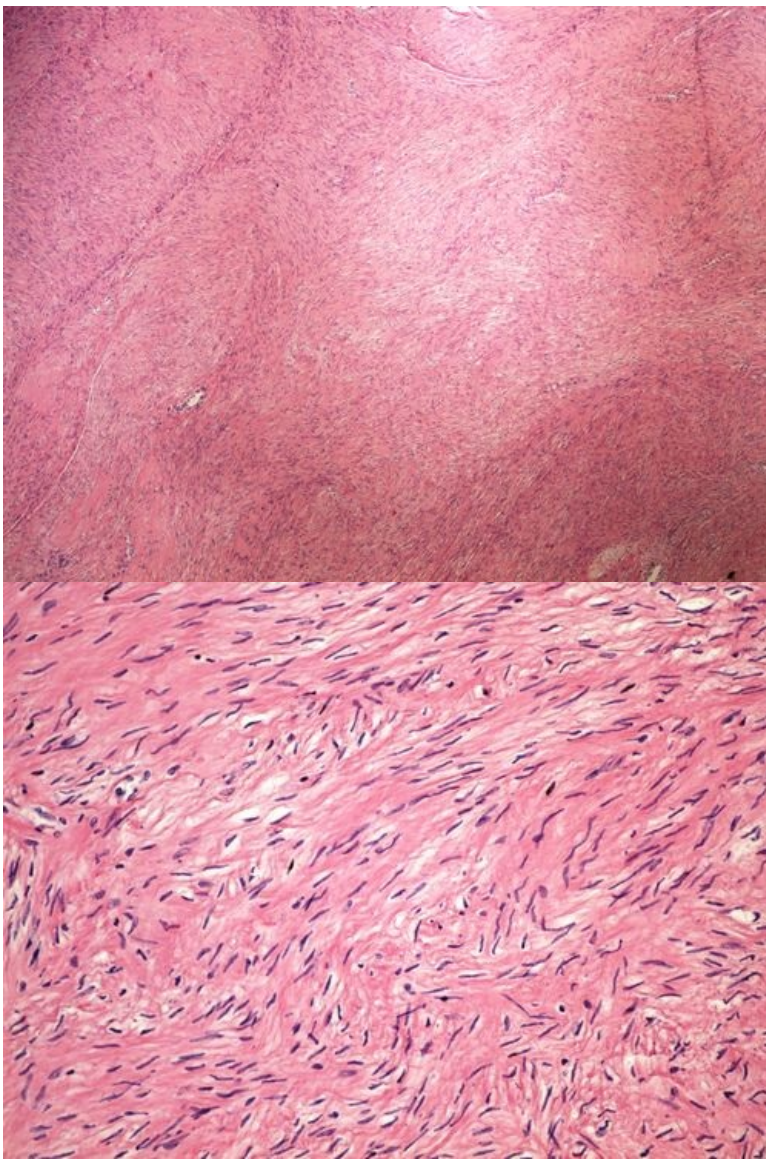
Preparát č.3 a č.4 - nádor z granulárních buněk



Struktury

[Expand]

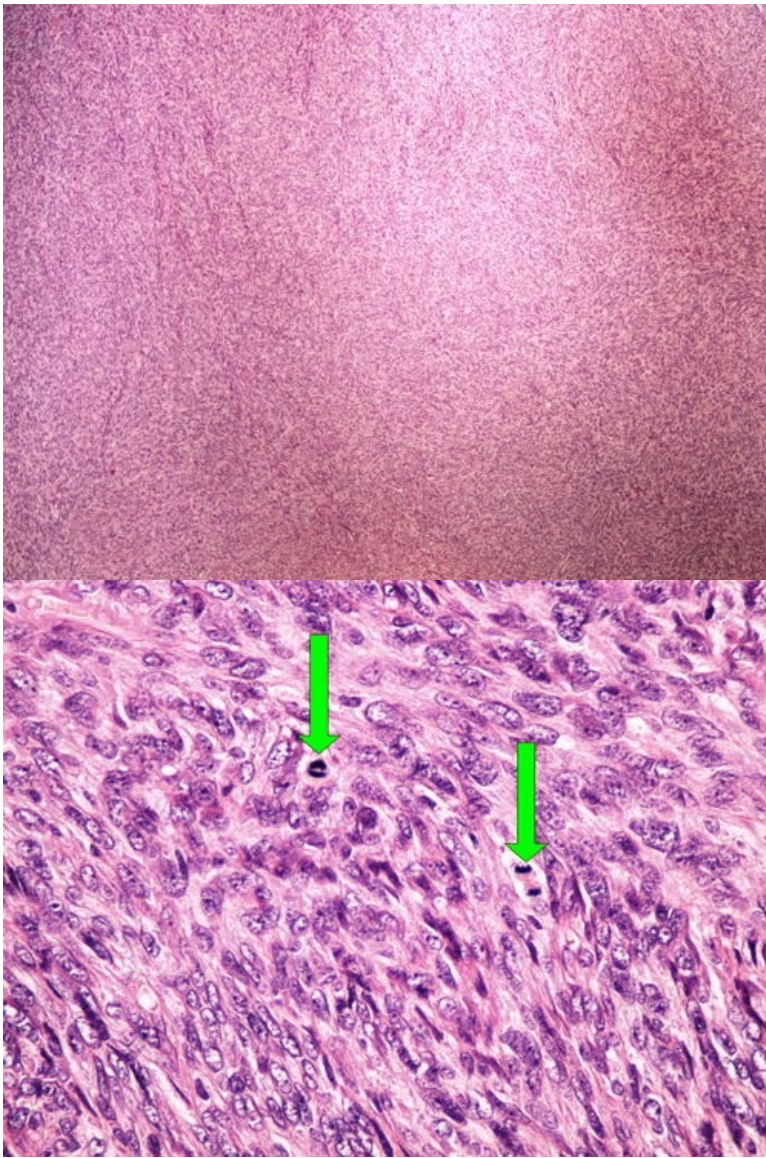
Preparát č.5 a č.6 - leiomyom dělohy



Struktury

[\[Expand\]](#)

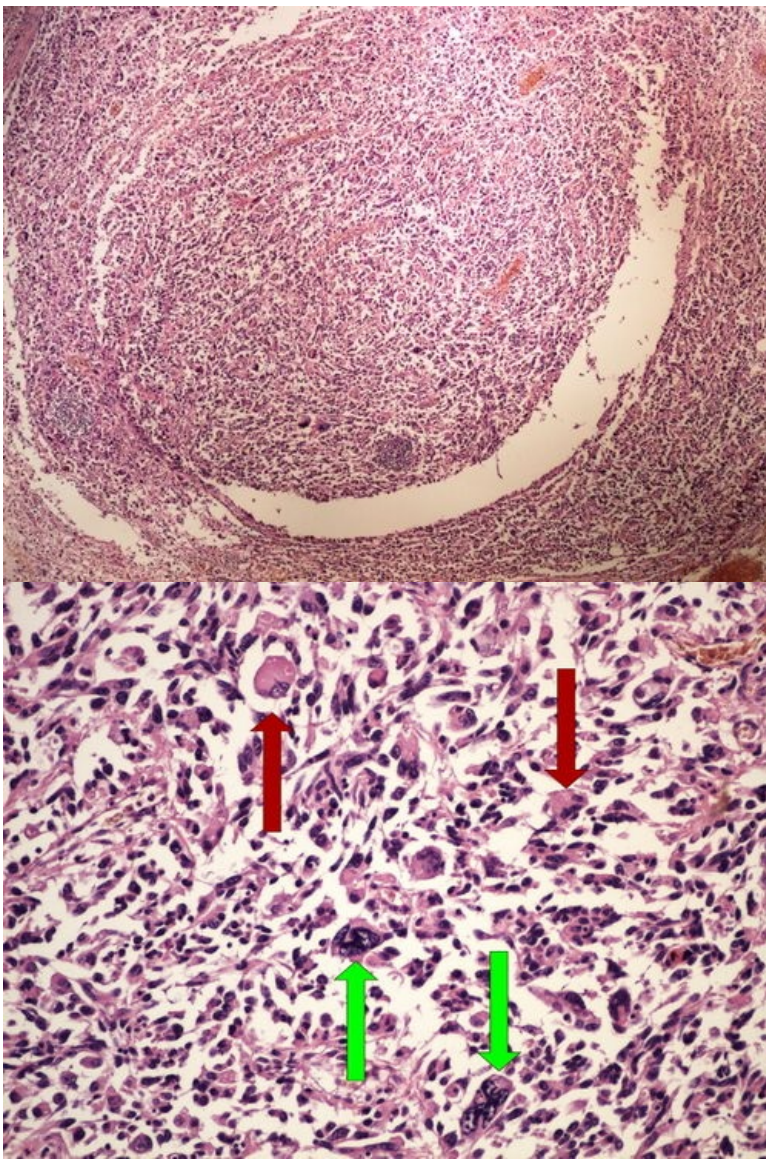
Preparát č.7 a č.8 - leiomyocelulární sarkom



Struktury

[Expand]

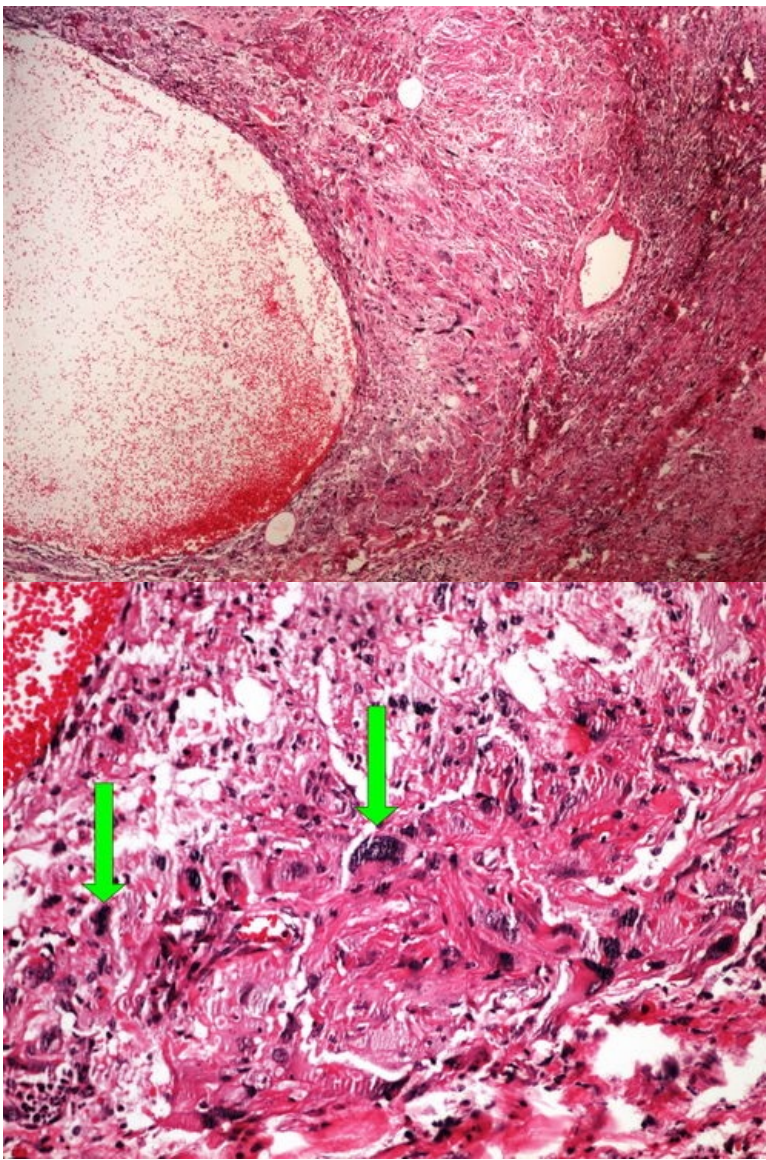
Preparát č.9 a č.10 - polymorfofelulární sarkom



Struktury

[Expand]

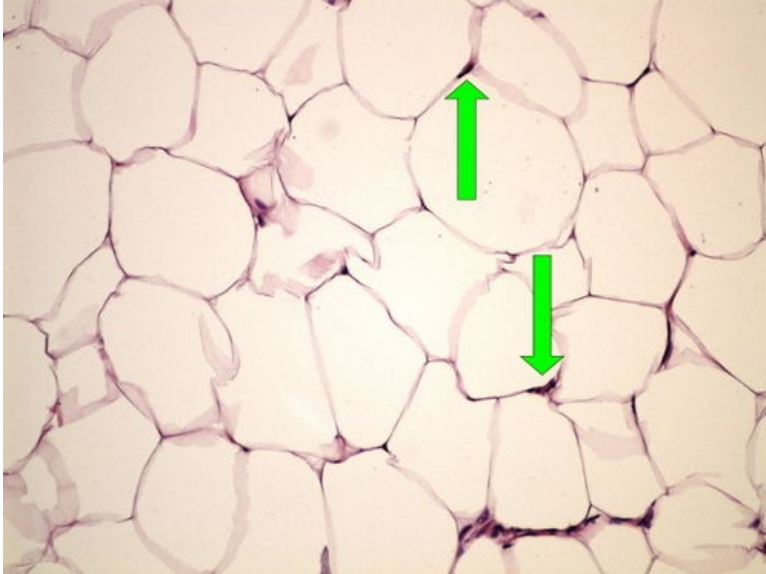
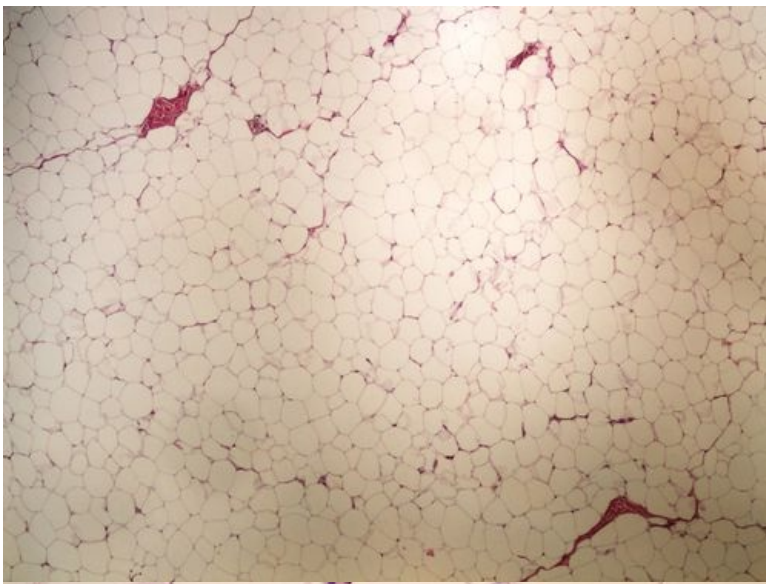
Preparát č.11 a č.12 - rhabdomyosarkom



Struktury

[Expand]

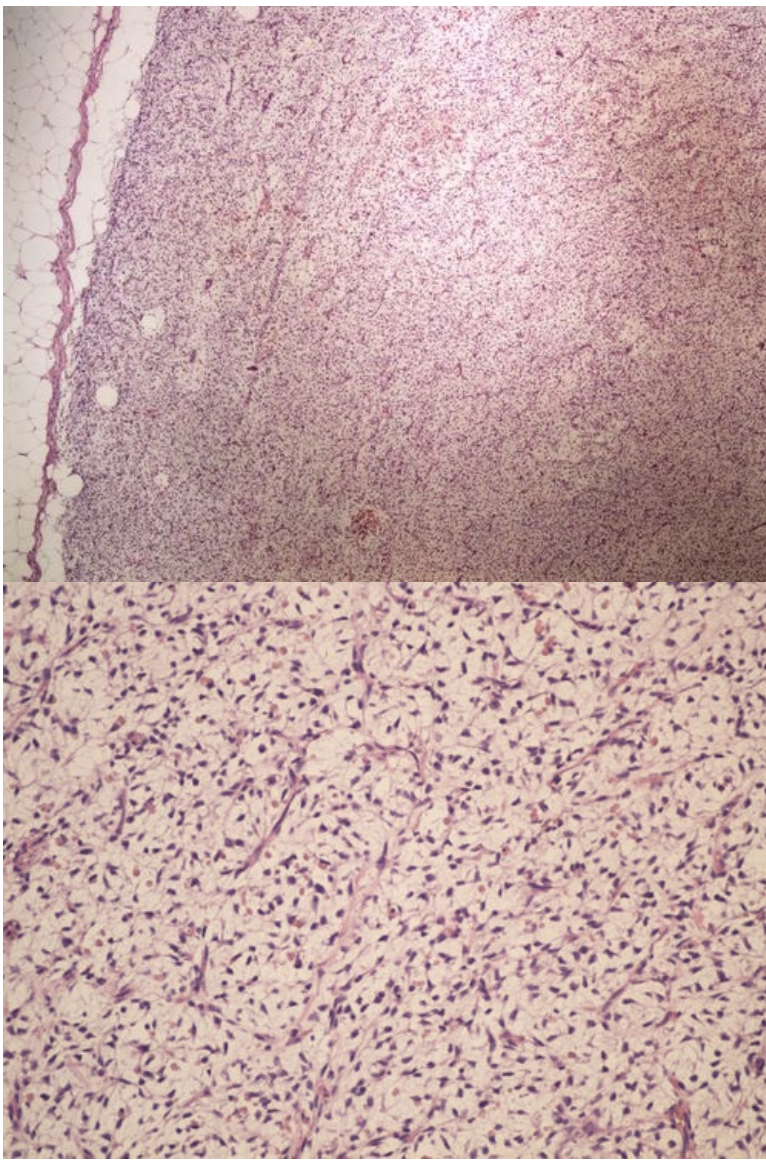
Preparát č.13 a č.14 - lipom



Struktury

[Expand]

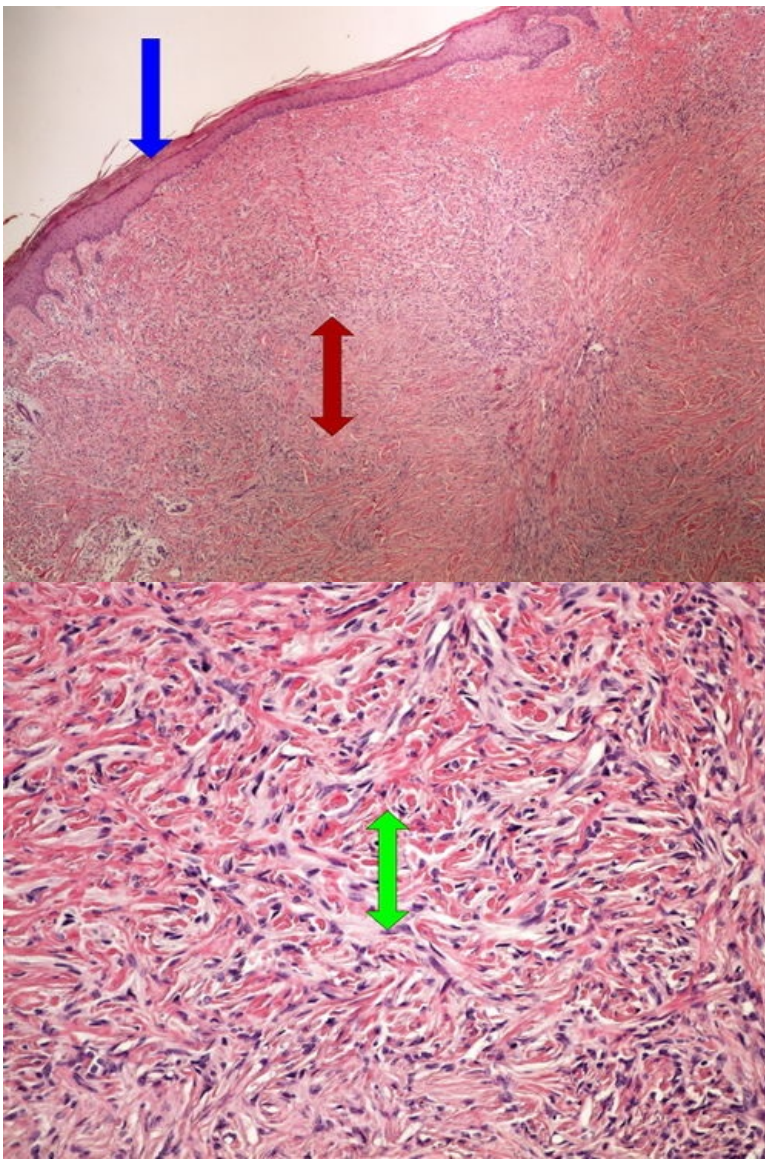
Preparát č.15 a č.16 - liposarkom



Struktury

[\[Expand\]](#)

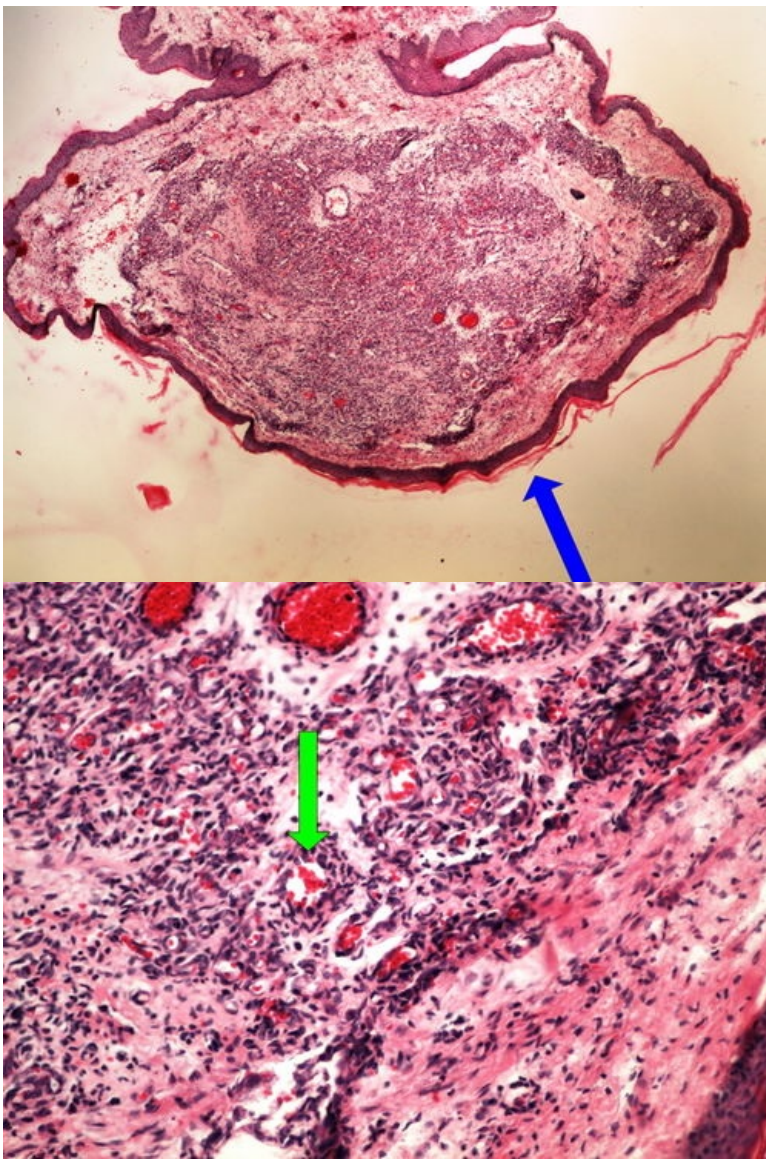
Preparát č.17 a č.18 - dermatofibrom



Struktury

[Expand]

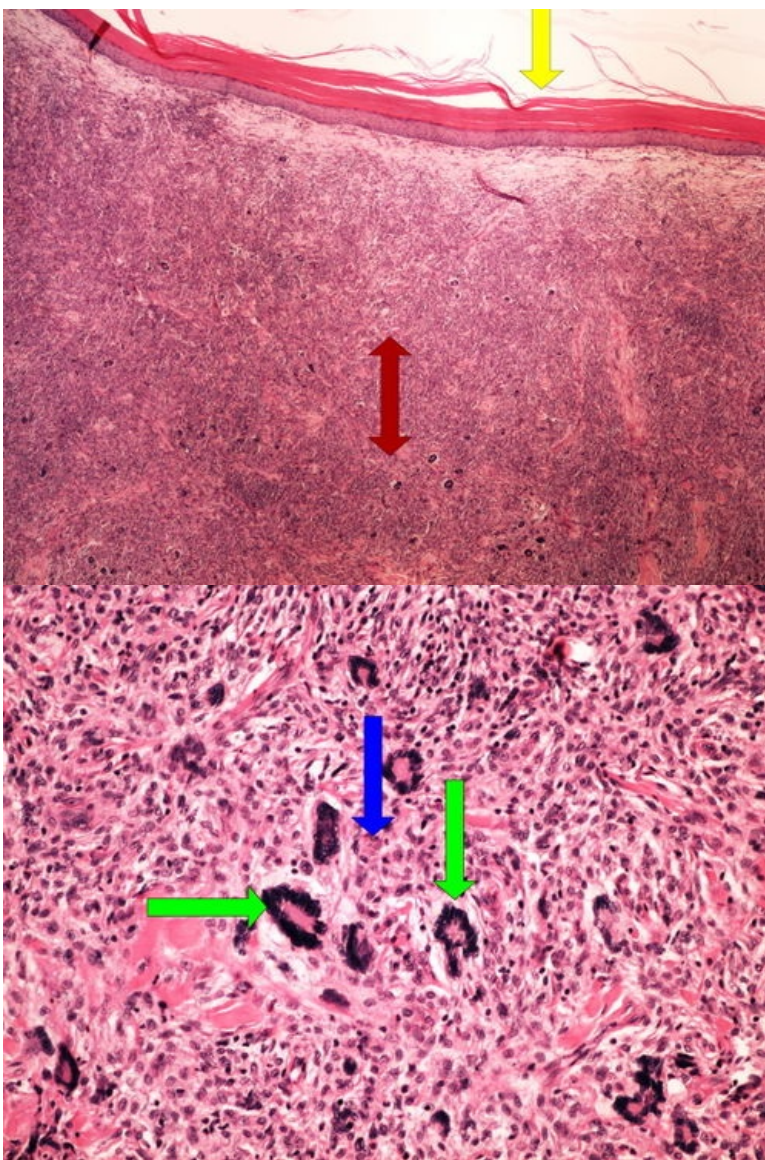
Preparát č.19 a č.20 - kapilární hemangiom kůže



Struktury

[Expand]

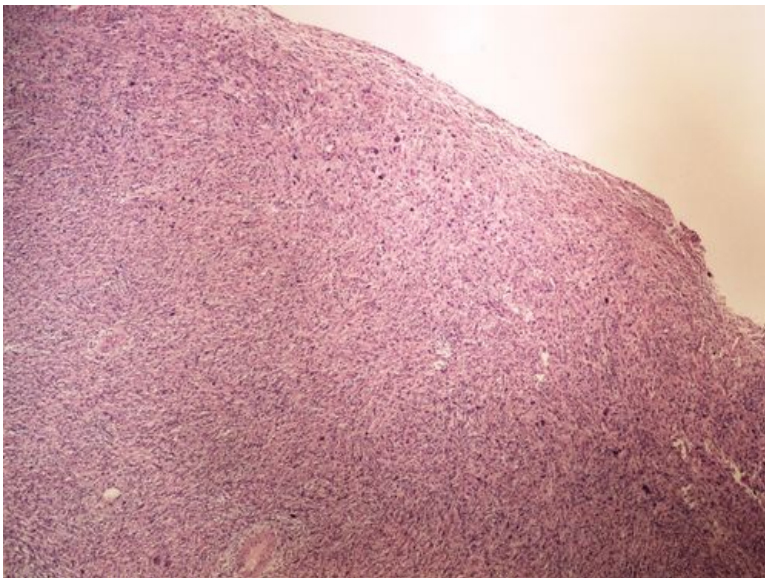
Preparát č.21 a č.22 - fibroxanthom



Struktury

[Expand]

Preparát č.23 - maligní fibrozní histiocytem



Odkazy

Navigace

← Praktikum č. 9

