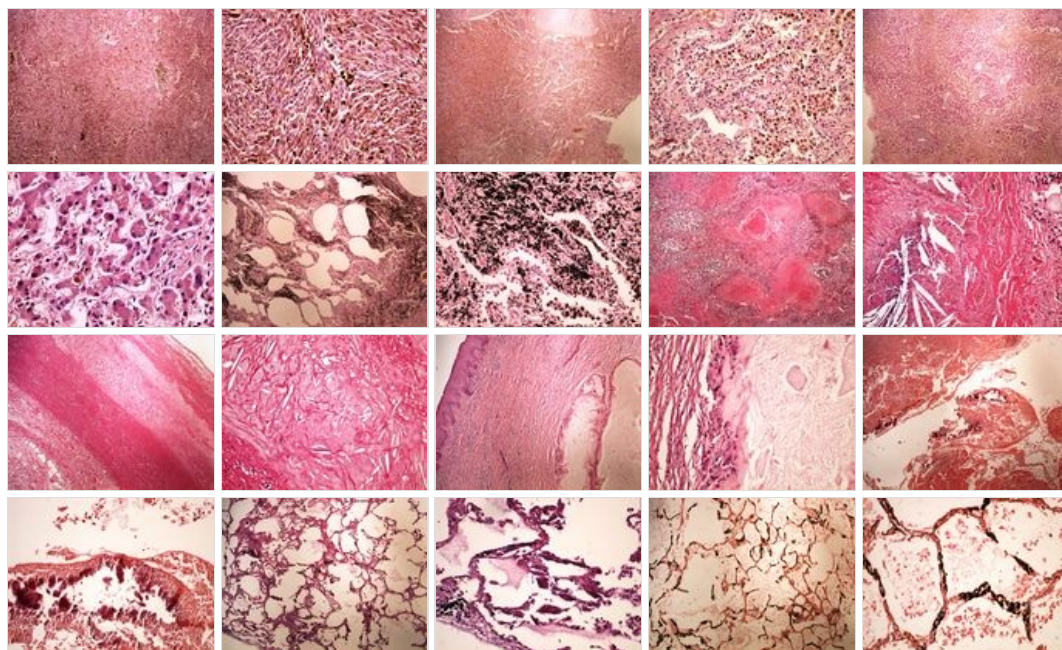
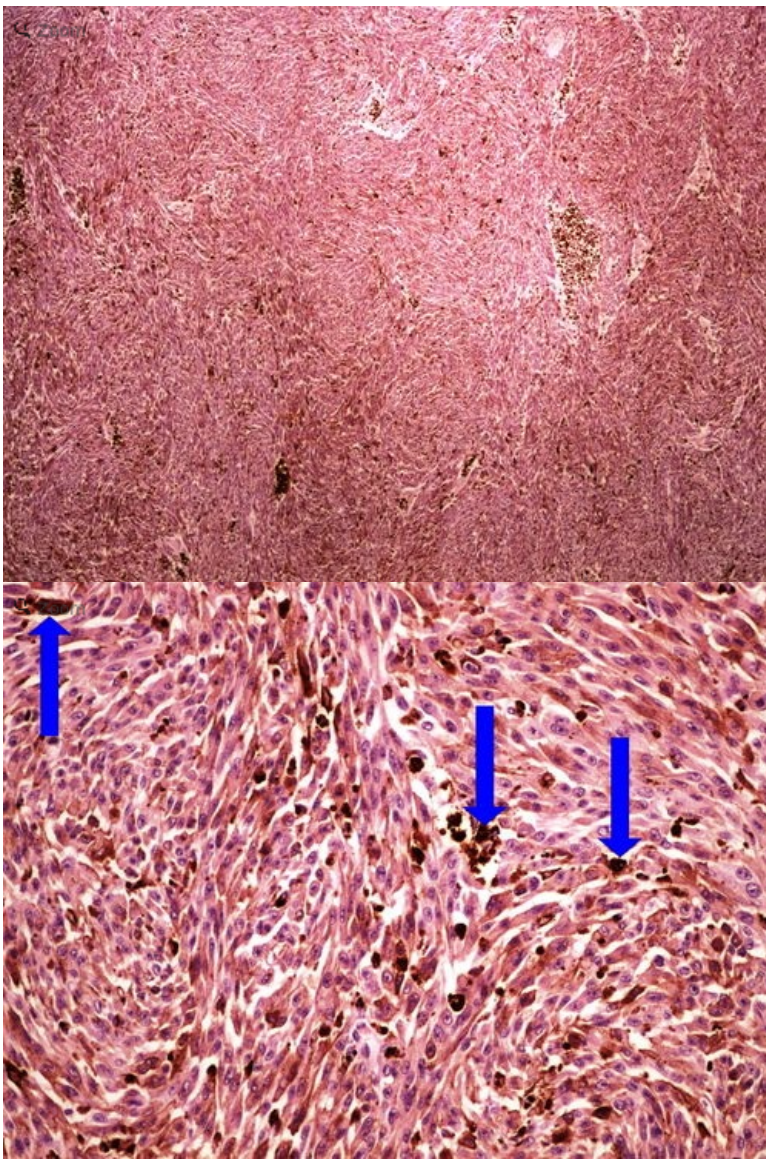


Modul OZPP - Praktikum č. 4 (zoom)

Přehled



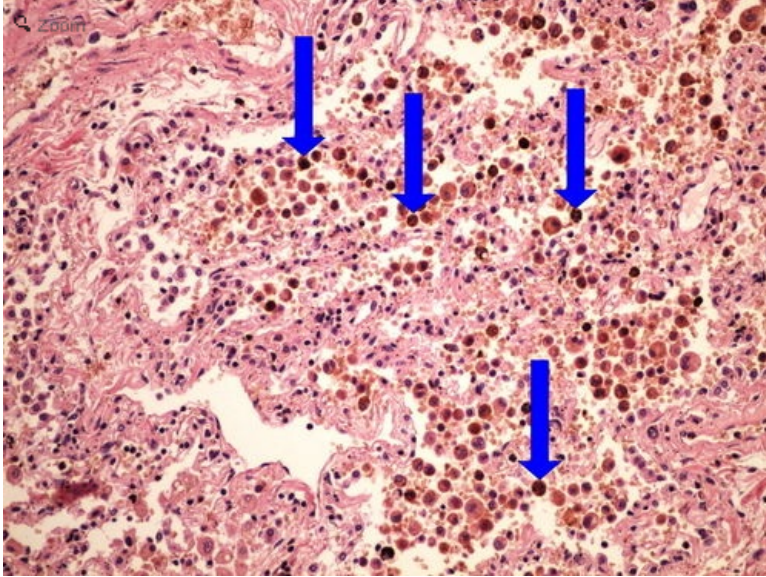
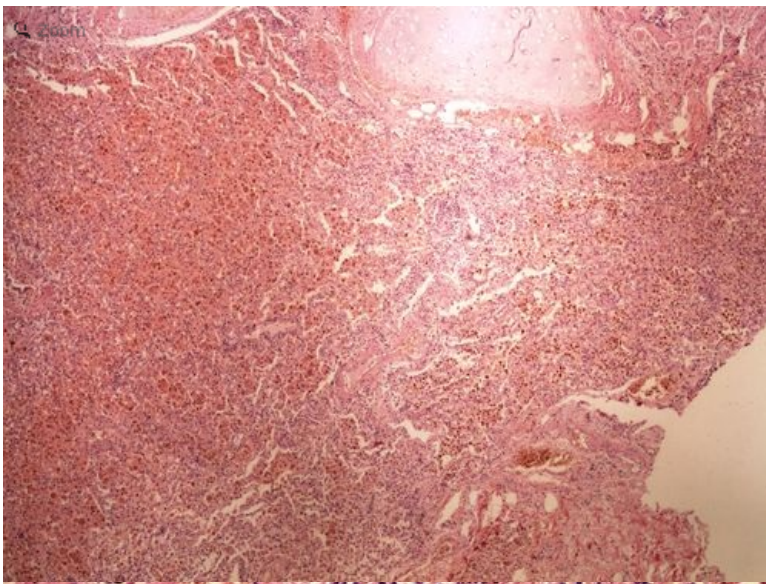
Preparát č.1 a č.2 - melanin



Struktury

[\[Expand\]](#)

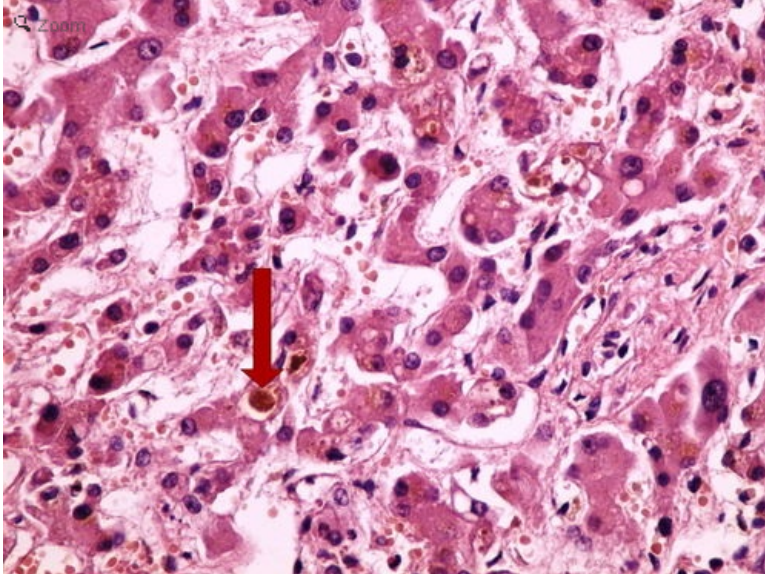
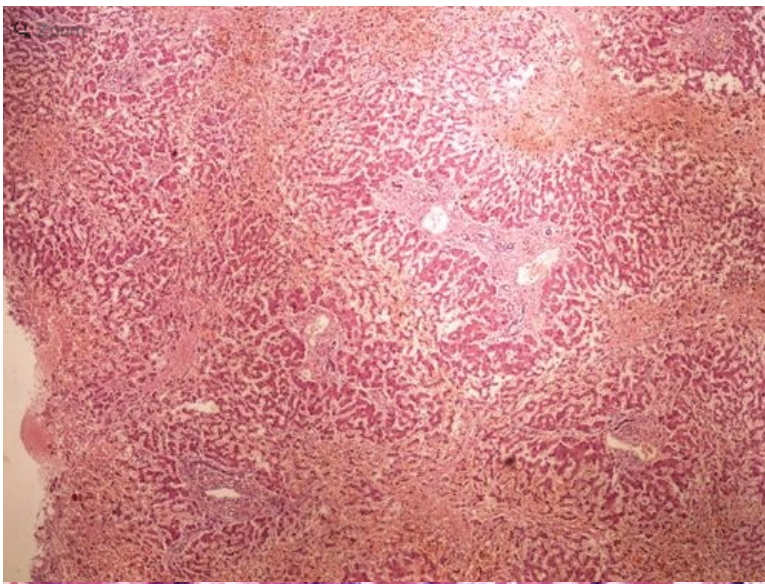
Preparát č.3 a č.4 - hemosiderin



Struktury

[Expand]

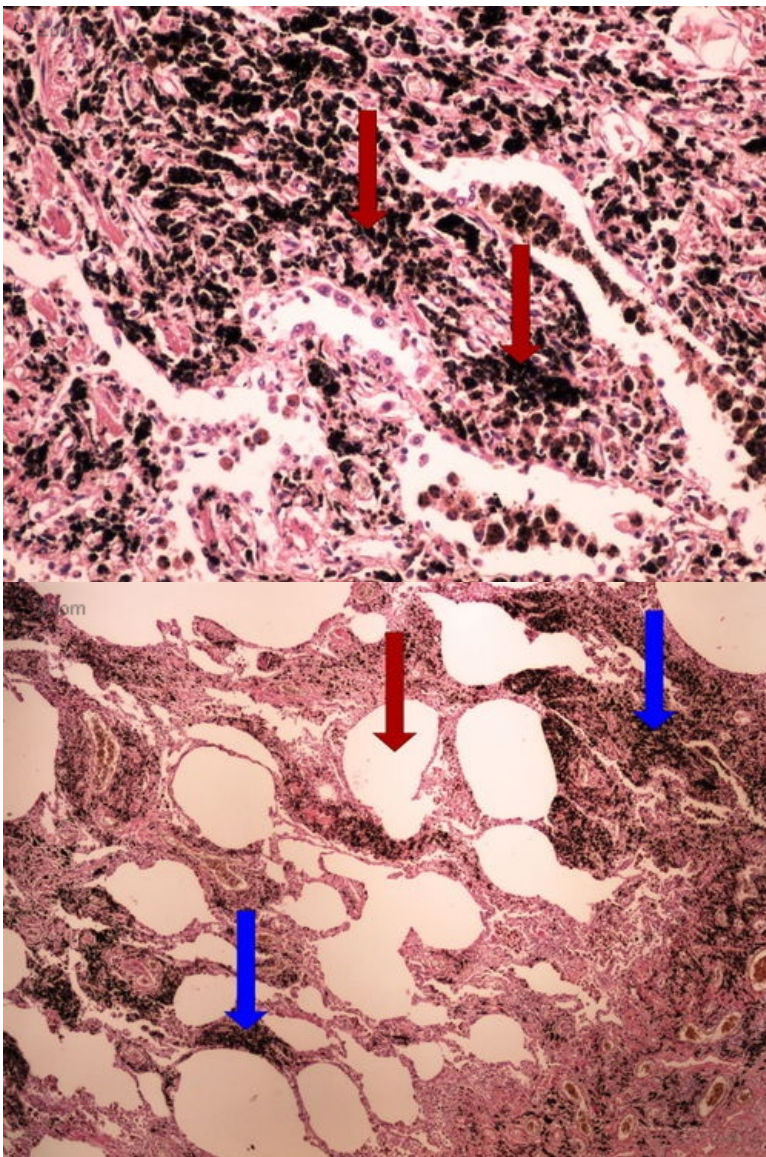
Preparát č.5 a č.6 - bilirubin



Struktury

[\[Expand\]](#)

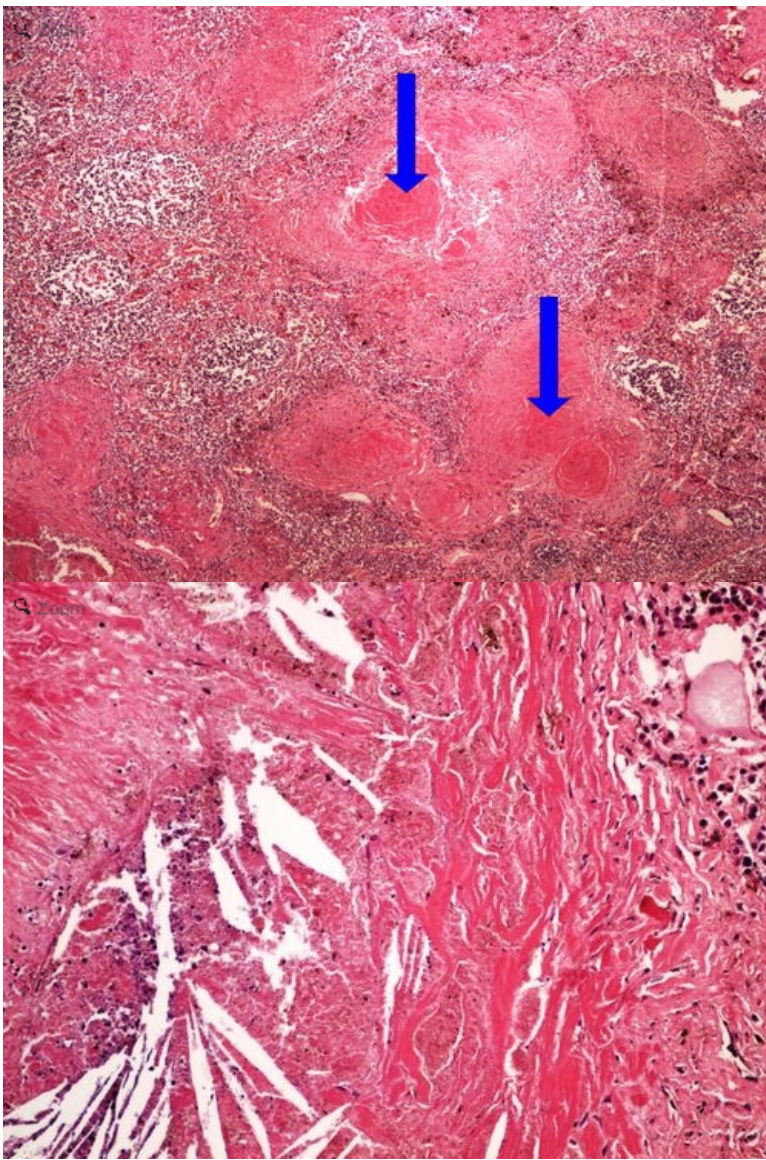
Preparát č.7 a č.8 - antrakóza



Struktury

[\[Expand\]](#)

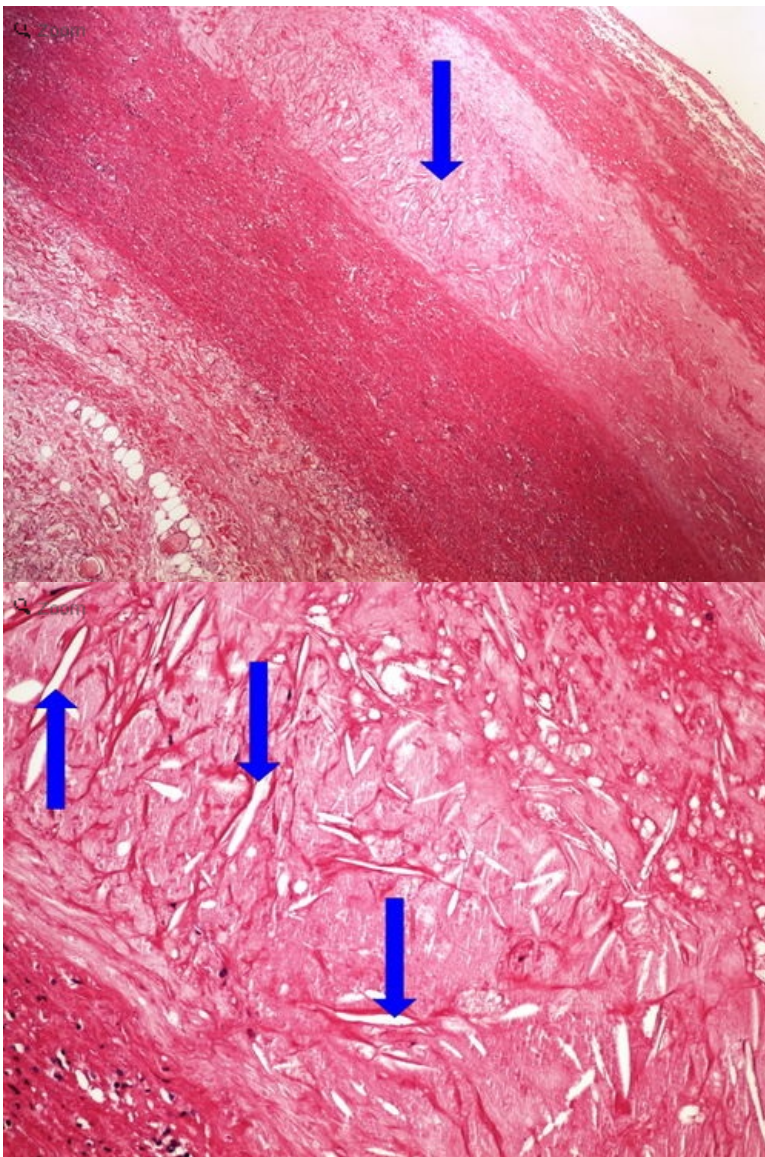
Preparát č.9 č.10 - silikóza



Struktury

[Expand]

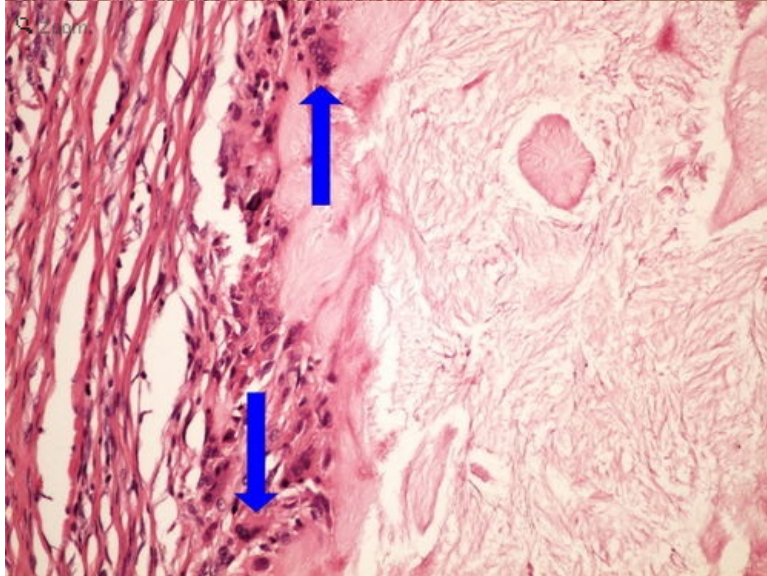
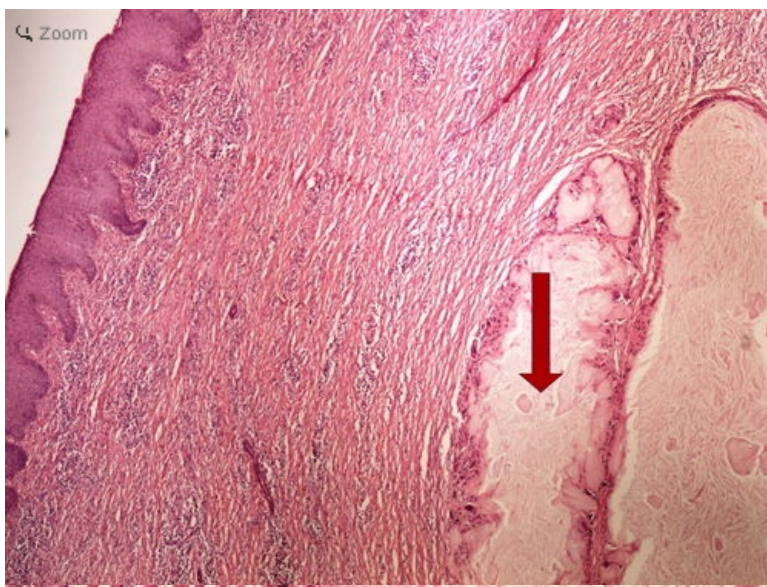
Preparát č.11 a č.12 - cholesterolové krystaly



Struktury

[Expand]

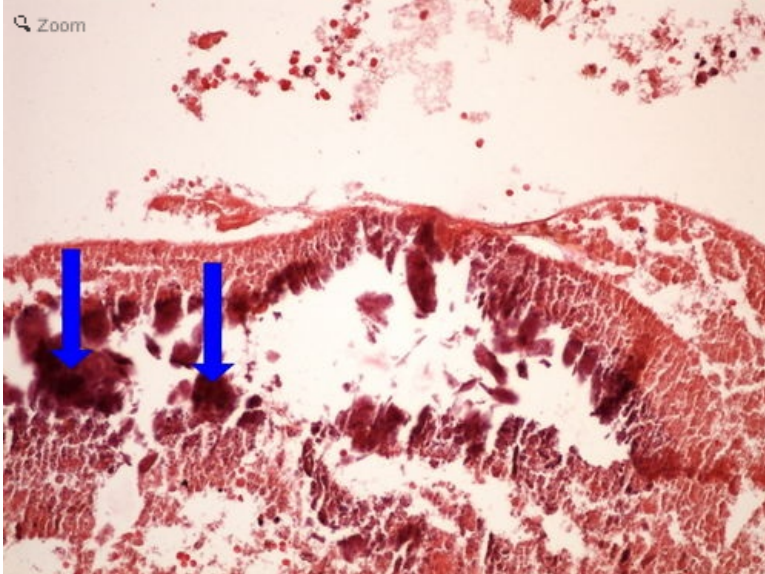
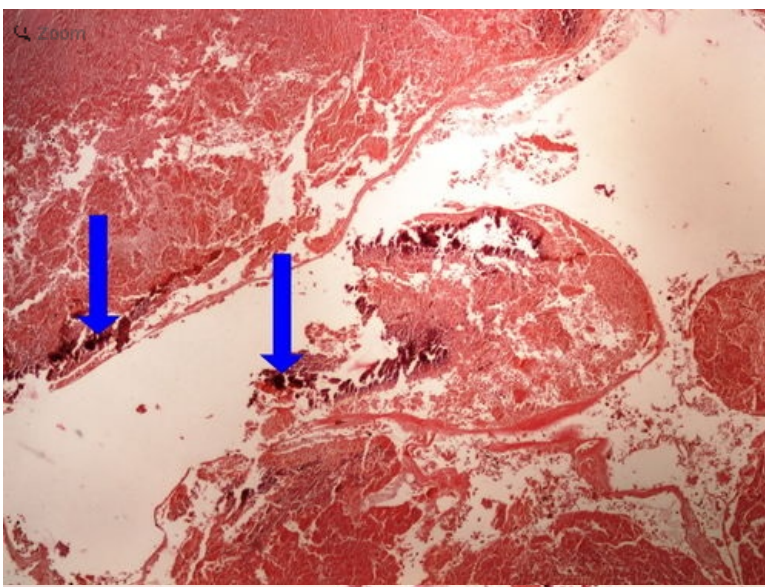
Preparát č.13 a č.14 - dnavé tofy



Struktury

[Expand]

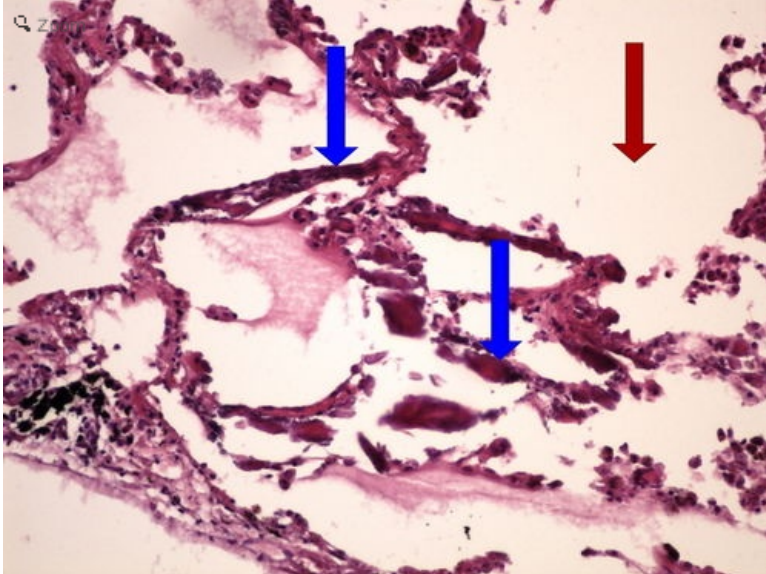
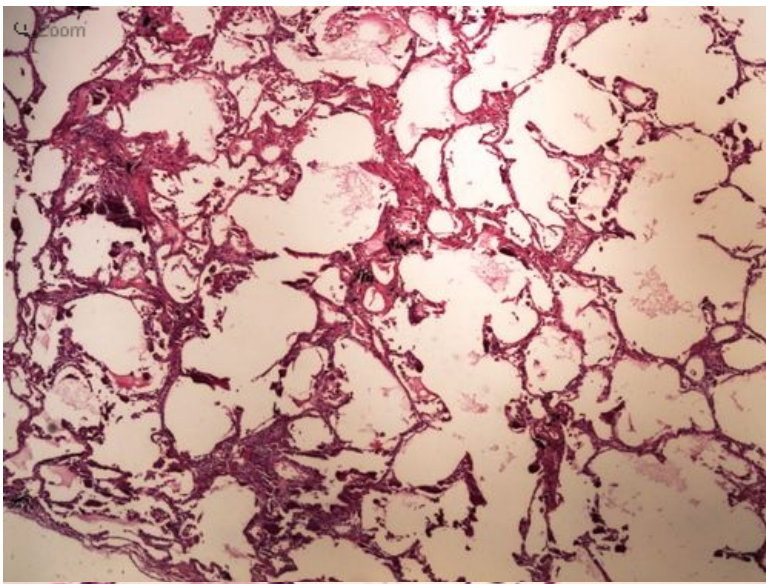
Preparát č.15 a č.16 - dystrofická kalcifikace



Struktury

[\[Expand\]](#)

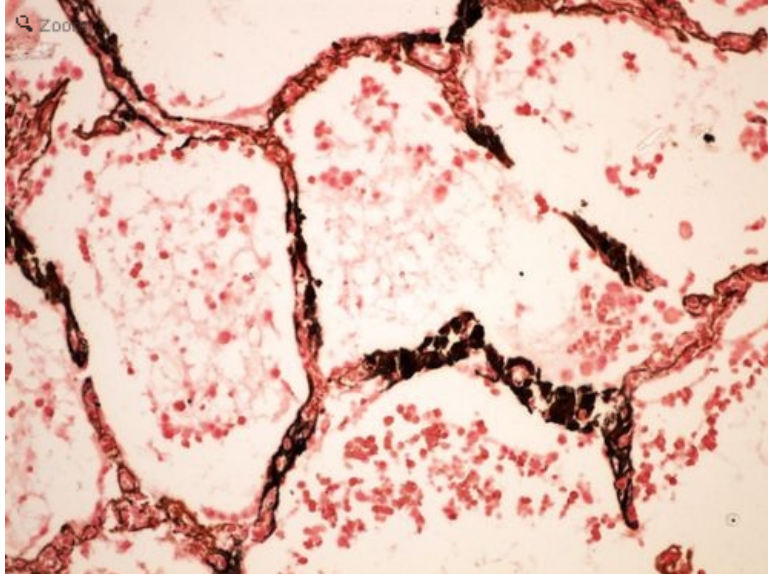
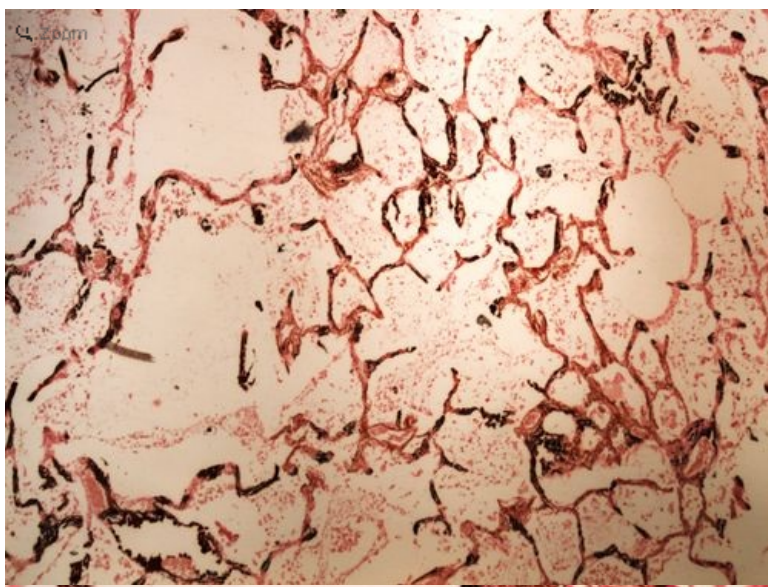
Preparát č.17 a č.18 - metastatická kalcifikace (HE)



Struktury

[Expand]

Preparát č.19 a č.20 - metastatická kalcifikace (Kossa)



Odkazy

Navigace

← Praktikum č. 3

Modul Obecné základy
patologie a patofyziologie (3.
LF UK)

Praktikum č. 5 →