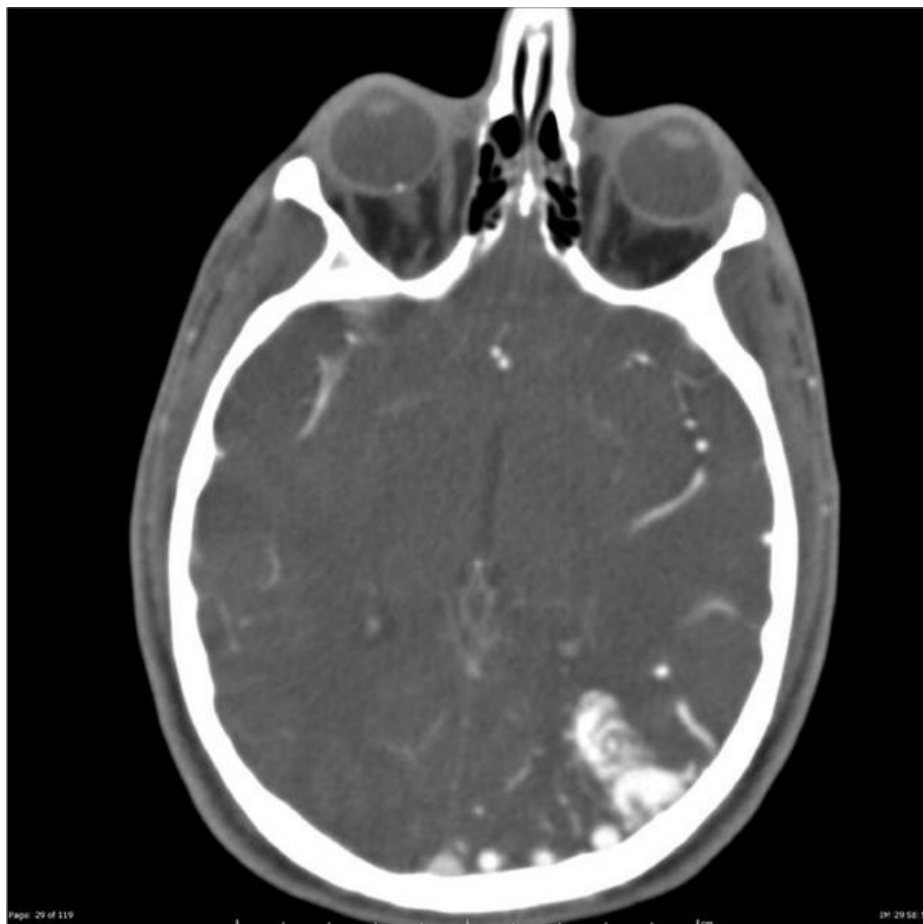

Soubor:CT brainAVM contrast.jpg



Size of this preview: 600 × 600 pixels.

Original file (630 × 630 pixels, file size: 32 KB, MIME type: image/jpeg)

Popis CT AVM contrast

Zdroj <https://radiopaedia.org/cases/cerebral-arteriovenous-malformation-19?lang=us>


Datum 2021-06-26

Autor kolektiv Radiopaedia

Licence Volné dílo nebo soubor, který nemá povahu autorského díla.

File history

Click on a date/time to view the file as it appeared at that time.

	Date/Time	Thumbnail	Dimensions	User	Comment
current	13:19, 26 June 2021		630 × 630 (32 KB)	AdELA (talk contribs)	

You cannot overwrite this file.

File usage

The following page uses this file:

- Arteriovenózní malformace