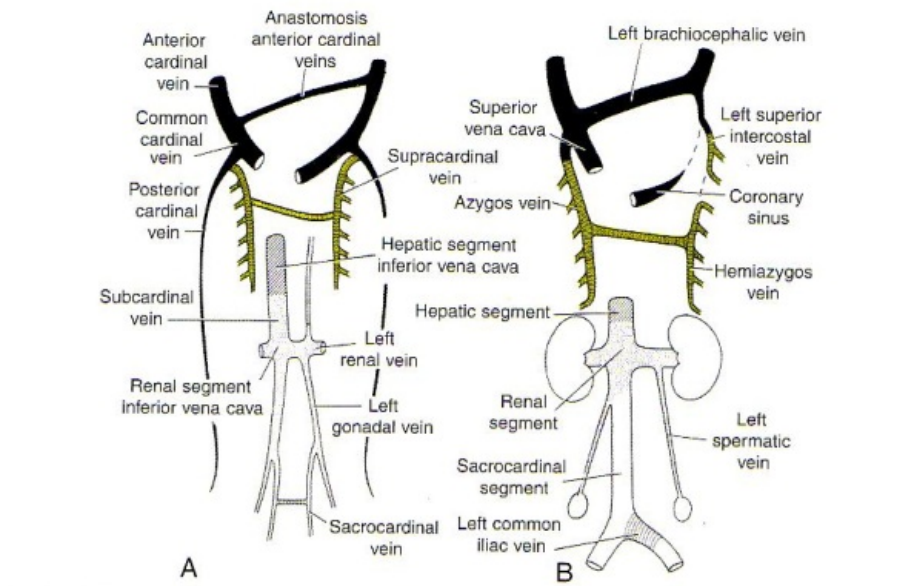


# Soubor: Celkovy pohled2.png



**Figure 12.43** Development of the inferior vena cava, azygos vein, and superior vena cava. **A.** Seventh week. The anastomosis lies between the subcardinals, supracardinals, sacrocardinals, and anterior cardinals. **B.** The venous system at birth showing the three components of the inferior vena cava.



This image can contain annotations.  
Move the mouse over the image to display.  
No higher resolution available.

Celkovy\_pohled2.png (594 × 430 pixels, file size: 241 KB, MIME type: image/png)

Open in Media Viewer

Popis	Venae cardinales
Zdroj	Langmanova lékařská embryologie
Datum	2013-01-17
Autor	Sadler Thomas W.
Licence	Vyhrazeno jen pro přímé užití na stránkách WikiSkripta.eu

## File history

Click on a date/time to view the file as it appeared at that time.

	Date/Time	Thumbnail	Dimensions	User	Comment
current	19:01, 17 January 2013		594 × 430 (241 KB)	Robertfaber (talk   contribs)	{{Soubor popis = Venae cardinales zdroj = Langmanova lékařská embryologie datum = 2013-01-17 autor = Sadler Thomas W. licence = {{WS_licence}}}} Kategorie:Nezařazené soubory Kategorie:Obrázky

You cannot overwrite this file.

## File usage

The following page uses this file:

