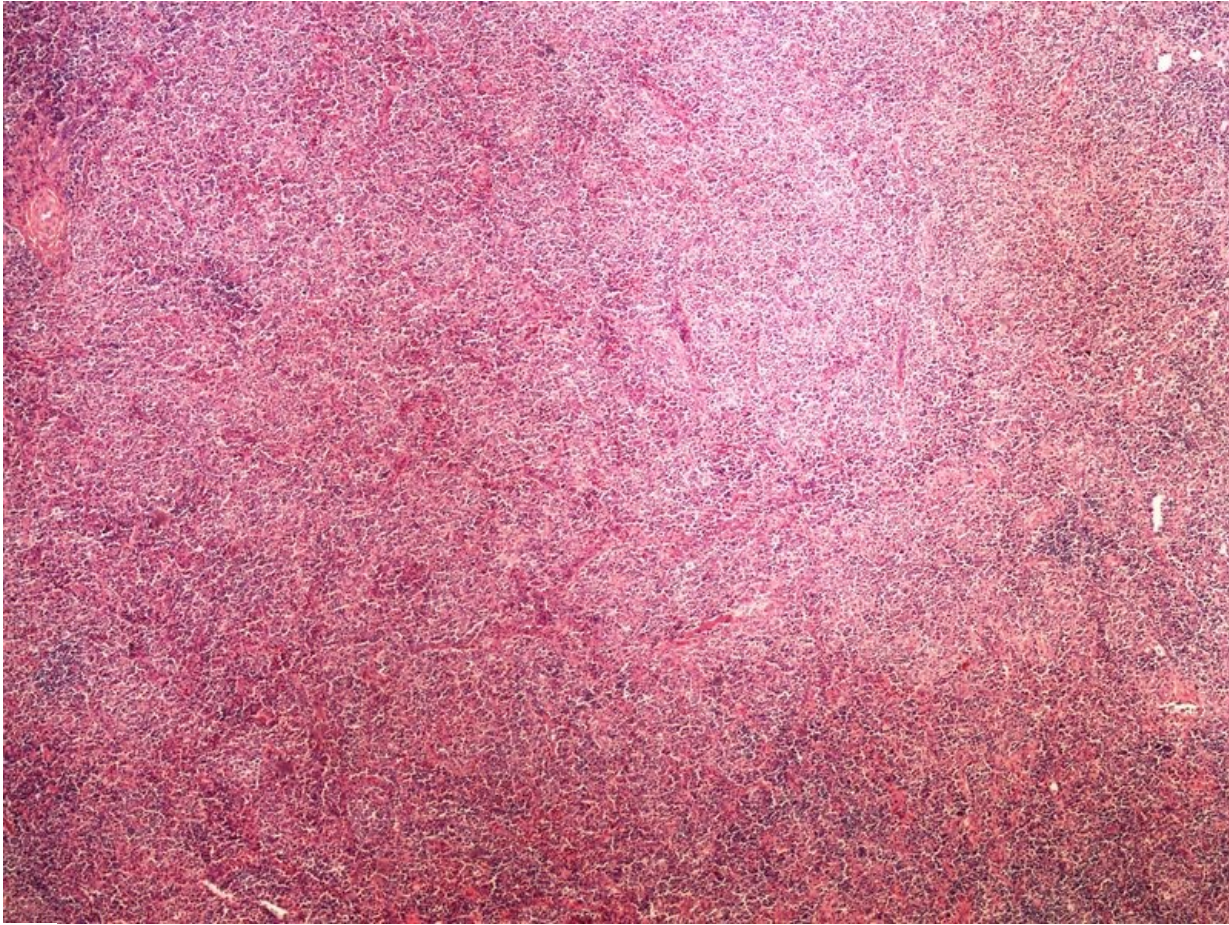


Soubor:Classic Hodgkin lymphomad mixed cellularity klasický Hodgkinuv lymfom smisena celularita 4x.jpg



This image can contain annotations.
Move the mouse over the image to display.
Size of this preview: 800 × 600 pixels.



Original file (2,560 × 1,920 pixels, file size: 4.5 MB, MIME type: image/jpeg)

Open in Media Viewer

Popis	klasický Hodgkinuv lymfom smisena celularita 4x - mikroskopický snímek
Zdroj	vlastní dílo
Datum	2013-10-28
Autor	Patologie3LF
Licence	Vyhrazeno jen pro přímé užití na stránkách WikiSkripta.eu

File history

Click on a date/time to view the file as it appeared at that time.

	Date/Time	Thumbnail	Dimensions	User	Comment
current	23:39, 13 November 2013		2,560 × 1,920 (4.5 MB)	Patologie3LF (talk contribs)	
	17:21, 31 October 2013		2,560 × 1,920 (4 MB)	Patologie3LF (talk contribs)	VicuñaUploader 1.18

You cannot overwrite this file.

File usage

The following 3 pages use this file:

- Modul OZPP - Praktikum č. 14
- Modul OZPP - Praktikum č. 14 (zoom)
- Modul Obecné základy patologie a patofyziologie - Přehled preparátů

Metadata

This file contains additional information, probably added from the digital camera or scanner used to create or digitize it.

If the file has been modified from its original state, some details may not fully reflect the modified file.