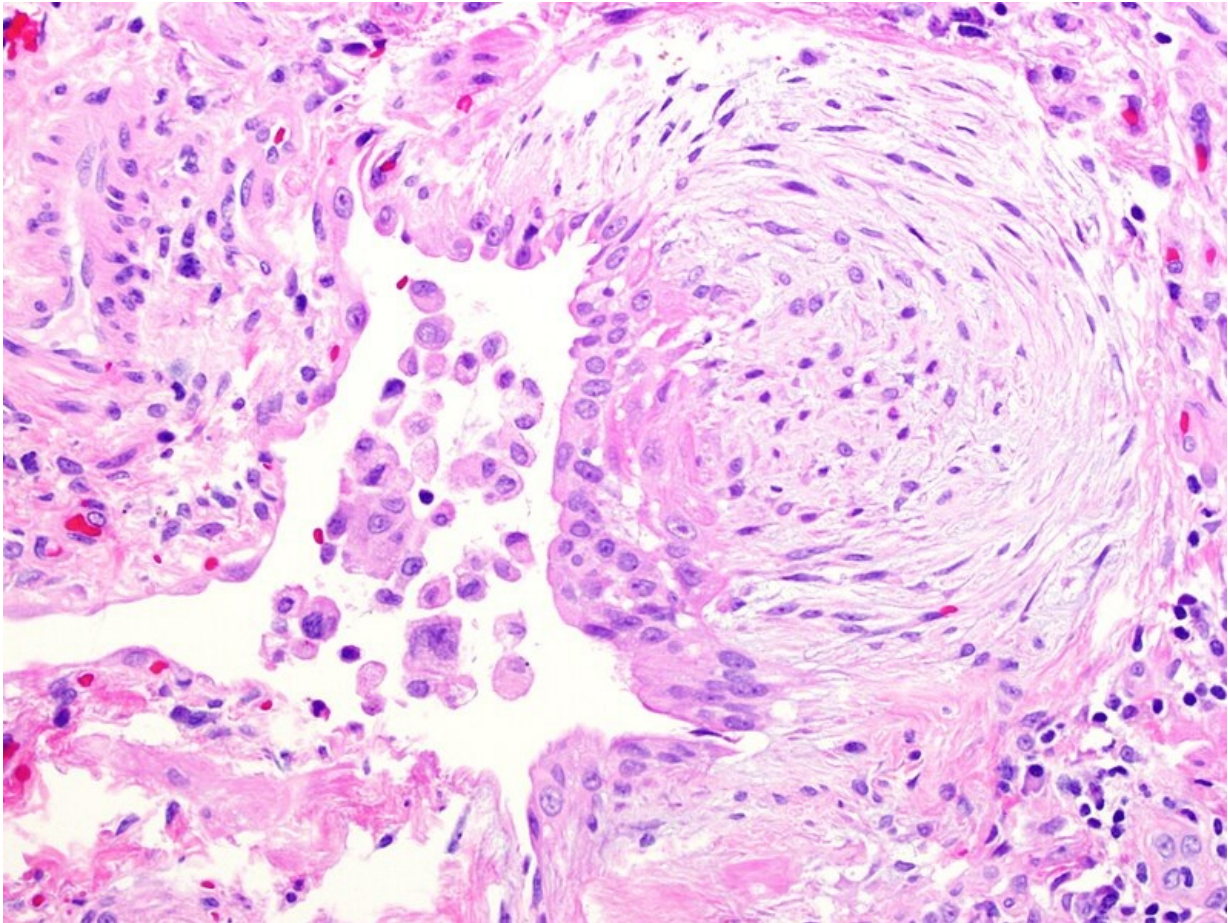


# Soubor:Fibroblast focus.jpg



This image can contain annotations.  
Move the mouse over the image to display.  
Size of this preview: 796 × 599 pixels.

Original file (2,040 × 1,536 pixels, file size: 2.08 MB, MIME type: image/jpeg)

**Open in Media Viewer**

This file is from Wikimedia Commons and may be used by other projects. The description on its file description page there is shown below.

## Summary

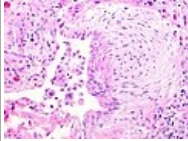
<b>Description</b>	<b>English:</b> Fibroblast focus in usual interstitial pneumonia (UIP). High magnification. Hematoxylin-eosin stain.
<b>Date</b>	29 November 2009
<b>Source</b>	Own work
<b>Author</b>	Mutleysmith

## Licensing

I, the copyright holder of this work, release this work into the **public domain**. This applies worldwide.  
In some countries this may not be legally possible; if so:  
*I grant anyone the right to use this work **for any purpose**, without any conditions, unless such conditions are required by law.*

## File history

Click on a date/time to view the file as it appeared at that time.

	Date/Time	Thumbnail	Dimensions	User	Comment
current	<b>01:46, 19 April 2014</b>		2,040 × 1,536 (2.08 MB)	wikimediacommons>Nephron	white balance, adjust colour levels (0.7) PD as original by "User:Mutleysmith"

## File usage

The following page uses this file:

- Vazivo

## Metadata

This file contains additional information, probably added from the digital camera or scanner used to create or digitize it.

If the file has been modified from its original state, some details may not fully reflect the modified file.

Image title	OLYMPUS DIGITAL CAMERA
Camera manufacturer	OLYMPUS CORPORATION
Camera model	DP71
Exposure time	1/66 sec (0.015151515151515)
ISO speed rating	200
Date and time of data generation	19:08, 29 November 2009