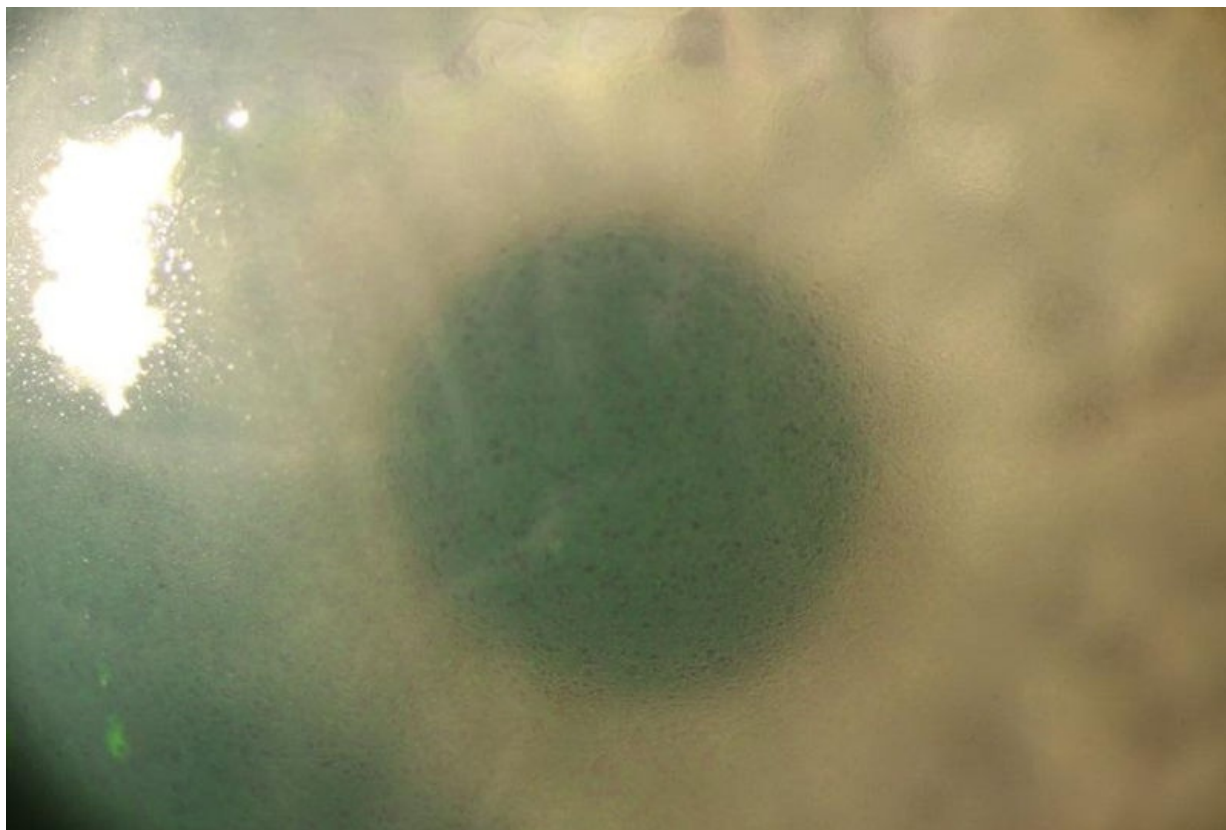


Soubor:Fuchsova dystrofie.jpg



This image can contain annotations.
Move the mouse over the image to display.
Size of this preview: 800 × 537 pixels.

Original file (850 × 571 pixels, file size: 46 KB, MIME type: image/jpeg)

 **Open in Media Viewer** 

Popis Fuchsova endoteliální dystrofie

Zdroj Oční klinika FN Hradec Králové


Datum 2012-11-30

Autor Oční klinika FN Hradec Králové

Licence Vyhrazeno jen pro přímé užití na stránkách WikiSkripta.eu

File history

Click on a date/time to view the file as it appeared at that time.

	Date/Time	Thumbnail	Dimensions	User	Comment
current	21:11, 30 November 2012		850 × 571 (46 KB)	Adnav (talk contribs)	{{Soubor popis = Fuchsova endoteliální dystrofie zdroj = Oční klinika FN Hradec Králové datum = 2012-11-30 autor = Oční klinika FN Hradec Králové licence = {{WS_licence}} }} Kategorie:Oční lékařství Kategorie:Obrázky

You cannot overwrite this file.

File usage

The following page uses this file:

- Degenerace a dystrofie rohovky

Metadata

This file contains additional information, probably added from the digital camera or scanner used to create or digitize it.

If the file has been modified from its original state, some details may not fully reflect the modified file.