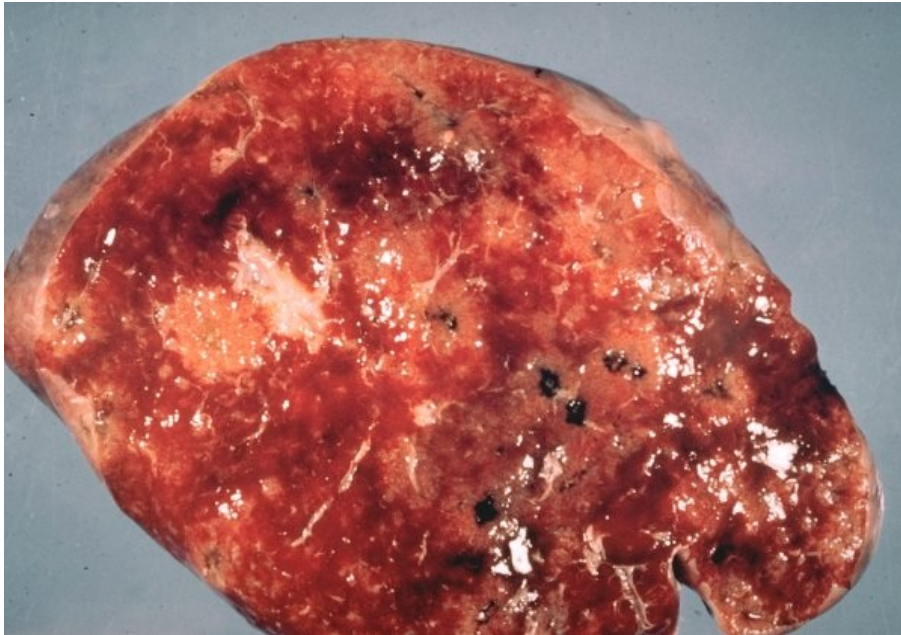


# Soubor:Gross sarcoid spleen677.jpg



This image can contain annotations.  
Move the mouse over the image to display.  
No higher resolution available.

Gross\_sarcoid\_spleen677.jpg (600 × 420 pixels, file size: 62 KB, MIME type: image/jpeg)

 **Open in Media Viewer** 

**Popis** sarkoidóza sleziny

**Zdroj** [http://granuloma.homestead.com/sarcoidosis\\_gross.html](http://granuloma.homestead.com/sarcoidosis_gross.html)


**Datum** *nezadáno*

**Autor** Yale Rosen, M.D

**Licence** Creative Commons NonCommercial-NoDerivs 3.0 Unported (CC BY-NC-ND 3.0) (<http://creativecommons.org/licenses/by-nc-nd/3.0/>)

## File history

Click on a date/time to view the file as it appeared at that time.

	Date/Time	Thumbnail	Dimensions	User	Comment
current	<b>19:36, 9 November 2011</b>		600 × 420 (62 KB)	JANKA (talk   contribs)	{{Soubor  popis = sarkoidóza sleziny  zdroj = http://granuloma.homestead.com/sarcoidosis_gross.html  datum =  autor = Yale Rosen, M.D  licence = {{Zpracovat doplnit licenci}} }} Kategorie:patologie Kategorie:vnitřní lékařství [[Kategorie:Ob

You cannot overwrite this file.

## File usage

The following page uses this file:

- Sarkoidóza lymfatického systému

# Metadata

This file contains additional information, probably added from the digital camera or scanner used to create or digitize it.

If the file has been modified from its original state, some details may not fully reflect the modified file.